

国内版

国际版



Hepatocellular carcinoma with tumor thrombus in bile d



Q ALL

IMAGES

VIDEOS

17,700 Results

Any time ▾

Hepatocellular carcinoma with bile duct tumor thrombi ...

<https://www.sciencedirect.com/science/article/pii/S0720048X09002976>

The formation of **bile duct** tumor thrombi is mainly through the following three ways: (1) tumor grows into the **bile duct**, and tumor tissues fill the **bile duct**; (2) tumor tissues invade the **bile duct** and rupture, a fragment of tumor tissue separate from **primary lesion**, migrate to different sites of the extra-hepatic **bile** ducts and result in ...

Cited by: 15

Author: Qingyu Liu, Jianyu Chen, Haigang Li, Bil...

Publish Year: 2010

Hepatocellular carcinoma with hilar bile duct ... - BMC Cancer

<https://bmccancer.biomedcentral.com/articles/10.1186/s12885-020-6539-7> ▾

Jan 22, 2020 · Liver **cancer** is the sixth most common malignancy and the second leading cause of **cancer** death for males worldwide []. **Hepatocellular carcinoma** (HCC) is the most common type of **primary** liver **cancer**, comprising 75 to 85% of cases [], but HCC with **bile duct** tumor **thrombus** (BDTT) is uncommon with incidence between 0.53 to 12.9% [2,3,4,5,6]. Previous studies have ...

Author: Xiaoqi Zhou

Pathology of small hepatocellular carcinoma. A proposal ...

[https://onlinelibrary.wiley.com/doi/10.1002/1097-0142\(19870815\)60:4<810::AID...](https://onlinelibrary.wiley.com/doi/10.1002/1097-0142(19870815)60:4<810::AID...)

Minoru Esaki, Kazuaki Shimada, Tsuyoshi Sano, Yoshihiro Sakamoto, Tomoo Kosuge and Hidenori Ojima, Surgical results for **hepatocellular carcinoma** with **bile duct** invasion: A clinicopathologic comparison between macroscopic and microscopic tumor **thrombus**, Journal of Surgical Oncology, 90, 4, (226-232), (2005).

Cited by: 445

Author: Toshio Kanai, Setsuo Hirohashi, Melissa...

Publish Year: 1987

A single institution report of 19 hepatocellular carcinoma ...

<https://www.ncbi.nlm.nih.gov/pmc/articles/PMC5349699>

Aug 07, 2017 · Objective: To report the clinical course and histologic features of **bile duct** tumor **thrombus** (BDTT) in ...



Hepatocellular carcinoma with tumor thrombus in bile duct: A prop



ALL IMAGES VIDEOS MAPS NEWS SHOPPING

22,800 Results Any time ▾

Hepatocellular carcinoma with hilar bile duct tumor ...

<https://bmccancer.biomedcentral.com/articles/10.1186/s12885-020-6539-7>

Jan 22, 2020 · Liver cancer is the sixth most common malignancy and the second leading cause of cancer death for males worldwide [1]. Hepatocellular carcinoma (HCC) is the most common type of primary liver cancer, comprising 75 to 85% of cases [2], but HCC with bile duct tumor thrombus (BDTT) is uncommon with incidence between 0.53 to 12.9% [2,3,4,5,6]. Previous studies have attempted to ...

Author: Xiaoqi Zhou, Jifei Wang, Mimi Tang, ... Publish Year: 2020

A single institution report of 19 hepatocellular carcinoma ...

<https://www.ncbi.nlm.nih.gov/pmc/articles/PMC5349699>

Obstructive jaundice caused due to bile duct tumor thrombus (BDTT) in a hepatocellular carcinoma (HCC) patient is an uncommon event. This study reports our clinical experiences and evaluates the outcomes of HCC patients with BDDT in a single institution.

Cited by: 3 Author: Anon Chotirosniramit, Akkaphod Liwattan...

Publish Year: 2017

Diagnosis and surgical treatments of hepatocellular ...

<https://www.ncbi.nlm.nih.gov/pmc/articles/PMC4656273>

May 15, 2004 · Aim: Hepatocellular carcinoma (HCC) with bile duct tumor thrombosis (BDT) is a rare event. The prognosis of this type of patients is very dismal. The aim of this study was to share the experience in the diagnosis and treatment of HCC with BDT, to further improve the prognosis of ...

Cited by: 70 Author: Lun-Xiu Qin, Zeng-Chen Ma, Zhi-Quan W...

Publish Year: 2004

Advances in Surgical Research of Hepatocellular Carcinoma ...

<https://www.researchgate.net/publication/328885722...>

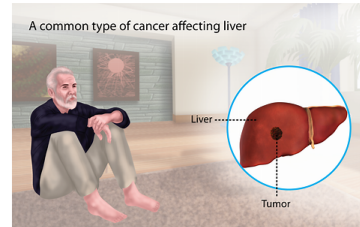
Hepatocellular carcinoma (HCC) with bile duct tumor thrombus (BDTT) formation is a rare entity found microscopically in 1% to 9.2% of resected specimens. The ideal treatment for HCC is surgical ...

Radiofrequency Ablation of the Main Lesion of ...

<https://www.ncbi.nlm.nih.gov/pmc/articles/PMC4504562>

Hepatocellular Carcinoma

Medical Condition



The most common form of liver cancer often seen in people with chronic liver diseases like cirrhosis.

Rare (Fewer than 200,000 cases per year in US)

May be preventable by vaccine

Often requires lab test or imaging

Treatment from medical professional advised

Can last several months or years

Caused mainly due to the chronic infection of the liver or DNA mutation of the liver cells. Characterized by unexplained weight loss, upper abdominal pain and yellowing of the skin. Treatment options include hepatectomy, target drug delivery and the use of radiation to kill the cancerous cells.


Symptoms

Early stages of the disease do not present any symptoms but in the late stages, symptoms such as the common ones which are noticed are as follows:

11-Jul-2020 11:55AM

5296 words • 7 matches • 7 sources

FAQ

iThenticate®

56510-Review-check.docx

Quoties Included
Bibliography Included

2%
similarity

Name of Journal: *World Journal of Gastroenterology*

Manuscript NO: 56510

Manuscript Type: ORIGINAL ARTICLE

Retrospective Study

Hepatocellular carcinoma with tumor thrombus in bile duct: A proposal of new classification according to resectability of primary lesion

New classification for HCC with BDDT

Di Zhou, Gang-Feng Hu, Wei-Chen Gao, Xiao-Yu Zhang, Wen-Bin Guan, Jian-Dong Wang, Fei Ma

Abstract

BACKGROUND

Hepatocellular carcinoma (HCC) with tumor thrombus in bile duct (BDDT) is easily misdiagnosed or mistreated due to the clinicopathological diversity of the thrombus and its relationship with primary lesions.

Match Overview

1

Crossref 19 words
Choi, Jong Young, "Diagnostic value of AFP, L3 and PIVKA-II in hepatocellular carcinoma according to total-AFP", *World J*

<1%

2

Internet 17 words
crawled on 17-Jan-2020
www.thieme-connect.com

<1%

3

Internet 15 words
crawled on 16-Jun-2019
www.landonline.com

<1%

4

Internet 12 words
crawled on 04-Oct-2016
www.koreamed.net

<1%

5

Crossref 12 words
Wu, Zheng, Kun Guo, Hao Sun, Liang Yu, Yi Lv, and the Wang g, "Criteria for Diagnosis and Surgical Treatment of Recurrent

<1%

6

Internet 12 words
crawled on 15-Mar-2020
link.springer.com

<1%

7

Internet 12 words
crawled on 25-Feb-2016
news.rare-cancer.org

<1%

Page: 1 of 16

Text Only Report

国内版

国际版

Hepatocellular carcinoma with tumor thrombus in bile duct: A pro



ALL

IMAGES

VIDEOS

45,600 Results

Any time ▾

Hepatocellular carcinoma with hilar bile duct tumor ...

<https://bmccancer.biomedcentral.com/articles/10.1186/s12885-020-6539-7> ▾

Jan 22, 2020 · Liver **cancer** is the sixth most common malignancy and the second leading cause of **cancer** death for males worldwide []. **Hepatocellular carcinoma** (HCC) is the most common type of **primary liver cancer**, comprising 75 to 85% of cases [], but HCC with **bile duct tumor thrombus** (BDTT) is uncommon with incidence between 0.53 to 12.9% [2,3,4,5,6]. Previous studies have ...

Author: Xiaoqi Zhou, Jifei Wang, Mimi Tang, ... **Publish Year:** 2020

A single institution report of 19 hepatocellular carcinoma ...

<https://www.ncbi.nlm.nih.gov/pmc/articles/PMC5349699>

Obstructive jaundice caused due to **bile duct tumor thrombus** (BDTT) in a **hepatocellular carcinoma** (HCC) patient is an uncommon event. This study reports our clinical experiences and evaluates the outcomes of HCC patients with BDTT in a single institution.

Cited by: 3 **Author:** Anon Chotirosniramit, Akkaphod Liwatt...

Publish Year: 2017

Advances in Surgical Research of Hepatocellular Carcinoma ...

https://www.researchgate.net/publication/328885722_Advances_in_Surgical_Research_of...

Hepatocellular carcinoma (HCC) with **bile duct tumor thrombus** (BDTT) formation is a rare entity found microscopically in 1% to 9.2% of resected specimens. ...

PEOPLE ALSO ASK

What are the histologic types of perihilar bile duct cancer?



What is extrahepatic bile duct tumor?

