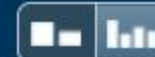

Match Overview



Name of Journal: *World Journal of Gastroenterology*

Manuscript NO: 67416

Manuscript Type: LETTER TO THE EDITOR

Gastrointestinal cytomegalovirus disease secondary to measles in an immunocompetent infant

Chao-Ming Hung, Po-Huang Lee, Hui-Ming Lee, Chong-Chi Chiu

Abstract

Yang *et al* reported an immunocompetent infant with gastrointestinal cytomegalovirus disease secondary to measles infection. We express our opinion about the diagnosis and treatment of this rare disease.

There are no matching sources for this report.



国内版

国际版



Comment on: Gastrointestinal cytomegalovirus disease secondary to



ALL

IMAGES

VIDEOS

25,400 Results

Any time ▼

[Gastrointestinal cytomegalovirus disease secondary to ...](#)

<https://pubmed.ncbi.nlm.nih.gov/33958850>

Extensive **gastrointestinal CMV** lesions can be induced by the immune suppression **secondary to measles infection**. Rational, fast, and effective laboratory examinations are ...

[Gastrointestinal cytomegalovirus disease secondary to ...](#)

<https://europepmc.org/article/PMC/PMC8058656> ▼

Apr 01, 2021 · We describe a case of extensive **gastrointestinal CMV disease secondary to measles infection** in a 9-mo-old boy who presented with persistent fever and bloody diarrhea. His condition was...

[Gastrointestinal cytomegalovirus disease secondary to ...](#)

<https://europepmc.org/article/MED/33958850> ▼

Apr 01, 2021 · **Gastrointestinal cytomegalovirus (CMV) disease** occurs commonly in immunocompromised/immunodeficient patients with advanced human **immunodeficiency virus**...

[Successful treatment with oral valganciclovir in ...](#)

<https://www.nature.com/articles/7211578>

Sep 28, 2006 · **CMV gastrointestinal disease secondary to perinatal infection** is a rare condition in non-immunocompromised patients. We identified only a single published **report**...

Cited by: 23

Author: PS Buonomo, Palma Maurizi, Piero Vale...

Publish Year: 2006

Gastrointestinal cytomegalovirus disease secondary to measles in a



ALL

IMAGES

VIDEOS

65,800 Results

Any time ▼

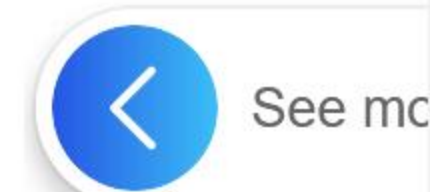[Gastrointestinal cytomegalovirus disease secondary to ...](https://pubmed.ncbi.nlm.nih.gov/33958850)

<https://pubmed.ncbi.nlm.nih.gov/33958850>

Background: **Gastrointestinal cytomegalovirus (CMV)** disease occurs commonly in immunocompromised/immunodeficient patients with advanced human **immunodeficiency virus infection**, neoplasm, solid organ transplantation, hematopoietic stem cell transplantation, or treatment with immunosuppressants, but is rarely reported in association with measles infection.

Author: Qing-Hua Yang, Xiao-Peng Ma, Dong... **Publish Year:** 2021

Gastrointestinal cytomegalovirus disease secondary to ...



[ALL](#)
[IMAGES](#)
[VIDEOS](#)
[MAPS](#)
[NEWS](#)
[SHOPPING](#)

67,900 Results

Any time ▾

Gastrointestinal cytomegalovirus disease secondary to ...

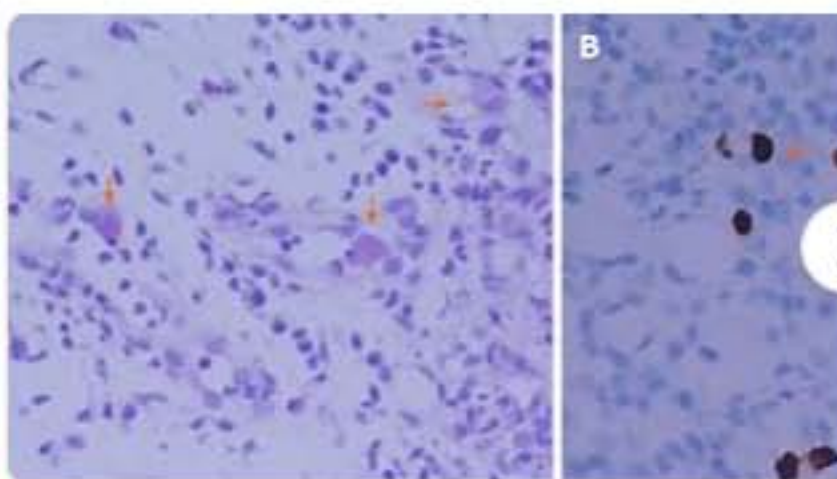
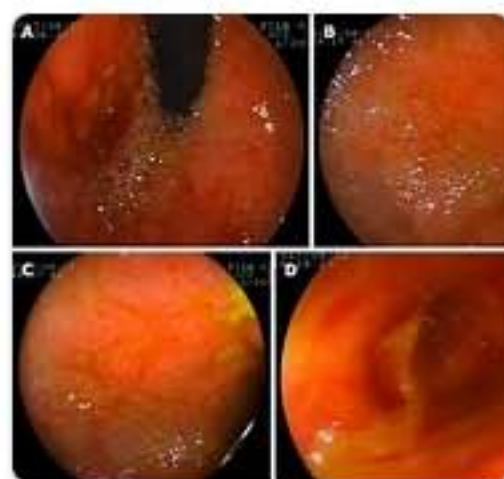<https://pubmed.ncbi.nlm.nih.gov/33958850>

Background: **Gastrointestinal cytomegalovirus (CMV)** disease occurs commonly in immunocompromised/immunodeficient patients with advanced human **immunodeficiency virus...**

Author: Qing-Hua Yang, Xiao-Peng Ma, Dong-Li... Publish Year: 2021

Images of Gastrointestinal cytomegalovirus disease secondary to ...

<bing.com/images>



See all images >

Gastrointestinal cytomegalovirus disease secondary to ...

<https://europepmc.org/article/PMC/PMC8058656> ▾

Apr 01, 2021 · The morbidity from **diarrhea**, one of the most common complications of **measles**, is reported to increase in the acute phase of **measles**; however, **gastrointestinal CMV** infection is rarely...

Gastrointestinal cytomegalovirus disease secondary to ...

<https://europepmc.org/article/MED/33958850> ▾

Apr 01, 2021 · We describe a case of extensive **gastrointestinal CMV disease secondary to measles infection** in a 9-mo-old boy who presented with persistent fever and bloody diarrhea. His condition was...

Author: Qing-Hua Yang, Xiao-Peng Ma, Dong-Li... Publish Year: 2021

Neonatal gastrointestinal involvement and congenital ...