

[PDF] Endoscopic Management of Large, Flat Colorectal Polyps<https://www.mayoclinic.org/documents/mc2024-1211-pdf/DOC-20078942>

colorectal polyps are now safely and effectively treated endoscopically—most commonly with endoscopic mucosal resection. • Various endoscopes and snares enable treatment of polyps in any...

EXPLORE FURTHER

Colon Polyps: Which Ones Are Riskiest for You? – Health ...health.clevelandclinic.org

Understanding Your Pathology Report: Colon Polyps (Sessile ...

www.cancer.org

Flat Colon Polyps and Endoscopic Mucosal Resection | MD ...

www.mdanderson.org

Flat Colon Polyps | LA Colon & Rectal Surgical Associates

lacoln.com

Recommended to you based on what's popular • Feedback

[PDF] Endoscopic Recognition and Management Strategies for ...<https://www.asge.org/.../guidelines/practice-guidelines/endoscopic-recognition>

reduce errors in understanding and clinical management. ENDOSCOPIC AND HISTOLOGIC CLASSIFICATION SYSTEMS USED IN THIS DOCUMENT The optimal management of malignant...

PEOPLE ALSO ASK

How are malignant polyps treated in a colonoscopy? ▾

What is endoscopic removal of polyp? ▾

Can polypsremoveda increase the risk of colon cancer? ▾

Can chromoendoscopy be used to treat polyps? ▾

Feedback

Management of malignant colon polyps: current status and ...<https://pubmed.ncbi.nlm.nih.gov/25473171>

Malignant polyps are defined by the presence of cancer cells invading through the muscularis mucosa into the underlying submucosa (T1). They can appear benign endoscopically but the presence of...

Cited by: 65

Author: Cary B Aarons, Skandan Shanmugan, Jo...

Microsoft Bing

国内版 国际版

Endoscopic management of colorectal polyps: From benign to ma

Chat with Bing

Sign in

Add the Olive with Bing extension

ALL IMAGES VIDEOS

270,000 Results Any time

Endoscopic Management of Malignant Colorectal Polyps ...

<https://www.sciencedirect.com/science/article/pii/S1055320718303697>

Jul 01, 1996 ENDOSCOPIC MANAGEMENT OF MALIGNANT COLORECTAL POLYPS 641 Submucosal Injection of Saline Submucosal injection of saline solution was first described by Dayle et al29 in 1973 as an aid in the management of sessile polyps.

Cited by: 4 Author: Nicole J. Kafka, John A. Collier

Publish Year: 1996

Management of malignant colon polyps: current status and ...

<https://pubmed.ncbi.nlm.nih.gov/25473171>

Malignant polyps are defined by the presence of cancer cells invading through the muscularis mucosa into the underlying submucosa (T1). They can appear benign endoscopically but the presence of malignant invasion histologically poses a difficult and often controversial clinical scenario.

Cited by: 68 Author: Cary B. Aaron, Skandan Shanmugan, Josh...

Publish Year: 2014

PEOPLE ALSO ASK

How are Endoscopes used to treat colorectal polyps?

Are there any management strategies for malignant polyps?

Can a polyp be removed with a colonoscopy?

What is the current status of colon polyps?

Feedback

Management of colorectal polyps - Markowitz - 1997 - CA: A ...

<https://acsjournals.onlinelibrary.wiley.com/doi/full/10.3322/canjclin.47.2.93>

Polyps may be detected endoscopically by sigmoidoscopy or colonoscopy, or radiographically by barium enema. Colorectal polyps are classified histologically as either neoplastic (adenomatous polyps) or non-neoplastic (Table). Although all adenomatous polyps have malignant potential, the majority are benign ...

Cited by: 60 Author: Arnold J. Markowitz, Sidney J. Winawer

Publish Year: 1997

PDF Endoscopic Management of Large, Flat Colorectal Polyps

<https://www.mayoclinic.org/documents/mc2024-1211-pdf/DOC-20078942>

colorectal polyps are now safely and effectively treated endoscopically—most commonly with endoscopic mucosal resection. • Various endoscopes and snares enable treatment of polyps in any part of the gastrointestinal tract accessible to endoscopy, including the esophagus, stomach, and duodenum. • Endoscopic submucosal dissection, a

Large colorectal polyps: endoscopic management and rate of ...

<https://pubmed.ncbi.nlm.nih.gov/20871408>

The rate of invasive cancer is low among endoscopically resected large colorectal polyps and most of these polyps can be resected successfully via colonoscopy with minimal morbidity and no mortality. A close endoscopic follow-up is required to monitor for recurrence.

Cited by: 25 Author: Sushil K. Ahlawat, Naveen Gupta, Stanley B...

Publish Year: 2011

PDF Endoscopic Recognition and Management Strategies for ...

<https://www.asge.org/docs/default-source/default-document-library/endoscopic...>

reduce errors in understanding and clinical management. ENDOSCOPIC AND HISTOLOGIC CLASSIFICATION SYSTEMS USED IN THIS DOCUMENT The optimal management of malignant polyps in mod-ern colonoscopy is based on the endoscopic diagnosis. Before endoscopic resection, every colorectal lesion de-tected at colonoscopy should undergo complete assess-

Experts release new management strategies for malignant ...

<https://gastro.org/press-releases/experts-release...>

Nov 04, 2020 Management of malignant polyps must begin with a thorough and knowledgeable endoscopic assessment designed to identify features of deep submucosal invasion. In nonpedunculated lesions with features of deep submucosal invasion, endoscopic biopsy and tattooing should be followed by surgical resection.

Estimated Reading Time: 4 mins

PDF Management of the malignant colorectal polyp: ACPGBI ...

<https://www.acpgbi.org.uk/content/uploads/...>


management of malignant polyps Modern endoscopic practice is safe, thorough and offers extensive opportunities for identification, diagnosis and definitive management of most benign colorectal neoplasms. A small proportion of these will be early cancers, and the diffusion of colorectal cancer screening has led to more of these being discovered [16]. The

File Size: 1MB Page Count: 38

11-Jul-2021 05:31PM

4358 words • 121 matches • 58 sources

FAQ

 iThenticate

65639_Auto_EditedC.docx

Quoted Included
Bibliography Included

27%
SIMILAR

14

Name of Journal: *World Journal of Gastrointestinal Endoscopy*

Manuscript NO: 65639

Manuscript Type: MINIREVIEWS

Endoscopic management of colorectal polyps: From benign to malignant polyps

Mathews AA ¹⁶ *et al.* Endoscopic management of colorectal polyps

April A Mathews, Peter V Draganov, Dennis Yang

Abstract

Colorectal cancer (CRC) is the third most common cancer worldwide and the second leading cause of cancer related death in the world. The early detection and removal of CRC precursor lesions has been shown to reduce the incidence of CRC and cancer-related mortality. Endoscopic resection has become the first-line treatment for the removal of most precursor benign colorectal lesions and selected malignant polyps. Detailed lesion assessment is the first critical step in the evaluation and

Match Overview

1

Crossref 121 words
Dennis Yang, Peter V. Draganov, "Surgery Referral of C...
rectal Polyps Based on Real-Time Optical Diagnosis Ab

3%

2

Crossref 113 words
Nabeel Moon, Mahmoud Aryan, Walid Khan, Peter Jiang
et al. "Effect of referral pattern and histopathology grade...

2%

3

Crossref 63 words
"Colon Polypectomy", Springer Science and Business Me
dia LLC, 2010

1%

4

Internet 48 words
crawled on 12-Aug-2020
www.wjnet.com

1%

5

Internet 46 words
crawled on 24-Feb-2021
www.karger.com

1%

6

Internet 43 words
crawled on 13-Jul-2020
journals.lww.com

1%

7

Crossref 38 words
Dennis Yang, Mohamed Othman, Peter V. Draganov, "En
doscopic Mucosal Resection Versus Endoscopic Submuc

1%

8

Crossref 36 words
Nabeel Moon, Mahmoud Aryan, Walid Khan, Peter Jiang
et al. "The effect of referral pattern and histopathology g...

1%

PAGE: 1 OF 16

Text Only Report

国内版

国际版

Endoscopic management of colorectal polyps: From benign to mal



ALL

IMAGES

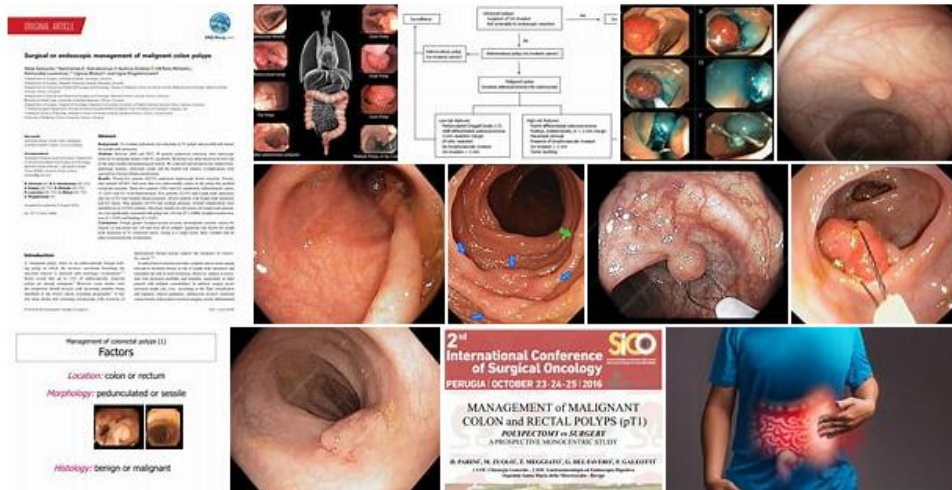
VIDEOS

270,000 Results

Any time ▾

Images of endoscopic management of Colorectal Polyp...

bing.com/images



[See all images >](#)

Management of malignant colon polyps: current status and ...

<https://pubmed.ncbi.nlm.nih.gov/25473171>

Malignant polyps are defined by the presence of cancer cells invading through the muscularis mucosa into the underlying submucosa (T1). They can appear **benign endoscopically** but the presence of **malignant invasion** histologically poses a difficult and often controversial clinical scenario.

Cited by: 71

Author: Cary B Aarons, Skandan Shanmugan, Jo...

Publish Year: 2014

[PDF] Endoscopic Management of Large, Flat Colorectal Polyps

<https://www.mayoclinic.org/documents/mc2024-1211-pdf/DOC-20078942>

colorectal polyps are now safely and effectively treated endoscopically—most commonly with endoscopic mucosal resection. Various endoscopic and surgical treatment of polyps is available.