

80310_Auto_Edited.docx

An update on endoscopic techniques for gastric neuroendocrine tumors

Massironi S ⁴ *et al.* Endoscopic treatment of gastric neuroendocrine tumors

Abstract

Background: Gastric ⁴ neuroendocrine neoplasms (gNENs) are a rare type of gastric neoplasm, even if their frequency is increasing according to the latest epidemiologic revisions of the main registries worldwide. They are divided into three main subtypes, with different pathogeneses, biological behaviors, and clinical characteristics. GNEN heterogeneity poses challenges, therefore these neoplasms require different management strategies. Aim: Update the knowledge on the endoscopic treatment options to manage gNENs. Methods: This manuscript is a narrative review of the literature. Results: In recent years, many advances have been made not only in the knowledge of both the pathogenesis and the molecular profiling of gNENs but also in the endoscopic expertise towards innovative treatment options, which proved to be less aggressive without losing the capability of being radical. The endoscopic approach is increasingly applied in the field of gastrointestinal (GI) luminal neoplasms, and this is true not only for adenocarcinomas but also for gNENs. In particular, different ² techniques have been described for the endoscopic removal of suspected lesions, ranging from classical polypectomy (cold or hot snare) to endoscopic mucosal resection (both with “*en bloc*” or piecemeal technique), ² endoscopic submucosal dissection, and endoscopic full-thickness resection. Conclusion: GNENs comprise different subtypes of neoplasms with distinct management and prognosis. New endoscopic techniques offer a wide variety of approaches for GI localized neoplasms, which demonstrated to be appropriate and effective also in the case of gNENs. Correct evaluation of size, site, morphology, and clinical context allows the choice of tailored therapy in order to guarantee a definitive treatment.

Key Words: Stomach neoplasm; Neuroendocrine tumors; Endoscopy; Endoscopic mucosal resection; Endoscopic submucosal dissection

Massironi S, Gallo C, Laffusa A, Ciuffini C, Conti CB, Barbaro F, Boskoski I, Dinelli ME, Invernizzi P. An update on endoscopic techniques for gastric neuroendocrine tumors. *World J Gastrointest Endosc* 2023; In press

Core Tip: Gastric neuroendocrine neoplasms (gNENs) are a rare form of gastric neoplasia, although their incidence is increasing worldwide according to recent epidemiological reviews of large registries. The heterogeneity of gNENs poses a challenge, and therefore these neoplasms require different treatment strategies. Among the possible treatment options, the endoscopic approach is increasingly used and progressively improved, with different techniques available, ranging from classical polypectomy (cold or hot snare) to endoscopic mucosal resection (both with “*en bloc*” and piecemeal techniques), endoscopic submucosal dissection and endoscopic full-thickness resection. In this manuscript, we have summarized all new endoscopic techniques for the treatment of gastric neuroendocrine tumors.

INTRODUCTION

Gastric neuroendocrine neoplasms (gNENs) are heterogeneous tumors whose incidence has increased rapidly recently due to improved recognition and awareness of neuroendocrine neoplasms as distinct tumor types^[1]. Representing approximately 1%-2% of all gastrointestinal (GI) malignancies^[2], they are still a rare type of tumor, even if they constitute the most frequent localization of digestive NENs, accounting for 20% of all enteric neuroendocrine tumors in selected countries, followed by rectal NENs^[3-5]. In addition to the European Neuroendocrine Tumors Society (ENETS) grading system that all NENs follow, based on the degree of differentiation and the Ki67 index (*i.e.*, well-differentiated G1, G2 and G3, and poorly differentiated G3 neoplasms), gNENs are also divided into three main clinical types with different etiology and pathophysiology, as well as different prognosis and treatment strategy^[6]: Type 1 gNENs are associated with chronic autoimmune atrophic gastritis (CAAG); type 2 gNENs are associated with gastrinoma/MEN-1 syndrome; in contrast, type 3 gNENs are not associated with any related pathology because they are usually sporadic^[3,7]. Figure 1 summarizes the clinical and biochemical differences among the three types of g-NENs. Type 1 tumors represent the majority of gNENs and account for approximately 70%-80%^[8]; they are usually

detected through an upper GI endoscopy, and they mainly appear as small, multiple, located in the gastric body or fundus. They are composed of enterochromaffin-like (ECL) cells, that are usually confined to the mucosal or submucosal layers of the gastric wall^[6] (Figure 2A-C); as for their etiopathogenesis, they are known to be an epiphenomenon of hypergastrinemia due to CAAG^[9,10], while the role of PPI is more controversial^[11]. Patients with CAAG, therefore, have an increased incidence of gNENs^[12], and for this reason, they should undergo endoscopic surveillance with a variable interval^[13].

Since type 1 gNENs are associated with a risk of metastasis of less than 5%, a conservative approach based on endoscopic resection and follow-up is preferred to surgery for small neoplasms greater than 5 mm in diameter and not infiltrating the muscularis propria^[14,15], although there is no evidence of a significant superiority of endoscopic resection over surveillance alone in terms of prognosis and recurrence in case of these small lesions^[16]. According to ENETS guidelines, a EUS staging is recommended for lesions > 10 mm to determine the exact depth of tumor infiltration, its size and echogenicity, to assess loco-regional lymph node involvement, and thus to confirm the appropriateness of endoscopic resection^[17,18]. Nevertheless, the accuracy of EUS in staging submucosal lesions appears to be only 45% when compared with the histologic diagnosis after complete endoscopic resection^[19]. Therefore, accurate staging is often not possible until the lesion has been removed, as histology remains the gold standard for determining tumor differentiation, infiltration of the deep resection margins, and lymphatic vessel invasion^[9].

Type 2 gNENs represent the smallest proportion of all gNENs, accounting for only 5%-6% of them; like type 1 neoplasms, they arise from ECL cells, and they are often small, multiple, and polypoid. They also represent an epiphenomenon of the trophic effect induced by hypergastrinemia on the gastric mucosa, but in this case hypergastrinemia is due to preexisting gastro-entero-pancreatic gastrinoma; type 2 gNENs are therefore associated with Zollinger-Ellison Syndrome (ZES), particularly in the context of multiple endocrine neoplasia type 1 (MEN-1) syndrome^[6]. To date, there is no complete agreement among international guidelines regarding the timing of endoscopic surveillance of gNEN in patients diagnosed with gastrinoma^[20-22]. Although approximately 10%-30% of cases are diagnosed at a metastatic stage, type 2 gNENs are relatively benign tumors^[23], and therefore, the same therapeutic approach is taken as for type 1 gNENs^[17,24], even if the

definitive treatment is removal/treatment of primary gastrinoma; for this purpose, EUS is useful to detect the associated primary duodenal/pancreatic lesion^[16].

Type 3 gNENs, which account for approximately 14%-25% of all gNENs, are usually larger, sporadic single lesions, with a greater tendency to infiltrate and metastasize^[14]. They are not associated with hypergastrinemia. Because of their aggressiveness, surgery represents the therapeutic strategy of choice, with total or subtotal gastrectomy together with lymphadenectomy being the standard treatment, as for gastric adenocarcinoma. Endoscopic resection may be a reasonable alternative only in selected cases of small (< 1 cm) G1/G2 (Ki-67 < 5%) type 3 gNENs that have been completely endoscopically resected (R0) and that have no risk factors for metastatic disease^[25,26].

Different endoscopic techniques have been described to approach gNENs, and the majority of them proved to be radical^[27]. Conventional approaches, such as polypectomy and traditional endoscopic mucosal resection (EMR) with mucosal lifting and hot snare resection, have recently been compared with new techniques, such as modified EMR, endoscopic submucosal dissection (ESD) and endoscopic full-thickness resection (EFTR), which are more invasive options, but with higher radicality rates. The rationale behind this shift trend towards new techniques lies in the increasingly clear evidence of the existence of well-differentiated gNENs that are already metastatic at the diagnosis.

AIM

This narrative review aims to describe in detail various proposed techniques for gNENs resection, even including latest technical tips.

METHODS

This manuscript is a narrative review of the literature. We performed a systematic research in PubMed, Medline and Embase databases using the terms “gastric neuroendocrine neoplasms” and “endoscopy” or “endoscopic treatment”, and we selected original articles, with English written abstract available.

RESULTS

Excisional biopsy and polypectomy

Epidemiologically, most detected gNENs lesions are < 1 cm in diameter^[9], so that the most common and simple endoscopic treatment, especially when they are < 5 mm, is excisional biopsy, which has an overall diagnostic, staging, and therapeutic role^[28]. For lesions > 5 mm, endoscopic treatment should be performed if a therapeutic goal R0 can be achieved, and it can be performed with polypectomy or with more technically demanding endoscopic procedures, such as EMR, ESD, or EFTR^[29].

²⁵ **Cold snare polypectomy**

⁸
Cold snare polypectomy is a simple procedure in which the lesion is resected with a snare^[29]. The endoscopist advances the snare sheath, opens the snare, and encircles the polyp; then, the nurse slowly closes the snare until the lesion is trimmed, capturing 1-2 mm of normal tissue around the polyp. This technique can be performed without lifting the polyp. However, cold snare polypectomy can be performed also with fluid injection into the submucosal layer (e.g., saline), to lift the gNEN and then cut with the snare using the same technique. In this second option, more normal tissue around the lesion can be captured to achieve a R0 resection. However, in this case, single-layer snares are preferable to conventional ones, because of their higher mechanical cutting power^[30]. Cold snare polypectomy provides margins without coagulation artifacts^[31]. Potential complications with this technique include bleeding, which is usually controlled by applying clips after the incision, or perforation, which is very rare^[32,33].

Hot snare polypectomy

Hot snare polypectomy is very similar to the cold snare technique^[29], but in this case the snare not only cuts mechanically but it also applies electrocoagulation when it is completely closed around the lesion. In this way, even larger lesions can be removed *en bloc*. Hot snare polypectomy is mostly used for lesions > 10 mm, pedunculated, or for flat lesions, which are actually very rare among NENs.

EMR

Traditional EMR: EMR is the technical term for the snare resection after an appropriate lifting of the lesion. There are many solutions that can be injected into the submucosal layer to obtain it; glycerol and saline solution are most used. For the resection of larger (>

10 mm) or flat lesions, EMR, as mentioned earlier, has a lower rate of incomplete resection, compared with cold or hot snare polypectomy^[29]. The aim of EMR in gNENs is the *en bloc* R0 resection. However, although some studies show that EMR can achieve a high percentage of free resection margins in the smallest and most superficial lesions, conventional EMR sometimes cannot provide effective R0 resection, because many lesions already have submucosal involvement at the time of detection^[9].

Anchored EMR: Anchored EMR is a very similar technique to conventional EMR: After lifting the submucosal layer, the endoscopist places the snare tip on the normal tissue surrounding the lesion and performs a small incision using the electrocoagulation. The tip of the snare is then inserted into the small incision and thus anchored into the tissue, and this allows the rest of the snare to open more stably around the lesion, better guaranteeing *en bloc* resection^[34,35].

Cap band EMR: Cap band EMR is a technique mainly used for esophageal or cardial lesions^[36]. After aspirating ⁵ the lesion into the transparent cap of a band ligation set (DuetteTM Multi-band Mucosectomy Device®, Cook Medical, Bloomington, IN, United States), ⁵ an elastic band is placed around the base of the lesion. Resection can then be performed with an appropriate snare closed below the mucosectomy band^[37] (Figure 2D). The DuetteTM Multi-band Mucosectomy Device allows the *en bloc* EMR of small lesions. For larger lesions, this system allows only piece-meal resections, which limits the pathologist's capability to evaluate the lateral margins^[36].

A recent study compared traditional EMR with cap-band EMR for removal of gastric submucosal lesions, including some gNEN, showed ⁵ a similar *en bloc* resection rate which ⁵ was 97% for conventional saline- mucosectomy, and 100% for cap band mucosectomy technique^[38].

Under-water EMR: Under-water EMR is performed without lifting the lesion with any solution, but using the ability of water to lift the lesion^[39]. Filling the lumen with water, it allows the lesion to be lifted^[40]. The complications are comparable to those of conventional EMR^[39]. This technique has been shown to be more effective than traditional EMR for *en*

bloc resection of colonic lesions^[41], including rectal NENs^[42]. However, to date, only a few cases of underwater EMR in gNENs have been described^[43].

Overall, EMR is a safe, cost-effective, and technically simple procedure. However, its major limitation is associated to the size of the lesion, which often forces the endoscopist to perform a piece-meal resection, especially for lesions larger than 1 cm in diameter, with the risk of a lower rate of radical excision. According to recent studies, complete resection is achieved with EMR in 52%-84% of cases^[44,45]. Nevertheless, there is limited evidence to date on the role of piece-meal resection in NENs. In a study that included 14 gNENs between 10-20 mm, treated with EMR, complete resection was not achieved in six cases. However, no recurrence occurred in any of them after 5-year follow-up^[46]. Moreover, EMR often removes an amount of submucosal tissue insufficient to accurately define lymphatic vessel invasion, making an accurate histopathologic assessment impossible^[46,47]. In addition, it should be considered that neuroendocrine tumors are usually not confined to the mucosa but they frequently invade the submucosal layer^[48,49].

In case of incomplete resection, a second endoscopic procedure is more difficult due to fibrosis, with a higher risk of perforation. Hybrid techniques such as EMR/ESD or ESD alone, can better achieve R0 resection in larger lesions.

Endoscopic submucosal dissection

This technique, developed in Japan about 20 years ago for the endoscopic treatment of early gastric cancer, allows *en bloc* endoscopic resection (ER), regardless of tumor size, including the submucosal layer underneath the lesion, thus increasing the chance of histologically complete resection^[50]. In addition, examination of a substantial amount of submucosal tissue allows accurate determination of lymphatic invasion and histologic grading, which may guide subsequent therapeutic decisions^[47,51]. ESD is technically more demanding than EMR and it is associated with longer procedure times and higher risk of complications (bleeding and perforation). It consists of a delineating a circumferential excision zone around the lesion by using an electrocauterization knife, followed by the creation of a cushion under the lesion by the injecting of a viscous solution, and thus performing a dissection underneath the submucosal layer under direct visualization^[46,52] (Figure 2D-G).

In 2012, an initial study by Chen *et al*^[51] about the role of ESD in the management of gNENs examined 33 cases, including 22 type 1 and 11 type 3 gNENs. Histopathologic examination revealed a 100% complete resection rate, with horizontal and vertical negative margins and no lymphovascular invasions in all cases. Only one patient experienced delayed bleeding which could be controlled endoscopically, and no perforation was reported. Additional surgery was indicated for type 3 gNENs larger than 10 mm (7 cases), but only one patient agreed to undergo surgery. During a median follow-up of 28.9 mo, two local recurrences occurred both of which were successfully treated by ESD. No lymph node metastases (LNM), or distant metastases were observed in any patient^[51].

Two studies have examined the efficacy of ESD compared with EMR in the treatment of type 1 gNENs. The first was a small study of 13 Lesions by Sato *et al*^[53], that found a superiority of ESD in achieving complete resection with 100% negative horizontal and vertical margins, whereas positive vertical margins occurred in 66.7% of cases in the EMR group. A subsequent retrospective study by Kim *et al*^[47] performed on 87 small lesions (< 10 mm in diameter) confirmed these results: The histological rate of complete resection was higher in the ESD group (94.9%) than in the EMR group (83.3%), mainly because the vertical margins were significantly less affected in patients underwent ESD (2.6% vs 16.7%, $P = 0.038$). This is explained as EMR removes less submucosal tissue than ESD and for larger lesions only piece-meal resection is possible with higher risk of incomplete resection. Regarding safety, the bleeding rate was similar in both groups, but perforation occurred in one patient in the ESD group; all complications were successfully managed endoscopically^[47]. Despite these findings, pooled data analysis of a recent systematic review by Panzuto *et al*^[54] aiming at determining the best endoscopic technique (ESD, EMR, or polypectomy) in the management of type 1 gNENs did not show clear superiority of ESD over EMR in terms of efficacy and safety, with similar complete resection rates (97.4% and 92.3%, respectively) and complication rates (11.7% and 5.4%, respectively). Nevertheless, ESD demonstrated a lower risk of recurrence.

Regarding type 3 gNENs, studies reporting ESD are mainly focused on finding a proper indication for endoscopic resection (ER). In 2013, Kwon *et al*^[23] retrospectively collected data from 50 patients with type 3 gNENs less than 20 mm in size, who were endoscopically treated by EMR (41 patients) or ESD (9 patients). Complete pathologic

resection was achieved in 80.4% of all cases. ESD⁷ showed a lower complete resection rate than EMR (66.7% and 85.4%, respectively), probably due to larger average size of lesions in the ESD group. Lymphovascular invasion associated with larger tumor size was observed in 3 cases, although no statistical significance was found; all 3 patients subsequently underwent surgical resection. In the remaining patients, no local or distant¹ recurrence was observed during the median follow-up period of 46 mo, even in the case of incomplete resection. This study concluded that ER should be considered as initial treatment⁶ for type 3 gNENs smaller than 20 mm and confined to the submucosal layer^[23]. However, another South Korean study by Min *et al*^[55] reported that type 3 G2 and G3 gNENs⁶ had aggressive features with frequent metastases regardless of tumor size and depth of invasion. In this study only one patient had a LNM 68 mo after a complete ESD of a type 3 G1 gNEN of 19 mm, so the authors suggested that only for type 3 G1 gNENs no larger than 15 mm surgical wedge resection or endoscopic resection (EMR or ESD) can be considered as a valid option in the absence of lymphovascular invasion, positive vertical margin, and/or G2 grading; of the remaining patients only one developed LNM and liver metastases during a median follow-up of 32 mo. In this study, LNM occurred in 16.1% of cases and was observed in one patient with a 6 mm type 3 G1 gNEN. Given the risk of LNM, authors concluded that⁶ gastrectomy with lymph node dissection is recommended for all type 3 gNENs, even for small low grading tumors; however, given the overall and recurrence-free survival superior to 90%, ER for type 3 G1 gNENs ≤ 10 mm in size confined to submucosa could be an alternative therapeutic option despite the risk of LNM^[56]. Conversely, Li *et al*^[57] published a retrospective study reporting 33 ER (ESD and EMR) of G1-G2 type 3 gNENs, with no local recurrence, LNM or distant metastases¹ during a median follow-up period of 36 mo, and concluded that ER is safe and effective for G1-G2 type 3 gNENs confined to the submucosa and smaller than 20 mm. However, as mentioned before, no one of these studies was aimed to demonstrate the efficacy of ESD in this setting or its superiority over EMR, and therefore further studies are needed. Furthermore, no randomized controlled trials comparing EMR and ESD in gNENs resection are to date available^[58]. Data from a

Chinese retrospective study analyzing efficacy and safety of different endoscopic techniques on any GI NEN, proved ESD to have a higher pathological complete resection rate compared to EMR^[59].

EFTR

EFTR, performed with the application of an ²over-the-scope-clip (OVESCO®, Tübingen, Germany), has been shown to be feasible, effective, and safe for small colorectal subepithelial tumors^[60]. A multicenter retrospective study has shown that EFTR could be a rapid, effective, and safe alternative for the removal of rectal NEN < 20 mm^[61]. Several studies investigated ²⁰the role of EFTR in the management of gastric subepithelial tumors, but to date very few data are available on gNENs^[62-67]. In the RESET trial, three gNENs with a size of < 15 mm were removed by using the gastric EFTR device, and R0 ¹resection was obtained in all cases; no recurrence was detected at 3-mo follow up^[67]. Anyway, further prospective, or controlled studies are needed to clarify whether EFTR has a standardized role in the treatment of gNEN.

Table 1 summarizes key information regarding the possible endoscopic therapeutic approaches for the different types of gNENs.

Endoscopic surveillance

Endoscopic surveillance after endoscopic treatment of gNENs has never been validated in prospective studies^[68,69], so it is mainly based on histology. If resection margins are positive or indeterminate, the patient should undergo gastroscopy after 3-6 mo. If macroscopic residual disease is detected, a second and more aggressive endoscopic treatment is recommended. Otherwise, taking a biopsy from the scar is suggested^[70].

After R0 endoscopic resection of type 1 gNEN, follow-up with an upper GI endoscopy is recommended every 6-12 mo in the first three years, and annually thereafter; after endoscopic resection of type 2 or 3 gNENs, annually follow-up is suggested^[70]. According to an Italian prospective study, a specific timing has also been proposed for type 1 gNENs based on the tumor recurrence rate^[71].

CONCLUSION

GNENs include different subtypes of neoplasms with distinct management and prognoses. After proper evaluation of size, site, morphology, and clinical context, different endoscopic techniques have been shown to be appropriate to treat GI localized neoplasms. To simplify, small lesions, especially when < 5 mm, can be radically resected by excisional biopsy or, if pedunculated, by polypectomy (cold or hot snare); > 5 mm type 1 and 2 (G1, G2, and G3) gNENs, and for type 3 (G1) , if confined to the submucosal layer and without LNM or distant metastases, the therapeutic goal of R0 could be achieved by both modified EMR techniques (anchored, cap band and under-water EMR) and ESD; ESD might be preferred over EMR for larger lesions, > 1 cm in diameter, but no randomized controlled trials are yet available to confirm this. Larger type 3 G2/G3 gNENs should undergo surgery. Endoscopic ultrasound might achieve a more standardized role in the therapeutic diagram of gastric neuroendocrine lesions. Further randomized, controlled head-to-head studies with homogeneous and stratified patients are needed.

Figure 1 Different clinical and biochemical aspects of the three types of gastric neuroendocrine neoplasms^[3]. Type 1 (A), type 2 (B), and type 3 (C). Citation: Delle Fave G, O'Toole D, Sundin A, Taal B, Ferolla P, Ramage JK, Ferone D, Ito T, Weber W, Zheng-Pei Z, De Herder WW, Pascher A, Ruzsniowski P, Vienna Consensus Conference participants. ENETS Consensus Guidelines Update for Gastroduodenal Neuroendocrine Neoplasms. *Neuroendocrinology* 2016; **103**: 119-124. Copyright ©The Author(s) 2016. gNEN: Gastric neuroendocrine neoplasms; CAAG: Chronic atrophic autoimmune gastritis; MEN: Multiple endocrine neoplasia; ZES: Zollinger-Ellison Syndrome.

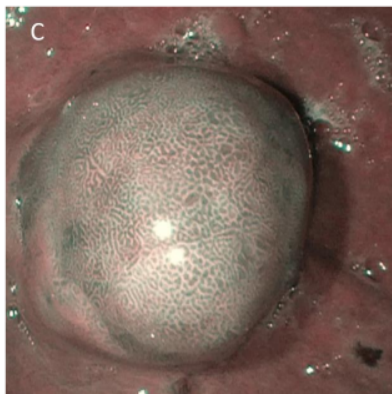


Figure 2 Gastrointestinal endoscopy. A and B: White light endoscopic aspect of gastric neuroendocrine neoplasms; C: Chromoendoscopic blue light endoscopic aspect of gastric neuroendocrine neoplasms; D: Cap band endoscopic mucosal resection of a gastric neuroendocrine neoplasm; E-G: Endoscopic submucosal dissection of a gastric neuroendocrine neoplasm.

Table 1 Endoscopic therapeutic approaches for the different types of well-differentiated gastric neuroendocrine neoplasms

	Type 1 gNEN (any grade)	Type 2 gNEN (any grade)	Type 3 gNEN (G1)	Type 3 gNEN (G2, G3)
Endoscopic presentation	Small, located in the gastric body or fundus, associated with CAAG	Small, multiple lesions, associated with gastrinoma (MEN1)	Larger, infiltrative, sporadic, single lesions	Larger, infiltrative, sporadic, single lesions
Risk of metastases	< 5%	10%-30%	50%-90%	50%-90%
Suggested resection technique	< 5 mm: endoscopic surveillance vs excisional biopsy 5-10 mm: polypectomy vs EMR (traditional or modified) vs ESD (ESD lower risk of recurrence) > 10 mm: EUS (to make sure it is confined to the submucosal layer, without LNM) + modified EMR vs ESD (no randomized trials)	< 5 mm: endoscopic surveillance vs excisional biopsy 5-10 mm: polypectomy vs EMR (traditional or modified) vs ESD (ESD lower risk of recurrence) > 10 mm: EUS (to make sure it is confined to the submucosal layer, without LNM) + modified EMR vs ESD (no randomized trials)	< 5 mm: excisional biopsy vs polypectomy 5-10 mm: modified EMR vs ESD (no randomized trials) > 10 mm: surgery vs EUS + ESD (possible role of EFTR)	Surgery (regardless of the size)

In case of incomplete resection: hybrid endoscopic mucosal resection/endoscopic submucosal (ESD) or ESD. CAAG: Chronic atrophic autoimmune gastritis; EFTR: Endoscopic full-thickness resection; EMR: Endoscopic mucosal resection; ESD: Endoscopic

submucosal dissection; EUS: Endoscopic ultrasound; gNEN: Gastric neuroendocrine
neoplasms; LNM: Lymph node metastases; MEN: Multiple endocrine neoplasia.

12%

SIMILARITY INDEX

PRIMARY SOURCES

- 1

f6publishing.blob.core.windows.net
Internet

95 words — 2%
- 2

worldwidescience.org
Internet

44 words — 1%
- 3

Camilla Gallo, Roberta Elisa Rossi, Federica Cavalcoli, Federico Barbaro, Ivo Boškoski, Pietro Invernizzi, Sara Massironi. "Rectal neuroendocrine tumors: Current advances in management, treatment, and surveillance", World Journal of Gastroenterology, 2022
Crossref

41 words — 1%
- 4

"Neuroendocrine Neoplasia Management", Springer Science and Business Media LLC, 2021
Crossref

39 words — 1%
- 5

Cetin Karaca, Ebubekir S. Daglilar, Ozlem Mutluay Soyer, Mine Gulluoglu, William R. Brugge. "Endoscopic submucosal resection of gastric subepithelial lesions smaller than 20mm: a comparison of saline solution-assisted snare and cap band mucosectomy techniques", Gastrointestinal Endoscopy, 2017
Crossref

33 words — 1%
- 6

B.-H. Min, M. Hong, J. H. Lee, P.-L. Rhee, T. S. Sohn, S. Kim, K.-M. Kim, J. J. Kim. "Clinicopathological features

28 words — 1%

and outcome of type 3 gastric neuroendocrine tumours",
British Journal of Surgery, 2018

Crossref

7 Roberta Elisa Rossi, Emanuele Rausa, Federica Cavalcoli, Dario Conte, Sara Massironi. "Duodenal neuroendocrine neoplasms: a still poorly recognized clinical entity", Scandinavian Journal of Gastroenterology, 2018

25 words — 1%

Crossref

8 www.dovepress.com

Internet

25 words — 1%

9 daneshyari.com

Internet

16 words — < 1%

10 Massironi, Sara, Alessandra Zilli, Ilaria Fanetti, Clorinda Ciafardini, Dario Conte, and Maddalena Peracchi. "Intermittent treatment of recurrent type-1 gastric carcinoids with somatostatin analogues in patients with chronic autoimmune atrophic gastritis", Digestive and Liver Disease, 2015.

14 words — < 1%

Crossref

11 pure.uva.nl

Internet

14 words — < 1%

12 "Diagnostic Imaging for Thoracic Surgery", Springer Science and Business Media LLC, 2018

Crossref

13 words — < 1%

13 assets.cureus.com

Internet

12 words — < 1%

14 "Liver Cancers", Springer Science and Business Media LLC, 2019

Crossref

11 words — < 1%

-
- 15 www.scribd.com 9 words — < 1%
Internet
-
- 16 Ashley Kieran Clift, Oskar Kornasiewicz, Panagiotis Drymoussis, Omar Faiz et al. "Goblet cell carcinomas of the appendix: rare but aggressive neoplasms with challenging management", *Endocrine Connections*, 2018 8 words — < 1%
Crossref
-
- 17 I. Borbath, U. - F. Pape, P.H. Deprez, D. K. Bartsch et al. "ENETS standardized (synoptic) reporting for endoscopy in neuroendocrine tumors", *Journal of Neuroendocrinology*, 2022 8 words — < 1%
Crossref
-
- 18 Marina Tsoli, Eleftherios Chatzellis, Anna Koumarianou, Dionysia Kolomodi, Gregory Kaltsas. "Current best practice in the management of neuroendocrine tumors", *Therapeutic Advances in Endocrinology and Metabolism*, 2018 8 words — < 1%
Crossref
-
- 19 Weili Sun, Siyuan Wu, Xiao Han, Chuanhua Yang. "Effectiveness of Endoscopic Treatment for Gastrointestinal Neuroendocrine Tumors", *Medicine*, 2016 8 words — < 1%
Crossref
-
- 20 library.unisel.edu.my 8 words — < 1%
Internet
-
- 21 watermark.silverchair.com 8 words — < 1%
Internet
-
- 22 "AGA Institute and Digestive Disease Week 2007 Program Pages", *Gastroenterology*, 200704 7 words — < 1%
Crossref

23 "Endocrine Pathology", Springer Science and Business Media LLC, 2022 6 words — < 1%
Crossref

24 "Neuroendocrine Tumors in Real Life", Springer Science and Business Media LLC, 2018 6 words — < 1%
Crossref

25 Alessandro Repici, Andrea Anderloni, Manol Jovani, Cesare Hassan. "Advances, problems, and complications of polypectomy", Clinical and Experimental Gastroenterology, 2014 6 words — < 1%
Crossref

26 Chen-Shuan Chung, Cho-Lun Tsai, Yin-Yi Chu, Kuan-Chih Chen et al. "Clinical features and outcomes of gastric neuroendocrine tumors after endoscopic diagnosis and treatment", Medicine, 2018 6 words — < 1%
Crossref

27 Hüseyin Köseoğlu, Tolga Duzenli, Mesut Sezikli. "Gastric neuroendocrine neoplasms: A review", World Journal of Clinical Cases, 2021 6 words — < 1%
Crossref

EXCLUDE QUOTES OFF

EXCLUDE SOURCES OFF

EXCLUDE BIBLIOGRAPHY OFF

EXCLUDE MATCHES OFF