

国内版国际版

Microsoft Bing

Chat with Bing

Sign in

Hepatocellular carcinoma with tumour thrombus extended to the right

ALLIMAGESVIDEOS

27,000 ResultsAny time

Hepatocellular Carcinoma with Tumor Thrombus Extending ...

<https://www.ncbi.nlm.nih.gov/pmc/articles/PMC6639066>

May 17, 2019 · Hepatocellular carcinoma (HCC) is one of the most common malignant tumors. Tumor thrombus formation in advanced HCC stages is common and usually involves the hepatic or portal veins. The formation of tumor thrombus is considered a poor prognostic factor.

Author: Laith Numan, Samia Asif, Omar K Abu... Publish Year: 2019

Hepatocellular Carcinoma With Tumor Thrombus Occupying ...

<https://www.ncbi.nlm.nih.gov/pmc/articles/PMC4602908>

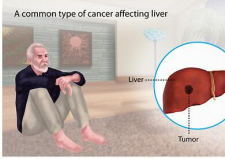
Aug 28, 2015 · Hepatocellular carcinoma (HCC) patients with tumor thrombus extended through the major hepatic veins and inferior vena cava into the right atrium (RA) are rare, and most cases are considered as the advanced stage with a poor prognosis. We report a case of HCC with a tumor thrombus extending into the RA and a tumor thrombus in the portal vein.

Cited by: 10 Author: Xin Luo, Binhao Zhang, Shuilin Dong, Bix...

Hepatocellular Carcinoma

Medical Condition

A common type of cancer affecting liver



The most common form of liver cancer is seen in people with chronic liver disease



Hepatocellular carcinoma with tumour thrombus extended to the ri



ALL IMAGES VIDEOS MAPS NEWS SHOPPING

17,200 Results Any time ▾

Hepatocellular Carcinoma With Tumor Thrombus Occupying the ...

<https://www.ncbi.nlm.nih.gov/pmc/articles/PMC4602908>

Aug 28, 2015 · Hepatocellular carcinoma (HCC) patients with tumor thrombus extended through the major hepatic veins and inferior vena cava into the right atrium (RA) are rare, and most cases are considered as the advanced stage with a poor prognosis. We report a case of HCC with a tumor thrombus extending into the RA and a tumor thrombus in the portal vein.

Cited by: 11 Author: Xin Luo, Binhao Zhang, Shulin Dong, Bix...
Publish Year: 2015

Hepatocellular Carcinoma With Tumor Thrombus Extending ...

<https://pubmed.ncbi.nlm.nih.gov/31338266>

Hepatocellular carcinoma (HCC) is one of the most common malignant tumors. Tumor thrombus formation in advanced HCC stages is common and usually involves the hepatic or portal veins. The formation of tumor thrombus is considered a poor prognostic factor.

Author: Laith Numan, Samia Asif, Omar K Abu... Publish Year: 2019

(PDF) Hepatocellular Carcinoma With Tumor Thrombus ...

<https://www.researchgate.net/publication/281338795...>

Hepatocellular carcinoma (HCC) patients with tumor thrombus extended through the major hepatic veins and inferior vena cava into the right atrium (RA) ...

PEOPLE ALSO ASK

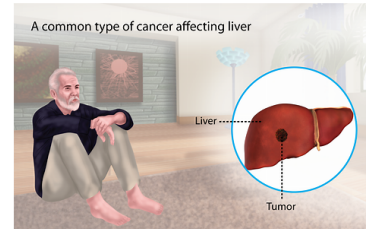
What is hepatic vein tumor thrombus?	▼
What is intravascular tumor thrombus?	▼
What is the prognosis of HCC with tumor thrombus?	▼
Can you milk a tumor thrombus?	▼

u/global.bing.com/?FORM=Z9FD1

Feedback

Hepatocellular Carcinoma

Medical Condition



The most common form of liver cancer often seen in people with chronic liver diseases like cirrhosis.

- Rare (Fewer than 200,000 cases per year in US)
- May be preventable by vaccine
- Often requires lab test or imaging
- Treatment from medical professional advised
- Can last several months or years

Caused mainly due to the chronic infection of the liver or DNA mutation of the liver cells. Characterized by unexplained weight loss, upper abdominal pain and yellowing of the skin. Treatment options include hepatectomy, target drug delivery and the use of radiation to kill the cancerous cells.

Symptoms

The early stages of the disease do not reveal any symptoms but in the

06-Sep-2020 05:55PM

3541 words • 17 matches • 12 sources

FAQ

iThenticate®

57257-Review-check.docx

Quoted Included
Bibliography Included
13%

Name of Journal: *World Journal of Hepatology*

Manuscript NO: 57257

Manuscript Type: **CASE REPORT**

Hepatocellular carcinoma with tumour thrombus extended to the right atrium and portal vein: A case report

Gomez-Puerto D *et al.* HCC with tumour thrombus

Diego Gomez-Puerto, Oriol Mirallas, Judit Vidal-González, Victor Vargas

Abstract

BACKGROUND

Hepatocellular carcinoma (HCC) is the most important primary malignant liver disease. A large proportion of patients with advanced HCC have macrovascular invasion. HCC tends to infiltrate vascular structures, particularly the portal vein and its branches, and more rarely, the hepatic veins. The intravascular tumour thrombus can affect the inferior vena cava (IVC) or even the right atrium (RA), the latter having a poor prognosis.

Match Overview

1

Internet 59 words
crawled on 17-May-2019
[www.cureus.com](#)

2%

2

Internet 58 words
crawled on 01-Jul-2020
[hessara.spenedios-publications.com](#)

2%

3

Internet 41 words
crawled on 20-Oct-2019
[www.invasivecardiology.com](#)

2%

4

Crossref 30 words
Chai Hong Rim, Hyung Joon Yim, Sunmin Park, Jinil Seong
"Recent clinical applications of external beam radiother

1%

5

Internet 29 words
crawled on 07-Mar-2020
[www.jstage.jst.go.jp](#)

1%

6

Internet 18 words
crawled on 24-May-2019
[wargulakareports.springeropen.com](#)

1%

7

Internet 17 words
crawled on 24-Jun-2020
[dozz.net](#)

1%

8

Internet 15 words
crawled on 12-Aug-2020
[maliadoc.com](#)

1%

9

Crossref 15 words
Luo, Xin, Binhao Zhang, Shulin Dong, Bixiang Zhang, and Xiaoping Chen. "Hepatocellular Carcinoma With Tumor T...

1%

10

Crossref Posted Content 14 words
Jiacheng Wu, Xiaodao Yao, Yien Xiang, Xianchi Gu, Shui Liu, Xuwen Zhang. "PCX2-A potential Therapeutic Target

1%

国内版 国际版

Hepatocellular carcinoma with tumour thrombus extended to the r



ALL IMAGES VIDEOS

16,700 Results Any time ▾

Hepatocellular Carcinoma With Tumor Thrombus Occupying the ...

<https://www.ncbi.nlm.nih.gov/pmc/articles/PMC4602908>

Aug 28, 2015 · **Hepatocellular carcinoma (HCC)** patients with **tumor thrombus extended** through the major **hepatic veins** and inferior vena cava into the **right atrium (RA)** are rare, and most cases are considered as the advanced stage with a poor prognosis. We report a case of **HCC** with a **tumor thrombus extending** into the RA and a **tumor thrombus** in the **portal vein**.

Cited by: 11

Author: Xin Luo, Binhao Zhang, Shuilin Dong, Bi...

Publish Year: 2015

Hepatocellular Carcinoma With Tumor Thrombus Extending ...

<https://pubmed.ncbi.nlm.nih.gov/31338266>

Hepatocellular carcinoma (HCC) is one of the most common **malignant tumors**. **Tumor thrombus formation** in **advanced HCC stages** is common and usually involves the **hepatic** or **portal veins**. The formation of **tumor thrombus** is considered a poor prognostic factor. Herein, we report a rare case wherein the **thrombus extended** to the inferior **vena cava (IVC)** **reaching the right atrium** ...

Author: Laith Numan, Samia Asif, Omar K Ab...

Publish Year: 2019

Cureus | Hepatocellular Carcinoma Presenting With Inferior ...

<https://www.cureus.com/articles/37275-hepatocellular-carcinoma-presenting-with...>

Hepatocellular carcinoma (HCC) is the most common primary liver tumor, and its incidence has been on the rise worldwide. It is a common cause of **cancer**-related death. HCC carries a poor prognosis and is challenging to manage, especially when diagnosed in advanced stages. We present a rare **case** of HCC in liver cirrhosis secondary to viral hepatitis C (HCV) infection, presenting ...

Author: Ragia Aly, Sachin Gupta, Ruby Gupt...

Publish Year: 2020

PEOPLE ALSO ASK