



25263-Review

Quotes Excluded
Bibliography Excluded6%
SIMILARName of Journal: *World Journal of Hepatology*

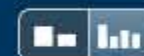
ESPS Manuscript NO: 25263

Manuscript Type: Case Report

Spontaneous liver rupture as first sign of Polyarteritis Nodosa

Irene Gómez, Felipe Alconchel, Rubén Ciria, M Dolores Ayllón, Antonio
Luque, Marina Sánchez, Pedro López-Cillero, Javier Briceño**Abstract**

Polyarteritis nodosa (PAN) is one of the systemic vasculitis that affects the media wall of arteries of small and medium diameter. Diagnosis proves difficult due to the unspecific symptoms that dominate the clinical profile. Liver involvement is very diverse, ranging from the development of cirrhotic liver disease to acute abdomen presentation that requires surgery because of

Match Overview

- 1** **Crossref** 83 words
"ESP Abstracts 2015", *Virchows Archiv*, 2015. 5%
- 2** **Internet** 13 words
crawled on 05-Jun-2014
journalgateway.com 1%

[全部](#)[图片](#)[新闻](#)[视频](#)[更多 ▾](#)[搜索工具](#)

找到约 489,000 条结果 (用时 0.87 秒)

Spontaneous liver rupture in polyarteritis nodosa

onlinelibrary.wiley.com/doi/10.1002/bjs.1800660410/pdf ▾ [翻译此页](#)

作者: AKC Li - 1979 - 被引用次数: 11 - 相关文章

Spontaneous liver rupture in polyarteritis nodosa ... associated with polyarteritis nodosa is reported. liver was due to massive bleeding from an aneurysmal.

Polyarteritis nodosa presenting with spontaneous perirenal ...

www.ncbi.nlm.nih.gov ▸ ... ▸ [PubMed Central \(PMC\)](#) ▾ [翻译此页](#)

作者: P Mukhopadhyay - 2012 - 被引用次数: 2 - 相关文章

Spontaneous perirenal hematoma following ruptured microaneurysm is an ... An association with hepatitis B virus infection is well documented in 7–36% of cases.[9] of the sigmoid colon with ischemic change due to polyarteritis nodosa.

Spontaneous rupture of the liver in a patient with chronic ...

www.ncbi.nlm.nih.gov ▸ ... ▸ [PubMed Central \(PMC\)](#) ▾ [翻译此页](#)

作者: CJ Liu - 2007 - 被引用次数: 3 - 相关文章

2007年8月28日 - Li et al[9] speculated that spontaneous liver rupture in polyarteritis nodosa is due to massive bleeding from an aneurysmal intrahepatic artery.

Spontaneous rupture of hepatocellular carcinoma with ...

www.ncbi.nlm.nih.gov ▸ ... ▸ [PubMed Central \(PMC\)](#) ▾ [翻译此页](#)

作者: AD Chedid - 2001 - 被引用次数: 8 - 相关文章

[全部](#)[图片](#)[新闻](#)[视频](#)[更多 ▾](#)[搜索工具](#)

找到约 3,800,000 条结果 (用时 0.82 秒)

Spontaneous liver rupture in polyarteritis nodosa - Wiley Online Library

onlinelibrary.wiley.com/doi/10.1002/bjs.1800660410/pdf ▾ [翻译此页](#)

作者: AKC Li - 1979 - 被引用次数: 12 - [相关文章](#)

Spontaneous liver rupture in polyarteritis nodosa ... associated with polyarteritis nodosa is reported. liver was due to massive bleeding from an aneurysmal.

Polyarteritis nodosa presenting with spontaneous perirenal hematoma

www.ncbi.nlm.nih.gov > NCBI > Literature > PubMed Central (PMC) ▾ [翻译此页](#)

作者: P Mukhopadhyay - 2012 - 被引用次数: 3 - [相关文章](#)

[1] Spontaneous perirenal bleeding secondary to PAN was first described by Schmidt[2] in 1908. He remained asymptomatic with no recurrence of symptoms at 6 months of follow up and Spontaneous liver rupture in polyarteritis nodosa.

Spontaneous rupture of the liver in a patient with chronic hepatitis B ...

www.ncbi.nlm.nih.gov > NCBI > Literature > PubMed Central (PMC) ▾ [翻译此页](#)

作者: CJ Liu - 2007 - 被引用次数: 2 - [相关文章](#)

2007年8月28日 - Li et al[9] speculated that spontaneous liver rupture in polyarteritis nodosa is due to massive bleeding from an aneurysmal intrahepatic artery.

Polyarteritis Nodosa: Background, Pathophysiology, Etiology

emedicine.medscape.com/article/330717-overview ▾ [翻译此页](#)

2016年1月12日 - Classic polyarteritis nodosa (PAN or c-PAN) is a systemic vasculitis characterized by ... resulting in microaneurysm formation, aneurysmal rupture with hemorrhage, ... systemic involvement may be the first sign of polyarteritis nodosa (PAN). ... Presence of hepatitis B surface antigen or antibody in serum.

[PDF] Spontaneous intra-hepatic haemorrhage in a patient with fever of



全部

图片

新闻

视频

更多 ▾

搜索工具

找到约 3,950,000 条结果 (用时 0.57 秒)

Polyarteritis nodosa presenting with spontaneous perirenal hematoma

www.ncbi.nlm.nih.gov > [NCBI](#) > [Literature](#) > [PubMed Central \(PMC\)](#) ▾ [翻译此页](#)

作者: P Mukhopadhyay - 2012 - 被引用次数: 3 - 相关文章

Spontaneous perirenal hematoma following ruptured microaneurysm is an ... An association with hepatitis B virus infection is well documented in 7–36% of cases.[9] of the sigmoid colon with ischemic change due to polyarteritis nodosa.

Spontaneous liver rupture in polyarteritis nodosa - Wiley Online Library

onlinelibrary.wiley.com/doi/10.1002/bjs.1800660410/pdf ▾ [翻译此页](#)

作者: AKC Li - 1979 - 被引用次数: 12 - 相关文章

Spontaneous liver rupture in polyarteritis nodosa ... associated with polyarteritis nodosa is reported. ... liver was due to massive bleeding from an aneurysmal.

Spontaneous liver rupture in polyarteritis nodosa - Li - 1979 - British ...

onlinelibrary.wiley.com/doi/10.1002/bjs.1800660410/abstract ▾ [翻译此页](#)

作者: AKC Li - 1979 - 被引用次数: 12 - 相关文章

Spontaneous liver rupture in polyarteritis nodosa ... First published: April 1979 Full publication history; DOI: 10.1002/bjs.1800660410View/save citation; Cited by: ...

Polyarteritis Nodosa: Background, Pathophysiology, Etiology

emedicine.medscape.com/article/330717-overview ▾ [翻译此页](#)

2016年1月12日 - Classic polyarteritis nodosa (PAN or c-PAN) is a systemic vasculitis characterized by ... resulting in microaneurysm formation, aneurysmal rupture with hemorrhage, ... systemic involvement may be the first sign of polyarteritis nodosa (PAN). ... Presence of hepatitis B surface antigen or antibody in serum.

[PDF] Spontaneous intra-hepatic haemorrhage in a patient with fever of ...