



22483-Review

Quotes Excluded
Bibliography Excluded14%
SIMILARName of Journal: *World Journal of Radiology*

ESPS Manuscript NO: 22483

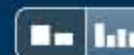
Manuscript Type: Minireviews

Imaging of peritoneal deposits in ovarian cancer: A pictorial review

Sheragaru Hanumanthappa Chandrashekhara, Gowramma Sannanaik Triveni, Rahul Kumar

Abstract

As per incidence, ovarian carcinoma is the second most common gynaecological malignancy in female. In spite of advanced technology, patient awareness and effective screening methods, epithelial ovarian cancer is usually diagnosed in advanced stage (stage III). Surgical debulking of disease is mainstay of improving the patient survival even in advanced stage. Thus exact delineation of cancer spread in the abdominal cavity guides the surgeon prior to the surgery, help them to decide resectability of lesion and plan for further need of other surgical speciality or need of neoadjuvant chemotherapy. Imaging particularly well planned contrast enhanced computed tomography answers most of the queries raised by the treating surgeon. The aim of this article is to review the

Match Overview

- | Rank | Source | Words | Match % |
|------|---|----------|---------|
| 1 | CrossCheck Nougaret, S., H. C. Addley, P. E. Colombo, S. Fujii, S. S. Al Sharif, S. H. Tirumani, K. Jardon, E. Sala, and C. Reinhold. "C... | 80 words | 6% |
| 2 | CrossCheck Halkia, Evgenia, John Spiliotis, and Paul Sugarbaker. "Diagnosis and Management of Peritoneal Metastases from Ovarian | 55 words | 4% |
| 3 | CrossCheck Ying Gao. "Intraoperative radiotherapy electron boost in advanced and recurrent epithelial ovarian carcinoma: a retrospe | 31 words | 2% |
| 4 | CrossCheck Meyers Dynamic Radiology of the Abdomen, 2011. | 20 words | 1% |
| 5 | CrossCheck Michiaki Yakushiji. "Current role of chemotherapy in the management of ovarian cancer", Seminars in Surgical Oncology, | 13 words | 1% |

[全部](#)[图片](#)[新闻](#)[视频](#)[购物](#)[更多 ▾](#)[搜索工具](#)

找到约 32,400 条结果 (用时 0.47 秒)

Google 学术: Imaging of peritoneal deposits in ovarian cancer: A pictorial review

... Imaging of Peritoneal Disease for Noninvasive Staging ... - Kyriazi - 被引用次数: 73

Imaging appearances of Sister Mary Joseph nodule. - Coll - 被引用次数: 32

... tumors of the ovary: CT and MRI features and tumor ... - deSouza - 被引用次数: 59

Omental cakes: unusual aetiologies and CT appearances

www.ncbi.nlm.nih.gov > ... > PubMed Central (PMC) ▾ [翻译此页](#)

作者: MD Mamlouk - 2011 - 被引用次数: 7 - [相关文章](#)

2011年5月22日 - Omental cakes typically are associated with ovarian carcinoma, as this CT showed peripherally enhancing deposits in the peritoneal cavity in a Diffusion-weighted MR imaging of female pelvic tumours: a pictorial review.

CT, MRI and PET imaging in peritoneal malignancy

www.ncbi.nlm.nih.gov > ... > PubMed Central (PMC) ▾ [翻译此页](#)

作者: CM Patel - 2011 - 被引用次数: 16 - [相关文章](#)

2011年8月24日 - This article reviews established and new techniques in CT, MRI and PET (a) Coronal and (b) sagittal pictorial diagram showing flow of peritoneal fluid Metastatic ovarian carcinoma with calcified peritoneal deposits on ...

[全部](#)[图片](#)[新闻](#)[视频](#)[购物](#)[更多 ▾](#)[搜索工具](#)

找到约 32,400 条结果 (用时 0.47 秒)

Google 学术: Imaging of peritoneal deposits in ovarian cancer: A pictorial review

... Imaging of Peritoneal Disease for Noninvasive Staging ... - Kyriazi - 被引用次数: 73

Imaging appearances of Sister Mary Joseph nodule. - Coll - 被引用次数: 32

... tumors of the ovary: CT and MRI features and tumor ... - deSouza - 被引用次数: 59

Omental cakes: unusual aetiologies and CT appearances

www.ncbi.nlm.nih.gov > ... > PubMed Central (PMC) ▾ [翻译此页](#)

作者: MD Mamlouk - 2011 - 被引用次数: 7 - 相关文章

2011年5月22日 - Omental cakes typically are associated with ovarian carcinoma, as this CT showed peripherally enhancing deposits in the peritoneal cavity in a Diffusion-weighted MR imaging of female pelvic tumours: a pictorial review.

CT, MRI and PET imaging in peritoneal malignancy

www.ncbi.nlm.nih.gov > ... > PubMed Central (PMC) ▾ [翻译此页](#)

作者: CM Patel - 2011 - 被引用次数: 16 - 相关文章

2011年8月24日 - This article reviews established and new techniques in CT, MRI and PET (a) Coronal and (b) sagittal pictorial diagram showing flow of peritoneal fluid Metastatic ovarian carcinoma with calcified peritoneal deposits on ...

[全部](#)[图片](#)[新闻](#)[视频](#)[更多 ▾](#)[搜索工具](#)

找到约 55,900 条结果 (用时 0.59 秒)

Google 学术: Imaging of peritoneal deposits in ovarian cancer: A pictorial review

... Imaging of Peritoneal Disease for Noninvasive Staging ... - Kyriazi - 被引用次数: 74

Imaging appearances of Sister Mary Joseph nodule. - Coll - 被引用次数: 32

... tumors of the ovary: CT and MRI features and tumor ... - deSouza - 被引用次数: 60

Omental cakes: unusual aetiologies and CT appearances

www.ncbi.nlm.nih.gov > ... > PubMed Central (PMC) ▾ 翻译此页

作者: MD Mamlouk - 2011 - 被引用次数: 7 - 相关文章

2011年5月22日 - Omental cakes typically are associated with ovarian carcinoma, as this CT showed peripherally enhancing deposits in the peritoneal cavity in a Diffusion-weighted MR imaging of female pelvic tumours: a pictorial review.

CT, MRI and PET imaging in peritoneal malignancy

www.ncbi.nlm.nih.gov > ... > PubMed Central (PMC) ▾ 翻译此页

作者: CM Patel - 2011 - 被引用次数: 17 - 相关文章

2011年8月24日 - This article reviews established and new techniques in CT, MRI and PET (a) Coronal and (b) sagittal pictorial diagram showing flow of peritoneal fluid Metastatic ovarian carcinoma with calcified peritoneal deposits on ...

Common primary tumours of the abdomen and pelvis and their

www.ncbi.nlm.nih.gov > ... > PubMed Central (PMC) ▾ 翻译此页

作者: N Griffin - 2011 - 被引用次数: 3 - 相关文章

2011年4月14日 - The purpose of this pictorial review is to discuss the imaging