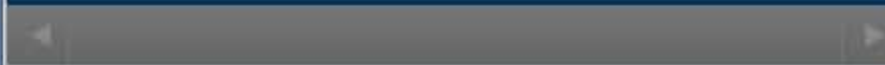


## Match Overview



There are no matching sources for this report.

Name of journal: World Journal of Cardiology

ESPS Manuscript NO: 19955

Manuscript Type: Letter to the editor

**Imaging of pannus formation in patients with mechanical heart valves**

Sabahattin Gündüz, Mehmet Özkan , Mahmut Yesin

### Abstract

Patient-prosthesis mismatch (PPM) should be recognized in patients with elevated transprosthetic gradients but without leaflet immobility, since the treatment strategy may differ in either etiology. However, thrombus and/or pannus formation should be excluded before a diagnosis of PPM is made. Particularly, pannus formation may not be diagnosed with 2-dimensional transesophageal echocardiography. Electrocardiographically gated 64-section multidetector computed tomography (MDCT) may be a promising tool in diagnosing or excluding pannus formation. Our report underlines the utility of MDCT in this regard and also emphasizes the importance of recognition of PPM as a differential diagnosis in such patients.



Imaging of pannus formation in patients with mechanical heart valves



网页 图片 新闻 视频 地图 更多 搜索工具

找到约 38,000 条结果 (用时 0.82 秒)

## Google 学术: Imaging of pannus formation in patients with mechanical heart valves

... pannus formation in obstructed mechanical prosthetic ... - Barbetseas - 被引用次数: 183

... Imaging Committee, Cardiac Imaging Committee of the ... - Zoghbi - 被引用次数: 352

... tomography scanner for detecting pannus formation - Teshima - 被引用次数: 53

### Diagnosis of the prosthetic heart valve pannus formation ... [ehjci.oxfordjournals.org/content/11/4/E17](http://ehjci.oxfordjournals.org/content/11/4/E17) - 翻译此页

作者: M Özkan - 2010 - 被引用次数: 16 - 相关文章

2009年12月18日 - Prosthetic heart valve obstruction (PHVO) caused by pannus formation is ... imaging techniques are needed in patients with suspected pannus formation. ... between cardiac structures than two-dimensional imaging, as well as ...

### Utility of cardiac computed tomography for evaluation of ... [link.springer.com/article/10.1007/s10554-015-0683-1](http://link.springer.com/article/10.1007/s10554-015-0683-1) - 翻译此页

2015年5月21日 - The International Journal of Cardiovascular Imaging ... is helpful in the evaluation of pannus formation in patients with mechanical aortic valves.

### Limitations of multimodality imaging in the diagnosis of ... [www.ncbi.nlm.nih.gov](http://www.ncbi.nlm.nih.gov) > ... > Literature > PubMed Central (PMC) - 翻译此页

作者: JB Soumoulou - 2015

2015年4月26日 - This diagnosis should be considered in patients with high ... We present a case of pannus formation in a prosthetic aortic valve and a review of ...

### Diagnosis of the prosthetic heart valve pannus formation ...



Imaging of pannus formation in patients with mechanical heart valves



网页

图片

新闻

视频

更多

搜索工具

找到约 20,400 条结果 (用时 0.57 秒)

## Google 学术: Imaging of pannus formation in patients with mechanical heart valves

... pannus formation in obstructed mechanical prosthetic ... - Barbetseas - 被引用次数: 186

... Imaging Committee, Cardiac Imaging Committee of the ... - Zoghbi - 被引用次数: 389

... of prosthetic heart valves: diagnosis and therapeutic ... - Roudaut - 被引用次数: 127

### Diagnosis of the prosthetic heart valve pannus formation ...

[ehjcardimaging.oxfordjournals.org/content/11/4/E17](http://ehjcardimaging.oxfordjournals.org/content/11/4/E17) - 翻译此页

作者: M Özkan - 2010 - 被引用次数: 18 - 相关文章

2009年12月18日 - We present real-time 3D-TEE imaging in a patient with mechanical mitral .... Prevalence of pannus formation after aortic valve replacement: ...

### Diagnosis of the prosthetic heart valve pannus formation ...

[www.researchgate.net/.../40730370\\_Diagnosis\\_of\\_the\\_prosth...](http://www.researchgate.net/.../40730370_Diagnosis_of_the_prosth...) - 翻译此页

作者: M Ozkan - 2009 - 被引用次数: 18 - 相关文章

Diagnosis of the prosthetic heart valve pannus formation with real-time ... We present real-time 3D-TEE imaging in a patient with mechanical mitral PHVO, clearly ...

### Limitations of multimodality imaging in the diagnosis of ...

[www.ncbi.nlm.nih.gov/.../Literature/PubMedCentral\(PMC\)](http://www.ncbi.nlm.nih.gov/.../Literature/PubMedCentral(PMC)) - 翻译此页

作者: JB Soumoulou - 2015 - 相关文章

2015年4月26日 - This diagnosis should be considered in patients with high ... We present a case of pannus formation in a prosthetic aortic valve and a review of ...





网页 图片 新闻 视频 更多 ▾ 搜索工具

找到约 20,400 条结果 (用时 0.59 秒)

## Google 学术: Imaging of pannus formation in patients with mechanical heart valves

... pannus formation in obstructed mechanical prosthetic ... - Barbetseas - 被引用次数: 187

... Imaging Committee, Cardiac Imaging Committee of the ... - Zoghbi - 被引用次数: 390

... of prosthetic heart valves: diagnosis and therapeutic ... - Roudaut - 被引用次数: 128

### Diagnosis of the prosthetic heart valve pannus formation ...

[ehjci.oxfordjournals.org/content/11/4/E17](http://ehjci.oxfordjournals.org/content/11/4/E17) ▾ 翻译此页

作者: M Özkan - 2010 - 被引用次数: 18 - 相关文章

2009年12月18日 - We present real-time 3D-TEE imaging in a patient with mechanical mitral .... Prevalence of pannus formation after aortic valve replacement: ...

### Limitations of multimodality imaging in the diagnosis of ...

[www.ncbi.nlm.nih.gov](http://www.ncbi.nlm.nih.gov) > ... > Literature > PubMed Central (PMC) - 翻译此页

作者: JB Soumoulou - 2015 - 相关文章

2015年4月26日 - This diagnosis should be considered in patients with high ... We present a case of pannus formation in a prosthetic aortic valve and a review of ...

### Diagnosis of the prosthetic heart valve pannus formation ...

[www.ncbi.nlm.nih.gov/pubmed/20022870](http://www.ncbi.nlm.nih.gov/pubmed/20022870) ▾ 翻译此页

作者: M Ozkan - 2010 - 被引用次数: 18 - 相关文章

2009年12月17日 - Diagnosis of the prosthetic heart valve pannus formation with ... We present real-time 3D-TEE imaging in a patient with mechanical mitral PHVO ...