

Name of journal: World Journal of Cardiology

ESPS Manuscript NO: 17443

Columns: Case Report

Giant and thrombosed left ventricular aneurysm

³ Jose Alberto de Agustin, Jose Juan Gomez de Diego, Pedro Marcos-Alberca, Jose Luis Rodrigo, Carlos Almeria, Patricia Mahia, ³ Maria Luaces, Miguel Angel Garcia-Fernandez, Carlos Macaya, Leopoldo Perez de Isla

¹ Abstract

Left ventricular aneurysms are a frequent complication of acute extensive myocardial infarction and are most commonly located at the ventricular apex. A timely diagnosis is vital due to the serious complications that can occur, including heart failure, thromboembolism, or tachyarrhythmias. We report the case ² of a 78-year-old male with history of previous anterior myocardial

Match Overview

1	Internet 39 words crawled on 28-May-2014 www.cardiothoracicsurgery.org	5%
2	CrossCheck 31 words J. Sindermann. "German Disease Management Guidelines: ... urgical Therapies for Chronic Heart Failure", The Thoracic a	4%
3	Internet 29 words crawled on 18-Nov-2014 www.pubfacts.com	4%
4	CrossCheck 19 words Castelvecchio, S., and L. Menicanti. "Left ventricular recons... uction: update to left ventricular aneurysm/reshaping techni	3%
5	Internet 8 words crawled on 28-Dec-2010 lib.bioinfo.pl	1%

网页 图片 视频 新闻 更多 ▾ 搜索工具

找到约 2,490,000 条结果 (用时 0.64 秒)

Google 学术: Giant and thrombosed left ventricular aneurysm

... treatment for a giant recanalized ophthalmic aneurysm - Velat - 被引用次数: 34

Thrombosed growing giant aneurysms of the vertebral ... - Nagahiro - 被引用次数: 92

Giant intracranial aneurysms: development, clinical ... - Choi - 被引用次数: 93

Calcified left ventricular aneurysm with a giant mural ...

www.ncbi.nlm.nih.gov/pubmed/19478110 - 翻译此页

作者: O Uz - 2009 - 被引用次数: 2 - 相关文章

Heart. 2009 Jun;95(12):993. doi: 10.1136/hrt.2009.166181. Calcified left ventricular aneurysm with a giant mural thrombus. Uz O(1), Kardesoglu E, Yalcin M, ...

Calcified left ventricular aneurysm with delayed thrombus ...

www.ncbi.nlm.nih.gov > ... > PubMed Central (PMC) ▾ 翻译此页

作者: P Robles - 2007 - 被引用次数: 2 - 相关文章

Calcified left ventricular aneurysm with delayed thrombus formation ... Left ventricular thrombus formation may occur in the early course after acute myocardial infarction. ... Calcified left ventricular aneurysm with a giant mural thrombus.[Heart.

Giant left ventricular thrombus after radiofrequency ablation ...

www.ncbi.nlm.nih.gov > ... > PubMed Central (PMC) ▾ 翻译此页

作者: J Benezet-Mazuecos - 2005 - 相关文章

[网页](#)[图片](#)[视频](#)[新闻](#)[更多 ▾](#)[搜索工具](#)

找到约 2,400,000 条结果 (用时 0.60 秒)

Calcified left ventricular aneurysm with delayed thrombus ...

www.ncbi.nlm.nih.gov > ... > [PubMed Central \(PMC\)](#) ▾ [翻译此页](#)

作者: P Robles - 2007 - 被引用次数: 2 - [相关文章](#)

Calcified left ventricular aneurysm with delayed thrombus formation ... Left ventricular thrombus formation may occur in the early course after acute myocardial infarction. ...

Calcified left ventricular aneurysm with a giant mural thrombus.[Heart.

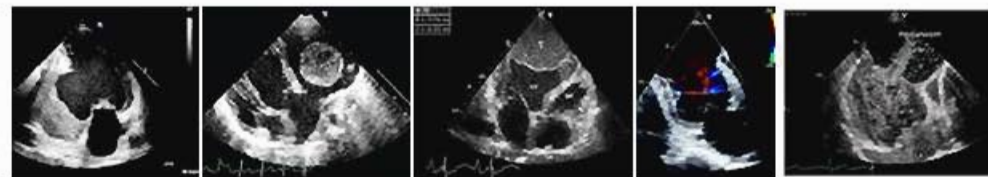
Giant left ventricular thrombus after radiofrequency ablation ...

www.ncbi.nlm.nih.gov > ... > [PubMed Central \(PMC\)](#) ▾ [翻译此页](#)

作者: J Benezet-Mazuecos - 2005 - [相关文章](#)

A left ventricular (LV) thrombus may develop as a complication of acute myocardial infarction, ventricular aneurysm, dilated cardiomyopathy, tako-tsubo transient ...

[Giant and thrombosed left ventricular ...](#) 的图片搜索结果 [举报图片](#)



有关“Giant and thrombosed left ventricular aneurysm”的更多图片