

검색결과 약 17,600개 (0.64초)

Symptomatic chronic long head of biceps rupture: Surgical ...

<https://www.ncbi.nlm.nih.gov/articles/PMC3590700>  이 페이지 번역하기

CY Ng 저술 - 2012 - 15회 인용 - [관련 학술자료](#)

Chronic **rupture** of the **long head** of **biceps** (LHB) **tendon** is usually asymptomatic. ... We performed a retrospective **review** of 11 consecutive **patients** who underwent ... of rotator cuff disease and several **cases** have been reported in **young** athletes. ... In these **cases** a scarred **musculotendinous junction** was found with no ...

[Abstract](#) · [INTRODUCTION](#) · [MATERIALS AND METHODS](#) · [DISCUSSION](#)

관련 질문

What is the Musculotendinous Junction?



What is subluxation of biceps tendon?



How do you fix a bicep tendon subluxation?



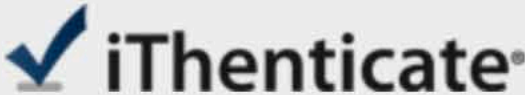
What is the long head biceps tendon?



사용자 의견

Spontaneous biceps tendon rupture in a patient with mixed ...

<https://www.ncbi.nlm.nih.gov/articles/PMC4400687>  이 페이지 번역하기



Name of Journal: *World Journal of Orthopedics*

Manuscript NO: 51090

Manuscript Type: CASE REPORT

Rupture of the long head of the biceps brachii tendon near the musculotendinous junction in a young patient: A case report

Liu X *et al.* Long head biceps tenodesis

Xuan Liu, Andrew Hwee Chye Tan

Abstract

We report an unusual case of the long head of the biceps brachii tendon rupture near the musculotendinous junction in a young patient. The injury occurred in a young athlete during sports competition. The clinical presentation, surgical treatment, and technique with tenodesis using a unicortical button of the ruptured tendon were presented. The post-surgical recovery was uneventful, and the patient returned to sports in 6 mo. The treatment approach and surgical technique of the long head of biceps brachii rupture was reviewed and discussed. In conclusion, surgical treatment of the long head of the biceps brachii tendon rupture with unicortical button tenodesis resulted in a favorable outcome in a young athlete.

Match Overview

1	Crossref 48 words Joseph P. DeAngelis, Alvin Chen, Michael Wexler, Benjamin Hertz, Leandro Grimaldi Bournissaint, Ara Nazarian, Arun J.	2%
2	Crossref 44 words Florian Elser, Sepp Braun, Christopher B. Dewing, J. Erik Giphart, Peter J. Millett. "Anatomy, Function, Injuries, and Trea	2%
3	Crossref 13 words William F. Scully, David J. Wilson, Jason A. Grassbaugh, Joanna G. Branstetter, Bryant G. Marchant, Edward D. Arringt	1%
4	Crossref 13 words Mario Tangari, Stefano Carbone, Mimmo Gallo, Andrea Campi. "Long head of the biceps tendon rupture in professio ...	1%



All

Images

Videos

关闭取词

11,800 Results

Any time ▾

Symptomatic chronic long head of biceps rupture: Surgical ...

<https://www.ncbi.nlm.nih.gov/pmc/articles/PMC3590700>

Rupture of the long head of biceps (LHB) tendon most frequently occurs secondary to degenerative changes within the tendon and is associated with underlying rotator cuff tendinopathy.[1-3] A cadaveric study has shown concentration of degenerative changes within the tendon at the distal bicipital groove, which could explain the predilection for tendon rupture at that site.

Case Report of a Bifid Distal Biceps Tendon with Traumatic ...

<https://www.thefreelibrary.com/Case+Report+of+a+Bifid+Distal+Biceps+Tendon+with...> ▾

Evaluation of the distal biceps revealed a bifid tendon with separate origins at the biceps brachii at the musculotendinous junction extending distally with a common sheath for the two tendons. The posterior musculotendinous unit (long head) inserting on the proximal ulnar aspect of the radial tuberosity was noted to be intact.

Rupture of a bifurcated distal biceps tendon: A case ...

https://www.researchgate.net/publication/8136889_Rupture_of_a_bifurcated_distal_biceps...

In the specimens with a bifurcated distal biceps tendon, the long head of the tendon inserted at the posterosuperior portion of the radial tuberosity, and the average area was $71.4 \text{ mm}^2 \pm 11.3$...

Spontaneous biceps tendon rupture in a patient with mixed ...

<https://www.ncbi.nlm.nih.gov/pmc/articles/PMC4400687>

Dec 31, 2013 - Summary. Tendon rupture is a rare complication that occurs in patients receiving corticosteroid therapy. We report a case of a middle-aged man with mixed connective tissue disease who presented with spontaneous biceps tendon rupture 5 weeks after initiation of high-dose corticosteroid therapy.

Author: Ong Sg Publish Year: 2013

Injury of the distal biceps at the musculotendinous junction

<https://www.sciencedirect.com/science/article/pii/S1058274606002023>

In conclusion, although complete rupture of the tendinous insertion of the distal biceps brachii remains a more common injury, musculotendinous junction injuries do occur. The key to diagnosis of these injuries is the mechanism of injury, as well as the position of the upper extremity at the time of injury.

Cited by: 31

Author: Mark L. Schamblin, Marc R. Safran