

Name of Journal: *World Journal of Clinical Pediatrics*

Manuscript NO: 54261

Manuscript Type: CASE REPORT

Acute lymphoblastic leukemia in a β -thalassemia intermedia child: A case report

Sherief LM *et al.* ALL in a child with β TI

Laila M Sherief, Esmael Goneim, Naglaa M Kamal, Amr Ibraheim, Fuad Alsofiani, Abdulraouf Alawur

Abstract

BACKGROUND

β -thalassemia intermedia (β TI) is one of the hemoglobinopathies. It constitutes 10% of β -thalassemia cases yet being associated with a better quality of life than β -thalassemia major (β TM).

CASE SUMMARY

We recently reported the first case of acute lymphoblastic leukemia (ALL) from Egypt in a child with β TM, and we herein report the first case of ALL from Egypt in a child with β TI. In this report, literature was reviewed for cases of malignancies associated with β TI and the possible factors underling

Match Overview

1	Crossref 54 words Laila M. Sherief, Naglaa M. Kamal, Hadeel M. Abdelrahman, Besheir Abdalla Hassan, Marwa M. Zakaria. "First Report ...	3%
2	Crossref 48 words Racha Halawi, Maria D. Cappellini, Ali Taher. "A higher prevalence of hematologic malignancies in patients with thalas...	3%
3	Internet 45 words crawled on 17-Apr-2020 www.elsevier.es	2%
4	Internet 32 words crawled on 07-Feb-2017 www.oalib.com	2%
5	Crossref 28 words Mehran Karimi. "Malignancies in patients with β -thalassemia... a major and β -thalassemia intermedia: A multicenter study i	2%
6	Internet 16 words crawled on 11-Dec-2014 www.ncbi.nlm.nih.gov	1%



ACUTE LYMPHOBLASTIC LEUKEMIA IN A B-THALASSEMI



Sign in

ALL IMAGES VIDEOS

11,400 Results Any time

Thalassemia Intermedia and Acute Lymphoblastic Leukemia ...

<https://www.ncbi.nlm.nih.gov/pmc/articles/PMC4287036>

Sep 05, 2014 · Beta-gene analysis revealed homozygote IVS-I-6 (T-C) mutation, pointing to thalassemia **intermedia** . Chemotherapy was started according to the Children's Cancer Group. He achieved remission at the end of the phase 1. The coexistence of thalassemia with cancers such as Hodgkin disease, lymphoma, seminoma, and **leukemia** has been reported [3,4,5,6 ...

Cited by: 1 Author: Deniz Tuğcu, Zeynep Karakaş, Müge Gökçe...

Publish Year: 2014

Thalassemia Intermedia and Acute Lymphoblastic Leukemia ...

europepmc.org/articles/PMC4287036

Sep 01, 2014 · Thalassemia **Intermedia** and **Acute Lymphoblastic Leukemia**: Is it a Coincidental Double Diagnosis? Talasemi **İntermedia** ve Akut Lenfoblastik Lösemi Rastlantısal Çift Tanı mı? Deniz Tuğcu , 1, * Zeynep Karakaş , 2 Müge Gökçe , 1 Leyla Ağaoğlu , 2 Ayşegül Ünüvar , 2 Ebru Sarıbeyoğlu , 2 Arzu Akçay , 1 and Ömer Devecioğlu 2

Cited by: 1 Author: Deniz Tuğcu, Zeynep Karakaş, Müge Gökçe...

Publish Year: 2014

B-Cell Acute Lymphoblastic Leukemia for Adults: Symptoms ...

<https://www.webmd.com/cancer/lymphoma/b-cell-acute...>

WebMD explains the causes, symptoms, and treatment of B-cell **acute lymphoblastic leukemia**, a cancer that affects your "B lymphocytes" – white blood cells that grow in the soft center of your ...

Thalassemia Intermedia and Acute Lymphoblastic Leukemia ...

<https://www.researchgate.net/publication/267102978...>

Moreover, a **case report** from Turkey in 2014 described the **case** of a 12-year old boy known to have thalassemia since the age of 5 years, presenting with headache, pallor, abdominal distension and ...

[PDF] Thalassemia Intermedia and Acute Lymphoblastic Leukemia ...

<https://www.researchgate.net/profile/Zeynep...>

312 Turk J Hematol 2014;31:311-312 Tuğcu D, et al: Thalassemia **Intermedia** and **Acute Lymphoblastic Leukemia** Whether the above theories hold true or not, one should suspect the possibility of ...

First Report of Acute Lymphoblastic Leukemia in an ...

<https://www.researchgate.net/publication/272753494...>

We use cookies to make interactions with our website easy and meaningful, to better understand the use of our services, and to tailor advertising.

1 2 3 4 5 >

Add the Give with Bing extension >



Support nonprofits responding to COVID-19 when you search on Bing

MAYBE LATER

YES

Acute lymphoblastic leukemia in a β -thalassemia intermedia ch

ALL

IMAGES

VIDEOS

19,900 Results

Any time ▾

[Thalassemia Intermedia and Acute Lymphoblastic Leukemia ...](#)

<https://www.ncbi.nlm.nih.gov/pmc/articles/PMC4287036>

Sep 05, 2014 · '**Thalassemia intermedia**' describes the patients whose **clinical phenotype** is placed between **thalassemia major** and the **thalassemia trait** despite having **homozygote beta-gene mutation**. These patients are generally identified with mild-to-moderate **anemia** later in life than the patients with **thalassemia major** .

Cited by: 1**Author:** Deniz Tuğcu, Zeynep Karakaş, Müge G...**Publish Year:** 2014

[PDF] [T- ACUTE LYMPHOBLASTIC LEUKEMIA IN AN ADOLESCENT ...](#)

cibtech.org/J-Medical-Case-Reports/PUBLICATIONS/2019/VOL-8-No-1/JCR-003-MAR-BISHT...

association of leukemia is rare. The case study of an **adolescent boy** with **HbE thalassemia homozygous diagnosed** with **T- Acute lymphoblastic leukemia** at his **adolescence** is presented here due to the rarity and diagnostic importance of the case. Keywords: **Thalassemia, Leukemia**, Malignancy INTRODUCTION

[Thalassemia Intermedia and Acute Lymphoblastic Leukemia ...](#)

https://www.researchgate.net/publication/267102978_Thalassemia_Intermedia_and_Acute...

Here we present a **case** of a two-year-old male **child** co-presenting with pre B **acute lymphoblastic** leukaemia (ALL) with MLL rearrangement and HbE alpha thalassaemia.

[First Report of Acute Lymphoblastic Leukemia in an ...](#)

https://www.researchgate.net/publication/272753494_First_Report_of_Acute_Lymphoblastic...

Request PDF | First Report of **Acute Lymphoblastic Leukemia in an Egyptian Child** with **β -Thalassemia Major** | **β -Thalassemia (β -thal)** is the most common **hereditary anemia** in humans.



Acute lymphoblastic leukemia in a β -thalassemia interme



ALL

IMAGES

VIDEOS

MAPS

NEWS

SHOPPING

20,000 Results

Any time ▾

Thalassemia Intermedia and Acute Lymphoblastic Leukemia ...

<https://www.ncbi.nlm.nih.gov/pmc/articles/PMC4287036>

Sep 05, 2014 · '**Thalassemia intermedia**' describes the patients whose **clinical phenotype** is placed between **thalassemia major** and the **thalassemia trait** despite having **homozygote beta-gene mutation**. These patients are generally identified with mild-to-moderate **anemia** later in life than the patients with **thalassemia major**.

Cited by: 1

Author: Deniz Tuğcu, Zeynep Karakaş, Müge Gö...

Publish Year: 2014

Thalassemia Intermedia and Acute Lymphoblastic Leukemia ...

<https://www.researchgate.net/publication/267102978...>

Here we present a **case** of a two-year-old male **child** co-presenting with pre B **acute lymphoblastic leukaemia** (ALL) with MLL rearrangement and HbE alpha thalassaemia.

First Report of Acute Lymphoblastic Leukemia in an ...

<https://www.researchgate.net/publication/272753494...>

Request PDF | First Report of **Acute Lymphoblastic Leukemia in an Egyptian Child** with **β -Thalassemia Major** | **β -Thalassemia (β -thal)** is the most common **hereditary anemia** in humans.

[PDF] A strategy for the clinical remission of acute ...

<https://www.spandidos-publications.com/10.3892/mco.2017.1533/download>

Acute lymphoblastic leukemia (ALL) has been suggested as a **long-term complication** in patients with **β -thalassemia major (β TM)**. A 12monthsold male patient was diagnosed with **β -TM**. The patient required a blood trans - fusion weekly for 2 years. At the age of 4 years, a **splenectomy** was performed due to massive splenomegaly and frequent

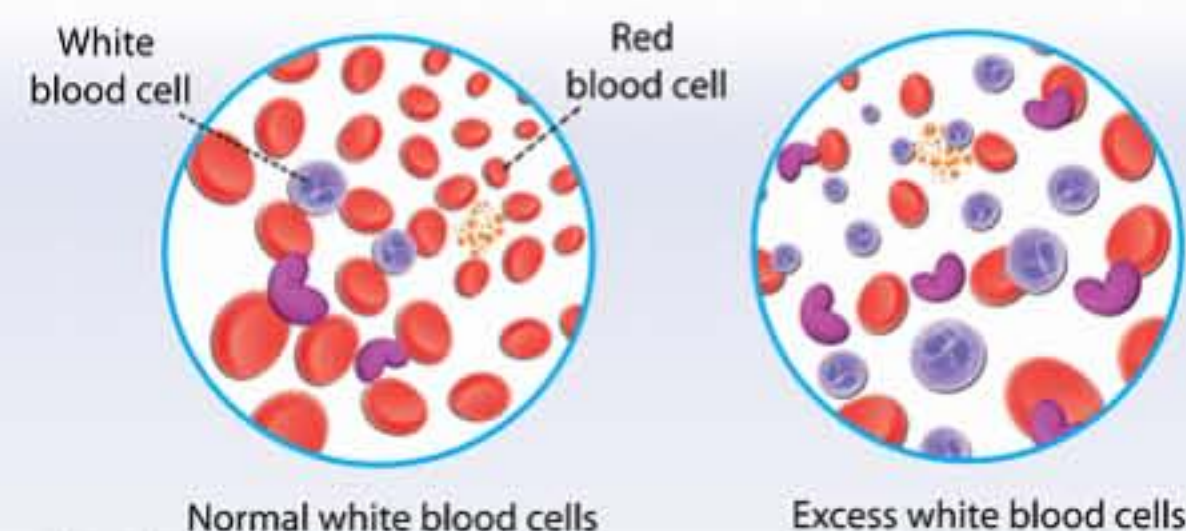
[PDF] Thalassemia Intermedia and Acute Lymphoblastic Leukemia ...

<https://www.researchgate.net/profile/Zeynep-Karakaş/publication/267102978/links/5470100008ae44c730900000/Thalassemia-intermedia-and-child%3a-A-case-report&FORM=HDRSC3>

Acute Lymphoblastic Leukemia

Medical Condition

Condition where the number of white blood cells are abnormally high



A type of blood and bone marrow cancer which mainly affects the white blood cells.

🏠 Very rare (Fewer than 20,000 cases per year in US)

🧪 Requires lab test or imaging

👨🏻‍⚕️ Treatment from medical professional advised

🕒 Can last several months or years

Occurs due to gene defects in the bone marrow leading to the development of a large number of immature lymphocytes. Major symptoms include bruising, fever, and bone pain. Treatment involves chemotherapy and bone marrow transplantation.