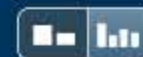

## Match Overview



- 1** **Crossref** 15 words  
"Posters", Journal of the European Academy of Dermatology and Venereology, 11/2004 1%
- 2** **Crossref** 12 words  
Oâ€™Keefe, Stephen J., Ihab I. El Hajj, Tong Wu, Dolly Martin, Khaled Mohammed, and Kareem Abu-Elmagd. "Endosco..." 1%
- 3** **Crossref** 9 words  
Bathla, Lokesh, and Alan Langnas. "Intestinal and Multivisceral Transplantation", Transplantation of the Liver, 2015. <1%

Name of Journal: *World Journal of Transplantation*

ESPS Manuscript NO: 31588


Manuscript Type: Case Report

**Mycophenolate Mofetil toxicity mimicking acute cellular rejection in a small intestinal transplant**

**Ross Apostolov, Khashayar Asadi, Julie Lokan, Ning Kam, Adam Testro**

### Abstract

Mycophenolate Mofetil (MMF) is an important medication used for maintenance immunosuppression in solid organ transplants. A common gastrointestinal (GI) side effect of MMF is enterocolitis, which has been associated with multiple histological features. There is little data in the literature describing the histological effects of mycophenolate mofetil in small intestinal transplant (SIT) recipients. We present a



[全部](#)[图片](#)[新闻](#)[视频](#)[购物](#)[更多 ▾](#)[搜索工具](#)

找到约 24,000 条结果 (用时 0.94 秒)

## Google 学术: Mycophenolate Mofetil toxicity mimicking acute cellular rejection in a small intestinal transplant

... biopsies in patients treated with mycophenolate mofetil - Selbst - 被引用次数: 75

The use of mycophenolate mofetil (RS-61443) in ... - ENsLEY - 被引用次数: 125

Therapy with mycophenolate mofetil for refractory acute ... - Furlong - 被引用次数: 57

### Modern Pathology - Spectrum of histologic changes in colonic ... - Nature

[www.nature.com](http://www.nature.com) > [Journal home](#) > [Archive](#) > [Original Articles](#) ▾ [翻译此页](#)

作者: MK Selbst - 2009 - 被引用次数: 75 - [相关文章](#)

2009年3月27日 - The histologic changes in patients receiving mycophenolate mofetil were ... decrease in the incidence of acute allograft rejection in solid organ transplant patients. ... mofetil-associated drug toxicity have been reported to mimic ... is highest following small bowel transplant (about 5%) possibly due to a large ...

### Mycophenolate Mofetil-Related Enterocolitis and Weight Loss: A ...

[www.ncbi.nlm.nih.gov](http://www.ncbi.nlm.nih.gov) > [NCBI](#) > [Literature](#) > [PubMed Central \(PMC\)](#) - [翻译此页](#)

2012年10月23日 - Mycophenolate mofetil (MMF) is an immunosuppressive medication ... States to prevent rejection in solid organ transplant recipients and to ... findings which may mimic infection, acute graft-versus-host disease, or Crohn's enterocolitis and are characterized by crypt cell apoptosis and small bowel villous ...

### Gastrointestinal Complications of Transplant Immunosuppression

[jasn.asnjournals.org/content/13/1/277.short](http://jasn.asnjournals.org/content/13/1/277.short) - [翻译此页](#)

作者: JH Helderma - 2002 - 被引用次数: 120 - [相关文章](#)

2002年1月1日 - CMV infection can also mimic many other entities such as ischemic colitis, ... these patients had evidence of CMV infection in the small intestine or gastric mucosa. ... All cases developed



[全部](#)[图片](#)[新闻](#)[视频](#)[购物](#)[更多](#)[设置](#)[工具](#)

找到约 27,400 条结果 (用时 0.65 秒)

## Google 学术: Mycophenolate Mofetil toxicity mimicking acute cellular rejection in a small intestinal transplant

... biopsies in patients treated with mycophenolate mofetil - Selbst - 被引用次数: 75

The use of mycophenolate mofetil (RS-61443) in ... - ENsLEY - 被引用次数: 125

Therapy with mycophenolate mofetil for refractory acute ... - Furlong - 被引用次数: 58

## Modern Pathology - Spectrum of histologic changes in colonic ... - Nature

[www.nature.com](http://www.nature.com) > Journal home > Archive > Original Articles - 翻译此页

作者: MK Selbst - 2009 - 被引用次数: 74 - 相关文章

2009年3月27日 - The histologic changes in patients receiving mycophenolate mofetil were ... decrease in the incidence of acute allograft rejection in solid organ transplant patients. ... mofetil-associated drug toxicity have been reported to mimic ... is highest following small bowel transplant (about 5%) possibly due to a large ...

## Mycophenolate Mofetil-Related Enterocolitis and Weight Loss: A ...

<https://www.hindawi.com/journals/cripe/2012/624168/> - 翻译此页

作者: DMH Dykes - 2012 - 被引用次数: 2 - 相关文章

2012年9月6日 - Mycophenolate mofetil (MMF) is an immunosuppressive medication utilized in ... to bone marrow and gastrointestinal toxicity, typically diarrhea [3]. ... and are characterized by crypt cell apoptosis and small bowel villous atrophy [4]. ... was admitted with acute renal allograft rejection, nonbloody diarrhea for ...

## Endoscopic and histological features of mycophenolate mofetil colitis ...

<https://www.ncbi.nlm.nih.gov> > NCBI > Literature > PubMed Central (PMC) - 翻译此页

[全部](#)[图片](#)[新闻](#)[视频](#)[购物](#)[更多](#)[设置](#)[工具](#)

找到约 30,000 条结果 (用时 0.62 秒)

## Google 学术: Mycophenolate mofetil toxicity mimicking acute cellular rejection in a small intestinal transplant

... biopsies in patients treated with mycophenolate mofetil - Selbst - 被引用次数: 76

The use of mycophenolate mofetil (RS-61443) in ... - ENsLEY - 被引用次数: 125

Therapy with mycophenolate mofetil for refractory acute ... - Furlong - 被引用次数: 60

## Modern Pathology - Spectrum of histologic changes in colonic ... - Nature

[www.nature.com](http://www.nature.com) > [Journal home](#) > [Archive](#) > [Original Articles](#) ▾ [翻译此页](#)

作者: MK Selbst - 2009 - 被引用次数: 76 - 相关文章

2009年3月27日 - The histologic changes in patients receiving mycophenolate mofetil were ... in the incidence of acute allograft rejection in solid organ transplant patients. ... mofetil-associated drug toxicity have been reported to mimic graft-vs-host disease, inflammatory bowel disease, ischemia or acute self-limited colitis in ...

## Mycophenolate Mofetil-Related Enterocolitis and Weight Loss: A ...

<https://www.hindawi.com/journals/cripe/2012/624168/> - [翻译此页](#)

作者: DMH Dykes - 2012 - 被引用次数: 2 - 相关文章

2012年9月6日 - Mycophenolate mofetil (MMF) is an immunosuppressive medication utilized in ... to bone marrow and gastrointestinal toxicity, typically diarrhea [3]. ... and are characterized by crypt cell apoptosis and small bowel villous atrophy [4]. ... was admitted with acute renal allograft rejection, nonbloody diarrhea for ...

## Endoscopic and histological features of mycophenolate mofetil colitis ...

<https://www.ncbi.nlm.nih.gov> > [NCBI](#) > [Literature](#) > [PubMed Central \(PMC\)](#) - [翻译此页](#)

作者: ... - 2015 - 被引用次数: 5 - 相关文章