



## Crohn's disease in human immunodeficiency virus-infected patient: A case report

Ausra Vinikaite, Benediktas Kurlinkus, Dominyka Jasinskaite, Sandra Strainiene, Audrone Buineviciute, Goda Sadauskaite, Vytautas Kiudelis, Edita Kazenaite

**Specialty type:** Medicine, research and experimental

**Provenance and peer review:** Unsolicited article; Externally peer reviewed.

**Peer-review model:** Single blind

**Peer-review report's scientific quality classification**

Grade A (Excellent): 0  
Grade B (Very good): 0  
Grade C (Good): C, C  
Grade D (Fair): 0  
Grade E (Poor): 0

**P-Reviewer:** Duan SL, China; Wen XL, China

**Received:** April 22, 2023

**Peer-review started:** April 22, 2023

**First decision:** April 26, 2023

**Revised:** May 4, 2023

**Accepted:** May 12, 2023

**Article in press:** May 12, 2023

**Published online:** June 16, 2023



**Ausra Vinikaite, Dominyka Jasinskaite,** Lithuanian University of Health Sciences, Faculty of Medicine, Kaunas 44307, Lithuania

**Benediktas Kurlinkus, Audrone Buineviciute, Goda Sadauskaite, Edita Kazenaite,** Clinic of Gastroenterology, Nephrourology and Surgery, Institute of Clinical Medicine, Faculty of Medicine, Vilnius University, Vilnius 01513, Lithuania

**Benediktas Kurlinkus, Audrone Buineviciute, Goda Sadauskaite, Edita Kazenaite,** Center of Hepatology, Gastroenterology and Dietology, Vilnius University Hospital Santaros Clinics, Vilnius 08661, Lithuania

**Sandra Strainiene,** Department of Internal Medicine and Surgery, Antakalnis Clinic, Vilnius 10207, Lithuania

**Vytautas Kiudelis,** Department of Gastroenterology, Lithuanian University of Health Sciences, Kaunas 44307, Lithuania

**Corresponding author:** Sandra Strainiene, MD, Lecturer, Department of Internal Medicine and Surgery, Antakalnis Clinic, Antakalnis Str. 59, Vilnius 10207, Lithuania.  
[sandra.strainiene@gmail.com](mailto:sandra.strainiene@gmail.com)

### Abstract

#### BACKGROUND

Inflammatory bowel disease (IBD) is an autoimmune condition treated with immunosuppressive drugs. However, the need for immune system suppression becomes questionable when infection with the human immunodeficiency virus (HIV) occurs simultaneously and impacts the course of IBD. Our reported case represents the clinical course, prescribed treatment and its effect, as well as clinical challenges faced by physicians in a combination of such diseases. We also present a comprehensive literature review of similar cases.

#### CASE SUMMARY

A 49-year-old woman suffering from a newly diagnosed Crohn's disease was hospitalized due to exacerbated symptoms (abdominal pain, fever, and weight loss). During her hospital stay, she tested positive for HIV. With conservative treatment, the patient improved and was discharged. In the outpatient clinic, her HIV infection was confirmed as stage C3, and antiretroviral treatment was initiated immediately. That notwithstanding, soon the patient was rehospitalized

with pulmonary embolism and developed a series of complications because of the subsequent coexistence of IBD and HIV. After intensive and meticulous treatment, the patient's condition has improved and she remains in remission.

### CONCLUSION

The paucity of studies and data on the coexistence of HIV and IBD leaves clinicians doubting the optimal treatment options.

**Key Words:** Crohn's disease; Inflammatory bowel disease; Human immunodeficiency virus; Immuno-compromised patient; Case report

©The Author(s) 2023. Published by Baishideng Publishing Group Inc. All rights reserved.

**Core Tip:** We present the case of a middle-aged female with Crohn's disease and concomitant human immunodeficiency virus (HIV) infection to improve knowledge of the rare and understudied interrelation of these two conditions. The paucity of studies and data on HIV and inflammatory bowel disease coinfection leaves clinicians doubting the optimal treatment options. This report reminds experts of the importance of early diagnostics and discusses the specific treatment and prophylactic guidelines when both diseases are present to prevent a variety of complications.

**Citation:** Vinikaite A, Kurlinkus B, Jasinskaite D, Strainiene S, Buineviciute A, Sadauskaite G, Kiudelis V, Kazenaite E. Crohn's disease in human immunodeficiency virus-infected patient: A case report. *World J Clin Cases* 2023; 11(17): 4202-4209

**URL:** <https://www.wjgnet.com/2307-8960/full/v11/i17/4202.htm>

**DOI:** <https://dx.doi.org/10.12998/wjcc.v11.i17.4202>

## INTRODUCTION

Human immunodeficiency virus (HIV) is a double-strand RNA retrovirus transmitted through direct blood contact that puts the body in a state of immunodeficiency. Meanwhile, autoimmune inflammatory bowel disease (IBD) is an idiopathic chronic relapsing disease of the gastrointestinal tract (GI) that is often treated with immunosuppressive drugs. It is classified as either ulcerative colitis (UC) or Crohn's disease (CD). Both IBD and HIV infection can coexist in the same person, although this coexistence is rarely observed; therefore, the relationship between one and the other and the impact of this relationship on the immune system are not fully understood yet[1,2]. However, there are speculations that the HIV-modified CD4<sup>+</sup> lymphocyte count plays its role in altering the course of IBD alongside increasing the likelihood of opportunistic infections occurring[2,3].

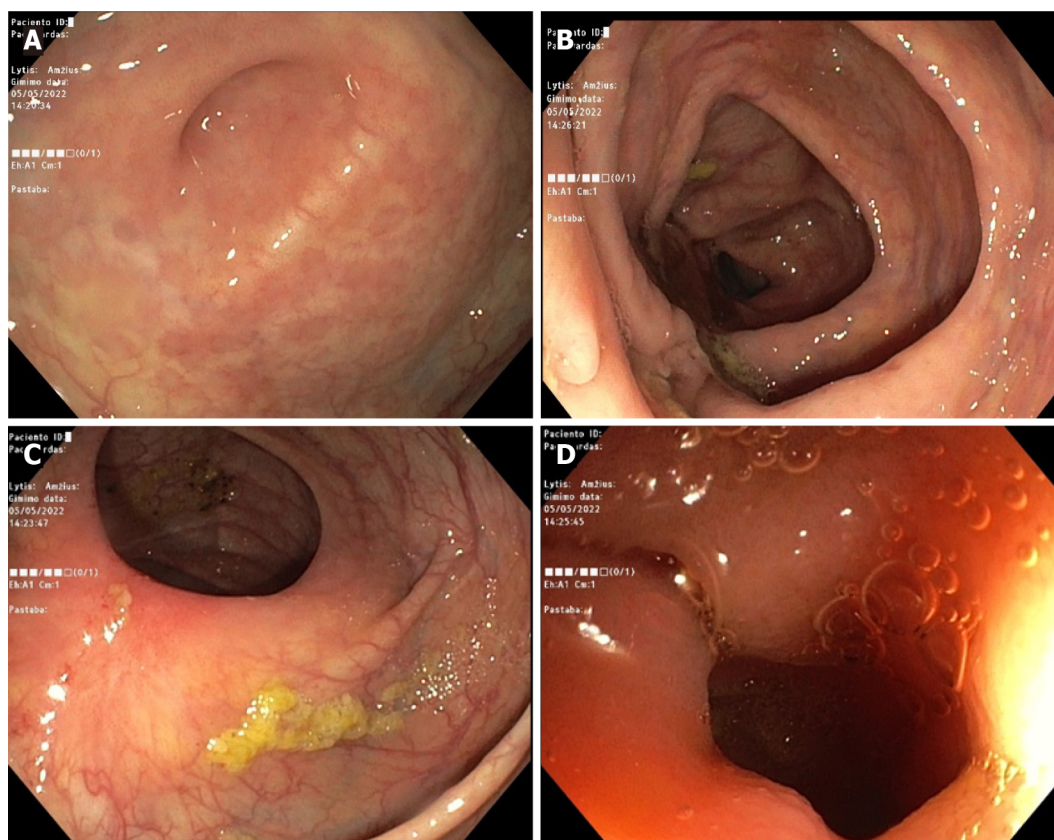
## CASE PRESENTATION

### Chief complaints

The middle-aged patient was admitted to the Hepatology and Gastroenterology Department of Vilnius University Hospital Santaros Clinics in August 2022 with the following presenting complaints: Abdominal pain, diarrhea, high-grade fever (temperatures of up to 39 °C), and severe weight loss (25 kg over six months).

### History of present illness

The mentioned abdominal pain, fever, and diarrhea started back in October 2021. However, the woman only sought medical attention in April of the following year when she consulted a gastroenterologist in an outpatient clinic. After running multiple diagnostic tests (such as blood analysis, upper GI endoscopy, colonoscopy, histology, and magnetic resonance imaging enterography) the diagnosis was finally confirmed by the end of May of that year, and it was CD with an inflamed transverse and descending colon (Figure 1). Subsequently, she was prescribed the following daily medication: Mesalazine 1000 mg × 2, azathioprine 50 mg × 2, prednisolone 15 mg × 2 with a steady dosage decrease until it was substituted with budesonide 3 mg × 3. Additionally, the patient was given two courses of ciprofloxacin 500 mg × 2 for 10 d overall. Although diarrhea subsided to watery defecation 1-2 times per day, the abdominal pain, fever, and persistent weight loss persisted. The patient was referred to the inpatient clinic for the preparation of the expected biological therapy.



DOI: 10.12998/wjcc.v11.i17.4202 Copyright ©The Author(s) 2023.

**Figure 1** Colonoscopy images. A: Valve of Baughini; B: The transverse colon with inflammation and ulcerations; C: The inflamed descending colon; D: The rectosigmoid colon.

### History of past illness

In 2018, the woman was diagnosed with a hyperplastic endometrial polyp. Also, the patient was chronically anemic. She had no other illnesses, drug allergies, or addictive habits.

### Personal and family history

The patient works as a cook and is a mother of an adult son and daughter, both of whom are currently healthy. The woman had not had a sexual partner for about a year. However, since her husband's death in 2011, she has had about 5-7 partners, with whom barrier contraceptives had not always been used.

### Physical examination

The patient's condition at admission was moderate. Her vital signs were as follows: Body temperature, 38 °C; blood pressure, 105/80 mmHg; heart rate, 110 beats/min. Her cardiopulmonary examination was normal, her abdomen was bloated and tender, and she had active bowel peristalsis. She had neither liver nor spleen enlargement, and no skin discoloration, rashes, peripheral edema, or lymphadenopathy was observed.

### Laboratory examinations

Before inducing CD remission with more aggressive treatment, several tests were performed to assess her condition and make sure she had not been infected with hepatitis B, hepatitis C, or HIV, and she tested positive for HIV. Inflammatory markers were also taken into account. Some of them are presented in Table 1. Testing for intestinal infections, such as *Clostridioides difficile*, *Shigella*, *Salmonella*, *Campylobacter*, and *Yersinia*, were negative.

### Imaging examinations

This patient with active CD (Montreal classification: A3 L2 B3) under glucocorticoid treatment was newly diagnosed with stage C3 HIV infection.

Table 1 Relevant laboratory results (August)

Timeline	Analyte	Results
August 22, 2022	White blood count ( $\times 10^9/L$ )	3.36
	Neutrophils ( $\times 10^9/L$ )	2.20
	Lymphocytes ( $\times 10^9/L$ )	0.40
	Red blood count ( $\times 10^{12}/L$ )	2.54
	Hemoglobin (g/L)	80
	Platelet count ( $\times 10^9/L$ )	506
	Reactive protein C-reactive protein (mg/L)	5.07
	HIV 1/2 Ag/Ab combo (s/co)	472.53
	HIV 1/2 Ag/Ab combo	Positive
September 26, 2022	Lymphocyte count (%)	13.9
	Lymphocyte count ( $mm^3$ )	391
	CD3 <sup>+</sup> CD4 <sup>+</sup> (T helper/inducers) (%)	48
	CD3 <sup>+</sup> CD4 <sup>+</sup> (T helper/inducers) ( $mm^3$ )	188

Ag: Antigen; Ab: Antibody; CD3 or CD4: Cluster of differentiation 3 or 4; HIV: Human immunodeficiency virus.

## FINAL DIAGNOSIS

This patient with active CD (Montreal classification: A3 L2 B3) under glucocorticoid treatment was newly diagnosed with stage C3 HIV infection.

## TREATMENT

Antiretroviral therapy was started, and CD remission was induced by the daily oral medication prescribed while she was in the hospital and continued after she was discharged (Table 2). The patient was also prescribed 80 mg/d of ferrous sulfate for chronic anemia during her hospitalization and afterward.

## OUTCOME AND FOLLOW-UP

A month after her first hospitalization, the patient started experiencing dyspnea; so, an ambulance was called and she was taken to the hospital where she was hospitalized again in the Department of Infectious Diseases where she complained of shortness of breath lasting for about 1 wk (initially, it only occurred during physical exertion; subsequently, it started occurring when resting), hoarseness of the voice, fever (temperatures of up to 38.5 °C), phalangeal paresthesia of the limb, and general fatigue.

During her prolonged stay in the hospital (from September 25 to October 31), the patient underwent multiple examinations. The patient underwent chest X-ray and computed tomography angiography and was diagnosed with pulmonary embolism (PE), which was later treated with anticoagulant and oxygen therapy. Second, signs of pulmonary infiltration on a chest X-ray raised the suspicion of concomitant infection. Therefore, a variety of tests were performed to differentiate the possible etiological pathogens. Apparently, the cause of her illness was not only *Pneumocystis jirovecii* (*P. jirovecii*) but also Cytomegalovirus (CMV) and Epstein Barr virus (EBV). Immediate treatment with antibiotics was initiated: Trimethoprim + sulfamethoxazole (TMP + SMX) for 18 d in addition to oral corticosteroids for hypoxemia (based on a consensus statement[4]) and antipyretics if necessary. At first, the patient seemed to be getting better. However, oral candidiasis was detected after a few days. Finally, after the antibiotic course was finished, the patient experienced a new fever (temperature of 38 °C) with chills. Her blood and urine cultures were positive for *Escherichia coli* (*E. coli*) and *Enterococcus faecium* (*E. faecium*); thus, she was also diagnosed with urinary tract infection and sepsis. The clinical pharmacologist adjusted her treatment accordingly; therefore, the patient's condition improved, despite a minor episode of conjunctivitis.

**Table 2 Crohn's disease and human immunodeficiency virus treatment (in August)**

<b>Inpatient treatment</b>				
<b>Crohn's disease exacerbation treatment</b>			<b>HIV treatment</b>	
Prednisolone	30 mg × 1	5 mg/wk	Emtricitabine/tenofovir disoproxil	200 mg/245 mg × 1
Metronidazole	500 mg × 3		Dolutegravir	50 mg × 1
Mesalazine	2000 mg × 2			
Azathioprine	50 mg × 2			
<b>Outpatient treatment</b>				
<b>Crohn's disease treatment</b>			<b>HIV treatment</b>	
Prednisolone	Eventually discontinued		Emtricitabine/tenofovir disoproxil	200 mg/245 mg × 1
Mesalazine	2000 mg × 2		Dolutegravir	50 mg × 1
Azathioprine	50 mg × 2			

HIV: Human immunodeficiency virus.

During the hospitalization period, clinicians constantly questioned how to decipher the results of the blood tests. Chronic anemia, progressing leukocytopenia, lymphocytopenia, thrombocytopenia, as well as changes in her blood count were challenging to interpret while keeping in mind the context of autoimmune inflammatory disease (CD), HIV, and immunosuppressive treatment with azathioprine, not to mention that many other infections were also present and were being treated concurrently. Due to the progression of anemia and thrombocytopenia, blood transfusions were performed (erythrocyte mass - 9 units in total, thrombocyte mass - 5 units in total). Meanwhile, to combat neutropenia, a granulocyte colony-stimulating factor (Filgrastim) was added. Intermittent diarrhea also occurred; however, her stool sample analysis revealed no etiological findings; therefore, symptomatic treatment was prescribed.

We have summarized the most relevant follow-up information (Table 3) with chronological examination reports, health status fluctuations, and the additional treatment required to address new-onset health deteriorations. With time, her serum inflammation marker levels diminished steadily, her blood cell count returned to the normal range, and the patient expressed no significant complaints. Moreover, clinically, there were no signs of CD exacerbation, and it was recommended that she refrained from taking azathioprine due to the high associated risk of pancytopenia recurrence. With the significant improvement in the patient's clinical situation, it was decided to discharge her with antiretroviral and anticoagulant treatment. The CD treatment continued with mesalazine, and azathioprine was suspended. Not long after, the patient was referred to an infectologist, gastroenterologist, and general practitioner.

## DISCUSSION

Both CD and HIV have their own specific impact on the immune system. Their pathophysiological interaction is still to be unveiled; however, there are several reasons to think that the clinical symptoms of IBD could be attenuated by the presence of HIV[5]. The authors of a similar case report and the other authors of a comprehensive study mentioned that specifically, CD4<sup>+</sup> cells are responsible for intestinal inflammation, while HIV reduces the CD4<sup>+</sup> count. Moreover, CD relapse rates reduce in the presence of HIV[2,6]. In our case, the patient still suffered from CD symptoms; however, during rehospitalization, the clinical manifestations were not as severe. We hope she will experience fewer relapses in the future. Also, there is a thought-provoking option to combat HIV in patients with IBD using anti-TNF- $\alpha$  drugs as some authors had noticed improvements; unfortunately, others could not state any benefits[7]. Maybe a cure in development, which can potentially treat both diseases, might be of help in the future, as one study shows[8]. New treatment options are truly welcome, as current management approaches remain problematic for many physicians and patients.

Speaking of the observed complications, interestingly, a previous study reported that inflammatory diseases promote coronary heart diseases; however, for HIV and IBD, this only occurs when the illnesses are severe[1]. Our patient had PE, which could also have been caused by the corticosteroids prescribed after her first exacerbation. Based on recent literature, the adverse effects of corticosteroids are more likely in patients with IBD who experience exacerbations and go through the post-hospitalization period without any anti-embolic prophylaxis[9].



Table 3 Case report timeline

Timeline	Remarks	Specific treatment (daily dosage)
September 25, 2022	2 background illnesses: CD and HIV	Background medication: Azathioprine 50 mg × 2 + mesalazine 2000 mg × 2. Dolutegravir 50 mg × 1. Emtricitabine + Tenofovir disoproxil 445 mg × 1
	PE	Oxygen (99.50%) 3 L/min (if SpO <sub>2</sub> is < 95%). Ketorolac trometamol 30 mg (once). Calcium nadroparin 0.6 mL × 2. Amoxicilline + clavulanic acid 1200 mg × 4
September 27, 2022	CMV DNA detected: 420 copies/mL EBV DNA detected: 13640 copies/mL <i>P. jirovecii</i> DNA detected Ct value: 25.79	Ibuprofen 400 mg (if > 38.5 °C). TMP + SMX 1920 mg × 3. Prednisolone 40 mg Æ-2 to 40 mg × 1 to 20 mg × 1
September 30, 2022	Candida Ag (mannans): Positive	Fluconazol 150 mg × 1 to 300 mg × 1
October 14, 2022	New fever episode/sepsis	Azathioprine was suspended. Treatment of pneumocystosis (TMP + SMX and prednisolone) finished. Piperacillin + tazobactam 4500 mg × 4. Amikacine 250 mg × 2
October 17, 2022	<i>E. coli</i> detected in microbiological blood sample cultures	Piperacillin + tazobactam 4500 mg × 4. Amikacine 250 mg × 2. Paracetamol 1000 mg × 1 (if > 38.5 °C)
October 18, 2022	<i>E. faecium</i> detected in microbiological urine sample cultures	
October 19, 2022	No clinical effect in terms of sepsis	Linezolid 600 mg × 2 added to antibiotic therapy
October 26, 2022	Acute conjunctivitis of both eyes	Hypromellose 1 mg × 4
October 31, 2022	Overall conditions stabilized	

Ag: Antigen; CD: Crohn's disease; CMV: Cytomegalovirus; Ct: Cycle threshold; DNA: Deoxyribonucleic acid; *E. coli*: *Escherichia coli*; *E. faecium*: *Enterococcus faecium*; EBV: Epstein Barr virus; HIV: Human immunodeficiency virus; *P. jirovecii*: *Pneumocystis jirovecii*; PE: Pulmonary embolism; SpO<sub>2</sub>: Oxygen saturation; TMP + SMX: Trimethoprim + sulfamethoxazole.

Continuing on the negative note, as HIV persists in the body, other infections have a greater chance of developing, including opportunistic ones such as *P. jirovecii*. New data shows that IBD patients with an additional risk factor, of which HIV is the most common one, are more likely to develop pneumocystic pneumonia. However, there are currently no clear recommendations on how to prevent it in the presence of IBD and a background of HIV[3]. The authors of the report of a similar clinical case of a patient who presented with CD without HIV but was infected with *P. jirovecii*, mention that pneumocystic pneumonia prophylaxis is still questionable for patients with IBD, while HIV-positive people can benefit from it if their CD4<sup>+</sup> counts are < 200 cells/μL[10]. However, there are still no clear pneumocystosis chemoprophylaxis guidelines. Therefore, the risk factors and immune system criteria should be taken into account before its publication[10]. Additionally, since CD requires a person to take immunosuppressive drugs for prolonged periods, a previous study revealed that it triples the odds of IBD patients getting infected with EBV, CMV, varicella-zoster virus, and herpes simplex virus, especially during an acute illness episode and while using azathioprine, which by itself brings many adverse effects, such as impaired liver function and a risk of blood lymph cancer[11,12]. Therefore, in our case, discontinuing azathioprine seemed necessary to manage not only pancytopenia but also the simultaneous occurrence of EBV, CMV, and pneumocystosis. Another health issue that requires attention for those on immunosuppressive drugs could be opportunistic fungal infections. One analysis has distinguished the risk factors for candidiasis, and some of them were found in our patient. For CD, the female sex and Caucasian race; meanwhile, for IBD, it could have been drastic weight loss, anemia, and probable pulmonary circulation disorders[13]. Additionally, HIV infection and antibiotic treatment must have also played a role in the deterioration of our patient's immune system. According to another review, *Candida* stands out among all GI fungal infections among IBD patients[14]. The authors of a similar case in which weight loss was also reported noted that fungal infections are observed more frequently among patients with CD than among those with UC[15]. Therefore, examinations for any signs of fungal infection should be performed routinely for these people. Furthermore, some bacterial populations (*E. coli* for instance) are known to expand in size during IBD because of dysbiosis, which is even more profound among HIV-infected individuals[16]. In addition, HIV and IBD can cause the mucosal barrier of the bowel to lose its integrity and become more permeable[2]. In this case, it might have led to *E. coli* bacteremia and sepsis, which required the clinical pharmacologist to quickly manage the situation with intensive antibiotic therapy that, in the end, accounted for the improvement of the patient's health status.

Finally, we want to draw clinicians' attention to possible threats and suggest preventive measures. Similarly, as another clinical case shows, the early detection of HIV risk factors in a patient who is newly diagnosed with IBD could help initiate appropriate treatment tactics and prepare for opportunistic

infections ahead of time[17]. Even if the patient is HIV-negative, other sexually transmitted infections should be tested for because their symptoms and endoscopic findings can be similar to those of IBD[2]. As mentioned earlier, PE prophylaxis could also be taken into consideration whenever corticosteroid treatment is prescribed for IBD patients with a higher PE risk[9]. Moreover, in a state of immunodeficiency, the sexually transmitted human papillomavirus (HPV) infection is more likely to cause cervical cancer[16]. The latter has already been linked to acquired immune deficiency syndrome; however, a new meta-analysis has also revealed an association between IBD and immunosuppressive drugs; hence, ill women might need to attend the cervical cancer screening program more frequently[18]. Furthermore, according to a previous systematic review, HPV vaccination is a safe and effective option for HIV-infected individuals[19]. As a preventive measure, gastroenterologists can provide patients with IBD and HIV with more information on available inactivated vaccines; for example, those against influenza, pneumococcus, rabies, hepatitis A and B, meningococcus, and tetanus, as they can potentially lower hospitalization or death rates among these patients; however, titers and monitoring should be taken into account[7,20,21].

## CONCLUSION

The early diagnosis of HIV in patients with IBD is crucial; however, there is currently not enough information on the interaction between these diseases. As a result, clinicians find it difficult to choose an optimal treatment strategy to achieve and maintain remission in these patients who also require careful follow-up and proper prophylactic measures against many infections. In this paper, we present the case of an HIV-infected patient with CD to encourage other professionals to adopt early preventive measures against complications for immunocompromised patients or to diagnose the illnesses early enough. We believe that some of the shared insights on the interaction between IBD and HIV could be of value.

## ACKNOWLEDGEMENTS

We wish to thank the patient and Vilnius University Hospital Santaros Clinics for giving consent and providing the data to report this case.

## FOOTNOTES

**Author contributions:** Vinikaite A and Jasinskaite D searched the literature and wrote the article based on the data analyzed (provided by Kurlinkus B); Sadauskaite G and Buineviciute A were the gastroenterologists who followed up with the patient; Kurlinkus B obtained the patient's informed consent and performed data extraction; Kurlinkus B, Kiudelis V, and Strainiene S reviewed and edited the manuscript; Sadauskaite G and Kazenaite E revised the manuscript for important intellectual content; and all authors have read and approved the final manuscript.

**Informed consent statement:** The authors declare that written informed consent was obtained from the patient for the publication of this report.

**Conflict-of-interest statement:** All the authors report no relevant conflicts of interest for this article.

**CARE Checklist (2016) statement:** The authors have read the CARE Checklist (2016), and the manuscript was prepared and revised according to the CARE Checklist (2016).

**Open-Access:** This article is an open-access article that was selected by an in-house editor and fully peer-reviewed by external reviewers. It is distributed in accordance with the Creative Commons Attribution NonCommercial (CC BY-NC 4.0) license, which permits others to distribute, remix, adapt, build upon this work non-commercially, and license their derivative works on different terms, provided the original work is properly cited and the use is non-commercial. See: <https://creativecommons.org/licenses/by-nc/4.0/>

**Country/Territory of origin:** Lithuania

**ORCID number:** Ausra Vinikaite 0009-0000-3874-6041; Benediktas Kurlinkus 0000-0001-9885-9347; Dominyka Jasinskaite 0000-0002-3221-9643; Sandra Strainiene 0000-0003-1884-1353; Goda Sadauskaite 0000-0001-5470-6154; Vytautas Kiudelis 0000-0003-3680-1320; Edita Kazenaite 0000-0002-7127-1399.

**S-Editor:** Wang JJ

**L-Editor:** A

**P-Editor:** Zhao S

## REFERENCES

- 1 **Sinha A**, Rivera AS, Chadha SA, Prasada S, Pawlowski AE, Thorp E, DeBerge M, Ramsey-Goldman R, Lee YC, Achenbach CJ, Lloyd-Jones DM, Feinstein MJ. Comparative Risk of Incident Coronary Heart Disease Across Chronic Inflammatory Diseases. *Front Cardiovasc Med* 2021; **8**: 757738 [PMID: [34859072](#) DOI: [10.3389/fcvm.2021.757738](#)]
- 2 **Siwak E**, Suchacz MM, Cielniak I, Kubicka J, Firląg-Burkacka E, Wiercińska-Drapała A. Inflammatory Bowel Disease in Adult HIV-Infected Patients-Is Sexually Transmitted Infections Misdiagnosis Possible? *J Clin Med* 2022; **11** [PMID: [36142970](#) DOI: [10.3390/jcm11185324](#)]
- 3 **Schwartz J**, Stein DJ, Feuerstein JD. Comprehensive National Inpatient Sample data reveals low but rising *Pneumocystis jirovecii* pneumonia risk in inflammatory bowel disease patients. *Ann Gastroenterol* 2022; **35**: 260-266 [PMID: [35599933](#) DOI: [10.20524/aog.2022.0713](#)]
- 4 **National Institutes of Health-University of California Expert Panel for Corticosteroids as Adjunctive Therapy for *Pneumocystis Pneumonia***. Consensus statement on the use of corticosteroids as adjunctive therapy for pneumocystis pneumonia in the acquired immunodeficiency syndrome. *N Engl J Med* 1990; **323**: 1500-1504 [PMID: [2136587](#) DOI: [10.1056/NEJM199011223232131](#)]
- 5 **Ho TH**, Cohen BL, Colombel JF, Mehandru S. Review article: the intersection of mucosal pathophysiology in HIV and inflammatory bowel disease, and its implications for therapy. *Aliment Pharmacol Ther* 2014; **40**: 1171-1186 [PMID: [25267394](#) DOI: [10.1111/apt.12976](#)]
- 6 **Casiraghi S**, Baggi P, Lanza P, Bozzola A, Vinco A, Villanacci V, Castelli F, Ronconi M. Simultaneous Diagnosis of Acute Crohn's Disease and Endometriosis in a Patient Affects HIV. *Case Rep Gastrointest Med* 2018; **2018**: 1509167 [PMID: [29854490](#) DOI: [10.1155/2018/1509167](#)]
- 7 **Chebli JM**, Gaburri PD, Chebli LA, da Rocha Ribeiro TC, Pinto AL, Ambrogini Júnior O, Damião AO. A guide to prepare patients with inflammatory bowel diseases for anti-TNF- $\alpha$  therapy. *Med Sci Monit* 2014; **20**: 487-498 [PMID: [24667275](#) DOI: [10.12659/MSM.890331](#)]
- 8 **Vautrin A**, Manchon L, Garcel A, Campos N, Lapasset L, Laaref AM, Bruno R, Gislard M, Dubois E, Scherrer D, Ehrlich JH, Tazi J. Both anti-inflammatory and antiviral properties of novel drug candidate ABX464 are mediated by modulation of RNA splicing. *Sci Rep* 2019; **9**: 792 [PMID: [30692590](#) DOI: [10.1038/s41598-018-37813-y](#)]
- 9 **Cheng K**, Faye AS. Venous thromboembolism in inflammatory bowel disease. *World J Gastroenterol* 2020; **26**: 1231-1241 [PMID: [32256013](#) DOI: [10.3748/wjg.v26.i12.1231](#)]
- 10 **Omer O**, Cohen P, Neong SF, Smith GV. *Pneumocystis pneumonia* complicating immunosuppressive therapy in Crohn's disease: A preventable problem? *Frontline Gastroenterol* 2016; **7**: 222-226 [PMID: [28839859](#) DOI: [10.1136/flgastro-2014-100458](#)]
- 11 **Wisniewski A**, Kirchgessner J, Seksik P, Landman C, Bourrier A, Nion-Larmurier I, Marteau P, Cosnes J, Sokol H, Beaugerie L; the Saint-Antoine IBD network. Increased incidence of systemic serious viral infections in patients with inflammatory bowel disease associates with active disease and use of thiopurines. *United European Gastroenterol J* 2020; **8**: 303-313 [PMID: [32529821](#) DOI: [10.1177/2050640619889763](#)]
- 12 **Neurath M**. Thiopurines in IBD: What Is Their Mechanism of Action? *Gastroenterol Hepatol (N Y)* 2010; **6**: 435-436 [PMID: [20827366](#)]
- 13 **Mushtaq K**, Khan Z, Aziz M, Alyousif ZA, Siddiqui N, Khan MA, Nawras A. Trends and outcomes of fungal infections in hospitalized patients of inflammatory bowel disease: a nationwide analysis. *Transl Gastroenterol Hepatol* 2020; **5**: 35 [PMID: [32632386](#) DOI: [10.21037/tgh.2019.10.14](#)]
- 14 **Stamatopoulos GA**, Ioannou P, Petrikos G, Tsioutis C. Fungal infections in patients with inflammatory bowel disease: A systematic review. *Mycoses* 2018; **61**: 366-376 [PMID: [29453860](#) DOI: [10.1111/myc.12753](#)]
- 15 **Sharif M**, Saddique MU, Zahid M, Khan D, Bashir T, Murshed K. Oropharyngeal Candidiasis as a Presenting Symptom of Crohn's Disease. *Case Rep Gastroenterol* 2020; **14**: 178-185 [PMID: [32399001](#) DOI: [10.1159/000506931](#)]
- 16 **Santiago-Rodriguez TM**, Hollister EB. Human Virome and Disease: High-Throughput Sequencing for Virus Discovery, Identification of Phage-Bacteria Dysbiosis and Development of Therapeutic Approaches with Emphasis on the Human Gut. *Viruses* 2019; **11** [PMID: [31323792](#) DOI: [10.3390/v11070656](#)]
- 17 **Davis W**, Vavilin I, Malhotra N. Biologic Therapy in HIV: To Screen or Not to Screen. *Cureus* 2021; **13**: e15941 [PMID: [34336440](#) DOI: [10.7759/cureus.15941](#)]
- 18 **Allegretti JR**, Barnes EL, Cameron A. Are patients with inflammatory bowel disease on chronic immunosuppressive therapy at increased risk of cervical high-grade dysplasia/cancer? A meta-analysis. *Inflamm Bowel Dis* 2015; **21**: 1089-1097 [PMID: [25895005](#) DOI: [10.1097/MIB.0000000000000338](#)]
- 19 **Zizza A**, Banchelli F, Guido M, Marotta C, Di Gennaro F, Mazzucco W, Pistotti V, D'Amico R. Efficacy and safety of human papillomavirus vaccination in HIV-infected patients: a systematic review and meta-analysis. *Sci Rep* 2021; **11**: 4954 [PMID: [33654181](#) DOI: [10.1038/s41598-021-83727-7](#)]
- 20 **Jordan A**, Mills K, Sobukonla T, Kelly A, Flood M. Influenza, PCV13, and PPSV23 Vaccination Rates Among Inflammatory Bowel Disease Patients With Additional Co-Morbidities as per CDC Recommendations. *Cureus* 2021; **13**: e18387 [PMID: [34729268](#) DOI: [10.7759/cureus.18387](#)]
- 21 **Besombes J**, Souala F, Bouguen G, Guyader D, Grolhier C, Thibault V, Pronier C. Acute hepatitis B virus infection despite vaccination in a patient treated by infliximab: a case report. *BMC Gastroenterol* 2022; **22**: 322 [PMID: [35768794](#) DOI: [10.1186/s12876-022-02397-5](#)]





Published by **Baishideng Publishing Group Inc**  
7041 Koll Center Parkway, Suite 160, Pleasanton, CA 94566, USA

**Telephone:** +1-925-3991568

**E-mail:** [bpgoffice@wjgnet.com](mailto:bpgoffice@wjgnet.com)

**Help Desk:** <https://www.f6publishing.com/helpdesk>

<https://www.wjgnet.com>

