

Metastatic colon cancer treated using traditional Chinese medicine combined with chemotherapy: A case report

Chen-Geng Deng, Meng-Yuan Tang, Xue Pan, Zhao-Heng Liu

Specialty type: Oncology

Provenance and peer review:

Unsolicited article; Externally peer reviewed.

Peer-review model: Single blind

Peer-review report's scientific quality classification

Grade A (Excellent): 0

Grade B (Very good): 0

Grade C (Good): C, C, C

Grade D (Fair): D

Grade E (Poor): 0

P-Reviewer: Al-Emam AMA, Saudi Arabia; Bacharaki D, Greece; Cheng TH, Taiwan

Received: February 20, 2023

Peer-review started: February 20, 2023

First decision: March 24, 2023

Revised: April 12, 2023

Accepted: May 26, 2023

Article in press: May 26, 2023

Published online: July 6, 2023



Chen-Geng Deng, Zhao-Heng Liu, School of Life Sciences, Beijing University of Chinese Medicine, Beijing 102401, China

Meng-Yuan Tang, Department of Breast and Thyroid Surgery, China-Japan Friendship Hospital, Beijing 100029, China

Xue Pan, Post-Doctoral Mobile Station, Guang'anmen Hospital, China Academy of Chinese Medical Sciences, Beijing 100053, China

Corresponding author: Zhao-Heng Liu, MD, Assistant Professor, School of Life Sciences, Beijing University of Chinese Medicine, Northeast Corner of the Intersection of Yangguang South Street and Baiyang East Road, Fangshan District, Beijing 102401, China.
zliu@bucm.edu.cn

Abstract

BACKGROUND

Colon cancer (CC) is one of the leading causes of cancer-related morbidity and mortality worldwide. Traditional Chinese medicine (TCM) is widely used in the treatment of various chronic diseases. CC easily metastasizes and results in high morbidity and mortality rates.

CASE SUMMARY

A 71-year-old man with a 12-year history of old myocardial infarction and a 7-year history of type 2 diabetes mellitus was diagnosed with CC and underwent right hemicolectomy 1 year ago. Tumor biopsy revealed moderately poorly differentiated adenocarcinoma. Subsequently, chemotherapy with oxaliplatin and paclitaxel was administered. Anastomosis recurrence and pelvic metastasis were noted 37 d later. The patient received eight 21-d cycles of adjuvant chemotherapy with oxaliplatin and capecitabine after recurrence. However, the tumor persisted, and chemotherapy-related liver damage developed gradually. Thus, he was advised to take TCM for the recurrence and pelvic metastasis. The patient's metastatic CC was cured after receiving TCM combined with long-term chemotherapy.

CONCLUSION

TCM may be an effective adjunct therapy in the treatment of patients with metastatic CC.

Key Words: Metastatic colon cancer; Traditional Chinese medicine; Tumor; Pelvic

metastasis; Chemotherapy; Case report

©The Author(s) 2023. Published by Baishideng Publishing Group Inc. All rights reserved.

Core Tip: Herein, we report a case of a patient with metastatic colon cancer (CC) who underwent right hemicolectomy and received 8 cycles of chemotherapy coupled with traditional Chinese medicine (TCM). After treatment, the patient was cured and there was no recurrence during the subsequent follow-up. We believe that TCM can provide a new postoperative treatment modality for CC, as the patient's enteroscopy revealed that the anastomotic stoma of the transverse colon had become smooth 7 mo after treatment.

Citation: Deng CG, Tang MY, Pan X, Liu ZH. Metastatic colon cancer treated using traditional Chinese medicine combined with chemotherapy: A case report. *World J Clin Cases* 2023; 11(19): 4670-4676

URL: <https://www.wjgnet.com/2307-8960/full/v11/i19/4670.htm>

DOI: <https://dx.doi.org/10.12998/wjcc.v11.i19.4670>

INTRODUCTION

Colon cancer (CC), the 3rd most common cancer worldwide, is one of the leading causes of cancer-related morbidity and mortality. It generally occurs among people aged > 70 years. Common therapies for CC include adjuvant chemotherapy, palliative chemotherapy, and palliative targeted therapy[1]. However, palliative chemotherapy only provides limited benefits in terms of prolonging progression-free survival, alleviating symptoms, and improving the quality of life of patients, without offering a cure for the disease. Surgery for CC that invades other organs or structures can be challenging[2]. Traditional Chinese medicine (TCM) offers specific treatment approaches for delaying disease progression, and therefore, may emerge as a significant alternative treatment for CC.

Right-sided cancers are typically reported in CC. Herein, we report a case of a 71-year-old man with a 12-year history of remote myocardial infarction and a 7-year history of type 2 diabetes mellitus whose metastatic CC was successfully treated with a combination of TCM and long-term chemotherapy. The details of the case are presented in accordance with the CARE reporting checklist.

CASE PRESENTATION

Chief complaints

A 71-year-old male patient with a 12-year history of prior myocardial infarction and a 7-year history of type 2 diabetes mellitus was admitted to our hospital for further evaluation and treatment of postoperative metastatic CC.

History of present illness

Upon admission to our hospital, the patient was diagnosed with CC and had undergone right hemicolectomy 6 mo earlier. He also complained of numbness and tingling in the limbs for the past 3 years and had lost 10 kg in the past 6 mo. He denied fever, cough, chest pain, chest tightness, abdominal pain, or abdominal distention. Tumor biopsy revealed moderately to poorly differentiated adenocarcinoma (Figure 1) with invasion of the deep muscular layer extending to the serosal layer (Figure 2).

Anastomosis recurrence and pelvic metastasis were noted 37 d later (Figure 3). Meanwhile, chemotherapy-related liver damage developed slowly. During a hospital visit, an irregular-density shadow of soft tissue was observed near the anastomotic stoma of the transverse colon, with a size of approximately 1.4 cm × 0.9 cm (Figure 4).

History of past illness

The patient received eight cycles of adjuvant chemotherapy with oxaliplatin and capecitabine after right hemicolectomy.

Personal and family history

The patient had no personal or family history.

Physical examination

His vital signs were as follows: temperature, 36.1 °C; blood pressure 117/62 mmHg; heart rate 86 beats/

Table 1 Tumor markers						
Marker	Reference range	September 2020	November 2020	January 2021	March 2021	May 2021
AFP in ng/mL	0.00–7.00	2.31	10.36 ¹	1.95	1.64	1.35
CEA in ng/mL	0.00–4.30	4.52 ¹	6.89 ¹	4.93 ¹	4.80 ¹	4.21
CA199 in U/mL	0.00–27	18.43	26.4	33.32 ¹	22.85	22.97

¹High level, changes in this patient’s tumor marker levels. AFP: Alpha-fetoprotein; CEA: Carcinoembryonic antigen; CA199: Cancer antigen 199.

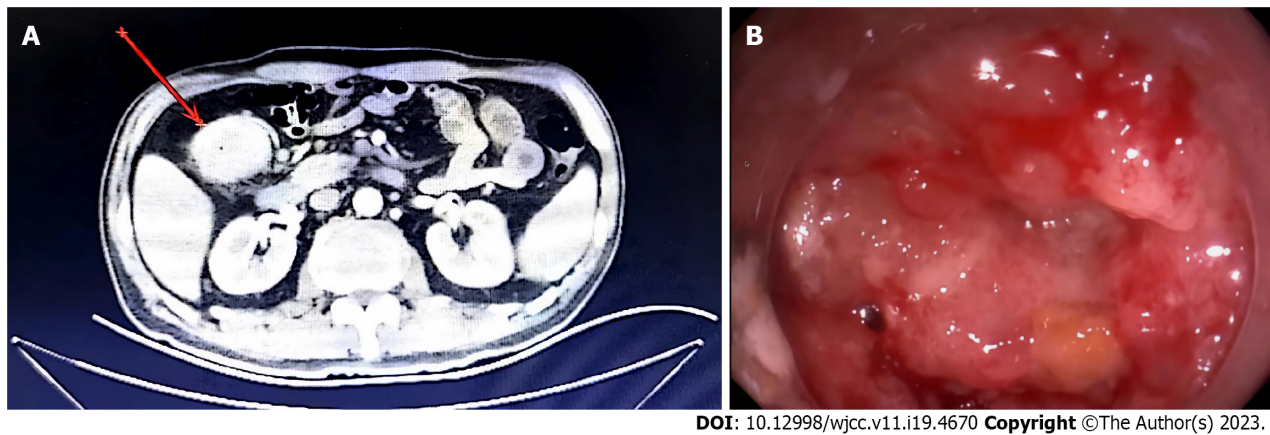


Figure 1 Initial X-ray and endoscopy findings. A: X-ray; B: Endoscopy. The patient’s tumor was located in the hepatic flexure of the right colon.

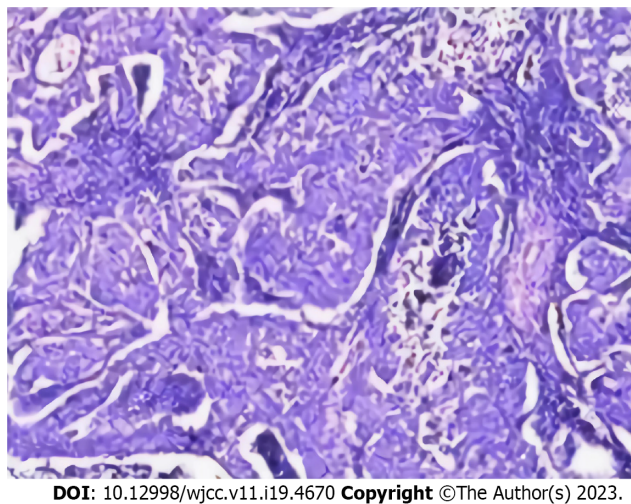


Figure 2 Histopathology of the patient’s tumor. Hematoxylin and eosin staining of a biopsy of the patient’s tumor suggested moderately to poorly differentiated adenocarcinoma.

min; and respiratory rate 20 breaths/min.

Laboratory examinations

The levels of tumor markers, including alpha-fetoprotein, carcinoembryonic antigen, and cancer antigen 199, showed an increasing trend (Table 1). Other laboratory tests were within normal limits.

Imaging examinations

The patient’s previous medical records suggested moderately to poorly differentiated adenocarcinoma (Figure 1). Postoperative immunohistochemical results revealed tumor invasion of the deep muscular layer, extending to the serosal layer (Figure 2). Anastomosis recurrence and pelvic metastasis were noted 37 d later (Figure 3). Imaging revealed an irregular-density shadow of soft tissue was observed near the anastomotic stoma of the transverse colon, with a size of approximately 1.4 cm × 0.9 cm

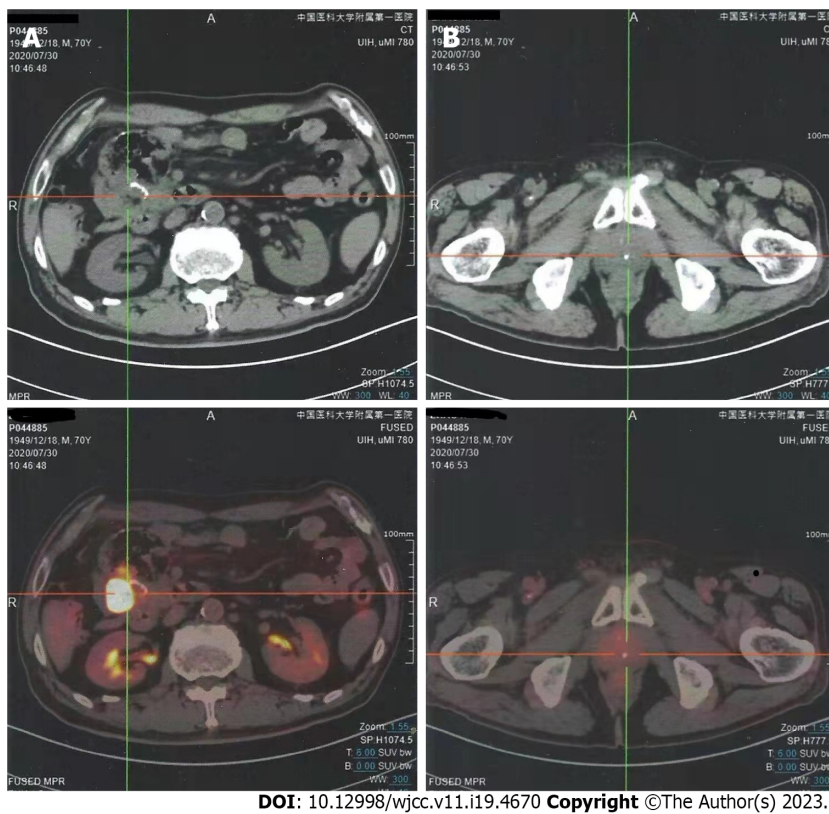


Figure 3 Computed tomography findings at postoperative day 37. A: Anastomosis recurrence; B: Pelvic metastasis.

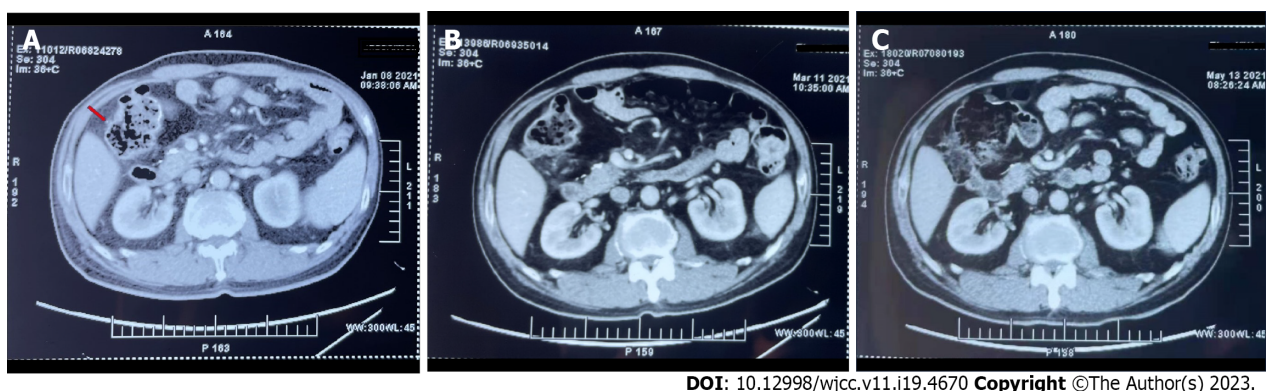


Figure 4 Computed tomography before and after traditional Chinese medicine. The patient presented to our hospital after receiving eight cycles of adjuvant chemotherapy with oxaliplatin and capecitabine. A: Initial computed tomography results revealing pelvic metastasis near the anastomotic stoma of the transverse colon, with a size of approximately 1.4 cm × 0.9 cm; B and C: Traditional Chinese medicine led to a gradual reduction in the tumor size according to the re-examinations performed 2 mo (B) and 4 mo (C) after presentation.

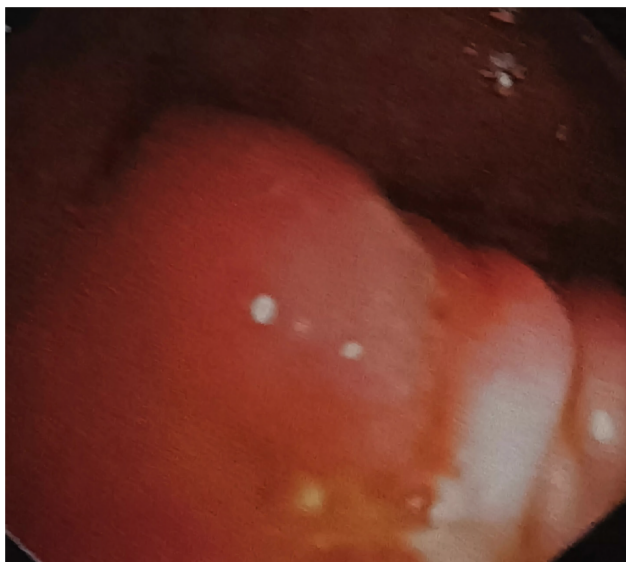
(Figure 4A).

FINAL DIAGNOSIS

The final pathological diagnosis after laboratory and imaging examinations was metastatic CC (stage T2N2bM1a).

TREATMENT

We advised the patient to initiate TCM and prescribed a regimen consisting of Huangqi (45 g), Chenpi (15 g), Daxueteng (30 g), Baijiangcao (10 g), and Shancigu (15 g).



DOI: 10.12998/wjcc.v11.i19.4670 Copyright ©The Author(s) 2023.

Figure 5 Follow-up colonoscopy finding. Colonoscopy was performed 7 mo after traditional Chinese medicine was given. The anastomotic stoma of the transverse colon has become smooth.

OUTCOME AND FOLLOW-UP

Computed tomography revealed that the recurrent neoplasm disappeared after 37 d of sustained medication, and a reexamination performed 4 mo later revealed no recurrence (Figure 4B and C). Additionally, enteroscopy performed 7 mo later showed that the anastomotic stoma of the transverse colon had become smooth (Figure 5). These findings were consistent with the changes in the patient's tumor marker levels (Table 1).

DISCUSSION

Here, we reported the case of a patient with recurrent metastatic CC after right hemicolectomy who received 8 cycles of chemotherapy combined with TCM and was finally cured. No recurrence was noted during subsequent follow-up. TCM may provide a new treatment modality for CC postoperatively, as the patient's enteroscopy revealed that the anastomotic stoma of the transverse colon had become smooth 7 mo after treatment.

Currently, the recommended treatment for CC includes surgical resection of cancer and counseling of patients to receive adjuvant chemotherapy, palliative chemotherapy, or palliative targeted therapy[3,4]. The current management of disseminated metastatic CC involves various active drugs (either in combination or as single agents), including 5-fluorouracil/leucovorin, capecitabine, irinotecan, oxaliplatin, bevacizumab, cetuximab, panitumumab, ziv-aflibercept, ramucirumab, regorafenib, trifluridine-tipiracil, pembrolizumab, and nivolumab[5]. Treatment personalization allows patients to maximize benefits while minimizing harm, thereby enabling optimal survival and quality of life[6]. Most patients show good curative effects and high long-term survival rates. The number of patients undergoing surgical resection has increased the associated mortality and morbidity, although approximately 10.8% of patients who undergo colectomy for CC have metastatic diseases[7]. However, combination chemotherapy is associated with additional toxicity, which is harmful to patients[8].

Our treatment approach aimed to achieve several goals: Elimination of recurrence and metastatic CC in the pelvis; reduction of chemotherapy-related liver toxicity; and improvement of patient overall quality of life. To achieve these goals, we utilized TCM to dispel cold, remove dampness, reduce phlegm, and resolve masses, as well as to provide detoxifying effects. Huangqi is widely used as an immune stimulant, tonic, antioxidant, hepatoprotectant, diuretic, expectorant, and antidiabetic and anticancer agent[9]. It can enhance the body's natural defense mechanisms. Astragaloside might contribute to the immunostimulating and anticancer effects of Huangqi, which have been demonstrated in clinical trials and animal experiments[10]. Shancigu extract can significantly inhibit the proliferation of human CC SW480 cells and induce apoptosis[11]. Another study revealed the role of active components of Baijiangcao in CC treatment[12]. Other herbs, such as Daxueteng, are also known to exert antitumor effects. Daxueteng and Baijiangcao can play an important role in intestinal diseases and enhance human immunity. The addition of TCM in the treatment regimen enhances the abovementioned effects.

This report has several limitations that preclude us from drawing definitive conclusions. Firstly, it is a single case report, and the evidence level of this treatment approach is insufficient. While we can adjust the prescription slightly based on different conditions, more research is needed to establish the efficacy of TCM combined with chemotherapy. Secondly, the follow-up period is limited, and long-term follow-up is required to confirm the clinical validity of this treatment modality.

CONCLUSION

TCM may be an effective adjunct therapy to current standard-of-care chemotherapy in the treatment of metastatic CC, as suggested by the resolution of our patient's metastatic CC after laparoscopic radical resection followed by TCM. However, further investigations are warranted to confirm the efficacy and mechanisms of TCM treatments for CC.

FOOTNOTES

Author contributions: Deng CG, Tang MY, and Pan X contributed equally to this work; Deng CG drafted and edited the original manuscript; Tang MY edited the manuscript and analyzed the data; Pan X collected the data; Liu ZH treated the patient and supervised the study; all authors have read and approved the final manuscript.

Supported by The National Natural Science Foundation of China, No. 81904049; Beijing Natural Science Foundation, No. 7202118; The National Traditional Chinese Medicine Inheritance Innovation Project, No. ZYYCXTD-C-202006-9; and The Basic Scientific Research Foundation of Beijing University of Chinese Medicine, No. 2021-JYB-XJSJJ-033.

Informed consent statement: Written informed consent for the publication of medical information was obtained from the patient.

Conflict-of-interest statement: The authors declare that they have no competing interests.

CARE Checklist (2016) statement: The authors have read the CARE Checklist (2016), and the manuscript was prepared and revised according to the CARE Checklist (2016).

Open-Access: This article is an open-access article that was selected by an in-house editor and fully peer-reviewed by external reviewers. It is distributed in accordance with the Creative Commons Attribution NonCommercial (CC BY-NC 4.0) license, which permits others to distribute, remix, adapt, build upon this work non-commercially, and license their derivative works on different terms, provided the original work is properly cited and the use is non-commercial. See: <https://creativecommons.org/licenses/by-nc/4.0/>

Country/Territory of origin: China

ORCID number: Chen-Geng Deng 0000-0002-8535-8006; Meng-Yuan Tang 0000-0001-9746-8096; Xue Pan 0000-0003-0299-7556; Zhao-Heng Liu 0000-0002-4729-8102.

S-Editor: Ma YJ

L-Editor: Filipodia

P-Editor: Zhao S

REFERENCES

- 1 **Moth EB**, Vardy J, Blinman P. Decision-making in geriatric oncology: systemic treatment considerations for older adults with colon cancer. *Expert Rev Gastroenterol Hepatol* 2016; **10**: 1321-1340 [PMID: 27718755 DOI: 10.1080/17474124.2016.1244003]
- 2 **Klaver CEL**, Kappen TM, Borstlap WAA, Bemelman WA, Tanis PJ. Laparoscopic surgery for T4 colon cancer: a systematic review and meta-analysis. *Surg Endosc* 2017; **31**: 4902-4912 [PMID: 28432461 DOI: 10.1007/s00464-017-5544-7]
- 3 **Ku G**, Tan IB, Yau T, Boku N, Laohavinij S, Cheng AL, Kang YK, de Lima Lopes G Jr. Management of colon cancer: resource-stratified guidelines from the Asian Oncology Summit 2012. *Lancet Oncol* 2012; **13**: e470-e481 [PMID: 23117002 DOI: 10.1016/S1470-2045(12)70424-2]
- 4 **Banerjee A**, Pathak S, Subramaniam VD, G D, Murugesan R, Verma RS. Strategies for targeted drug delivery in treatment of colon cancer: current trends and future perspectives. *Drug Discov Today* 2017; **22**: 1224-1232 [PMID: 28545838 DOI: 10.1016/j.drudis.2017.05.006]
- 5 **Benson AB 3rd**, Venook AP, Cederquist L, Chan E, Chen YJ, Cooper HS, Deming D, Engstrom PF, Enzinger PC, Fichera A, Grem JL, Grothey A, Hochster HS, Hoffer S, Hunt S, Kamel A, Kirilcuk N, Krishnamurthi S, Messersmith WA, Mulcahy MF, Murphy JD, Nurkin S, Saltz L, Sharma S, Shibata D, Skibber JM, Sofocleous CT, Stoffel EM, Stotsky-

- Himelfarb E, Willett CG, Wu CS, Gregory KM, Freedman-Cass D. Colon Cancer, Version 1.2017, NCCN Clinical Practice Guidelines in Oncology. *J Natl Compr Canc Netw* 2017; **15**: 370-398 [PMID: [28275037](#) DOI: [10.6004/jnccn.2017.0036](#)]
- 6 **Benson AB**, Venook AP, Al-Hawary MM, Cederquist L, Chen YJ, Ciombor KK, Cohen S, Cooper HS, Deming D, Engstrom PF, Garrido-Laguna I, Grem JL, Grothey A, Hochster HS, HOFFE S, Hunt S, Kamel A, Kirilcuk N, Krishnamurthi S, Messersmith WA, Meyerhardt J, Miller ED, Mulcahy MF, Murphy JD, Nurkin S, Saltz L, Sharma S, Shibata D, Skibber JM, Sofocleous CT, Stoffel EM, Stotsky-Himelfarb E, Willett CG, Wuthrick E, Gregory KM, Freedman-Cass DA. NCCN Guidelines Insights: Colon Cancer, Version 2.2018. *J Natl Compr Canc Netw* 2018; **16**: 359-369 [PMID: [29632055](#) DOI: [10.6004/jnccn.2018.0021](#)]
- 7 **Moghadamyeghaneh Z**, Hanna MH, Hwang G, Mills S, Pigazzi A, Stamos MJ, Carmichael JC. Outcomes of colon resection in patients with metastatic colon cancer. *Am J Surg* 2016; **212**: 264-271 [PMID: [27094117](#) DOI: [10.1016/j.amjsurg.2016.01.025](#)]
- 8 **Meyers BM**, Cosby R, Queresby F, Jonker D. Adjuvant Chemotherapy for Stage II and III Colon Cancer Following Complete Resection: A Cancer Care Ontario Systematic Review. *Clin Oncol (R Coll Radiol)* 2017; **29**: 459-465 [PMID: [28341242](#) DOI: [10.1016/j.clon.2017.03.001](#)]
- 9 **Fu J**, Wang Z, Huang L, Zheng S, Wang D, Chen S, Zhang H, Yang S. Review of the botanical characteristics, phytochemistry, and pharmacology of *Astragalus membranaceus* (Huangqi). *Phytother Res* 2014; **28**: 1275-1283 [PMID: [25087616](#) DOI: [10.1002/ptr.5188](#)]
- 10 **Liu P**, Zhao H, Luo Y. Anti-Aging Implications of *Astragalus Membranaceus* (Huangqi): A Well-Known Chinese Tonic. *Aging Dis* 2017; **8**: 868-886 [PMID: [29344421](#) DOI: [10.14336/AD.2017.0816](#)]
- 11 **Wang Y**, Tang J, Sun P, Lin SH, Zhang X. [Effect of *Pleurotus eryngii* extract on proliferation and apoptosis of human colon cancer SW480 cells]. *Zhongguo Zhongyi Jichu Yixue Zazhi* 2021; **27**: 1754-1758 [DOI: [10.19945/j.cnki.issn.1006-3250.2021.11.018](#)]
- 12 **Yang H**, Cheung MK, Yue GG, Leung PC, Wong CK, Lau CB. Integrated Network Pharmacology Analysis and In Vitro Validation Revealed the Potential Active Components and Underlying Mechanistic Pathways of *Herba Patriniae* in Colorectal Cancer. *Molecules* 2021; **26** [PMID: [34641576](#) DOI: [10.3390/molecules26196032](#)]



Published by **Baishideng Publishing Group Inc**
7041 Koll Center Parkway, Suite 160, Pleasanton, CA 94566, USA

Telephone: +1-925-3991568

E-mail: bpgoffice@wjgnet.com

Help Desk: <https://www.f6publishing.com/helpdesk>

<https://www.wjgnet.com>

