



## Pathological complete response to neoadjuvant alectinib in unresectable anaplastic lymphoma kinase positive non-small cell lung cancer: A case report

Lu-Ming Wang, Peng Zhao, Xu-Qi Sun, Feng Yan, Qian Guo

**Specialty type:** Oncology

**Provenance and peer review:**

Unsolicited article; Externally peer reviewed.

**Peer-review model:** Single blind

**Peer-review report's scientific quality classification**

Grade A (Excellent): 0

Grade B (Very good): B, B, B

Grade C (Good): 0

Grade D (Fair): 0

Grade E (Poor): 0

**P-Reviewer:** Bustamante-Lopez LA, Brazil; Chiu ML, United States; Rajer M, Slovenia

**Received:** March 20, 2023

**Peer-review started:** March 20, 2023

**First decision:** June 15, 2023

**Revised:** June 28, 2023

**Accepted:** July 7, 2023

**Article in press:** July 7, 2023

**Published online:** August 6, 2023



**Lu-Ming Wang**, Department of Thoracic Surgery, The First Affiliated Hospital, Zhejiang University School of Medicine, Hangzhou 310002, Zhejiang Province, China

**Peng Zhao, Xu-Qi Sun**, Department of Medical Oncology, The First Affiliated Hospital, Zhejiang University School of Medicine, Hangzhou 310002, Zhejiang Province, China

**Feng Yan, Qian Guo**, Department of Medical Oncology, The First People's Hospital of Hangzhou Lin'an District, Hangzhou 311300, Zhejiang Province, China

**Corresponding author:** Qian Guo, MD, Doctor, Department of Medical Oncology, The First People's Hospital of Hangzhou Lin'an District, No. 548 Yijin Street, Jincheng Street, Lin'an District, Hangzhou 311300, Zhejiang Province, China. [gqwy2007@163.com](mailto:gqwy2007@163.com)

### Abstract

#### BACKGROUND

The development of anaplastic lymphoma kinase (ALK)-tyrosine kinase inhibitors (TKIs) has remarkably improved the prognosis of patients with ALK-positive advanced non-small cell lung cancer (NSCLC). Alectinib, the second-generation ALK-TKI, has been approved as first-line treatment for advanced or metastatic NSCLC patients with ALK rearrangement. Neoadjuvant therapy can achieve tumor downstaging and eradicate occult lesions in patients with potentially resectable disease. Whether neoadjuvant alectinib can be a conversion therapy in ALK-positive advanced NSCLC patients remains unclear.

#### CASE SUMMARY

A 41-year-old man was pathologically diagnosed with locally advanced ALK-positive stage IIIB NSCLC. Alectinib was prescribed to induce tumor downstaging and facilitate the subsequent surgical resection. The tumor was successfully downstaged and pathological complete response was achieved. Left upper lobectomy with mediastinal lymphadenectomy was performed after tumor downstaging. The patient has continued to receive alectinib as adjuvant therapy during postoperative follow-up with a recurrence-free survival of 29 mo as of writing this report.

#### CONCLUSION

This case sheds light on the feasibility and safety of alectinib as a neoadjuvant treatment for stage IIIB NSCLC patients with ALK rearrangement. Its efficacy

needs to be validated in prospective clinical trials.

**Key Words:** Alectinib; Anaplastic lymphoma kinase; Non-small cell lung cancer; Neoadjuvant therapy; Case report

©The Author(s) 2023. Published by Baishideng Publishing Group Inc. All rights reserved.

**Core Tip:** Whether neoadjuvant alectinib can serve as a conversion therapy in patients with anaplastic lymphoma kinase (ALK)-positive advanced non-small-cell lung cancer (NSCLC) remains unclear. We report the first case of ALK-positive stage IIIB NSCLC in which a pathological complete response was achieved after neoadjuvant alectinib therapy. Subsequently, left upper lobectomy with mediastinal lymphadenectomy was performed. Postoperatively, alectinib is being continued as adjuvant therapy with a recurrence-free survival of 29 mo as of date. This case report highlights the feasibility of alectinib as neoadjuvant therapy for unresectable ALK-positive locally advanced NSCLC.

**Citation:** Wang LM, Zhao P, Sun XQ, Yan F, Guo Q. Pathological complete response to neoadjuvant alectinib in unresectable anaplastic lymphoma kinase positive non-small cell lung cancer: A case report. *World J Clin Cases* 2023; 11(22): 5322-5328

**URL:** <https://www.wjgnet.com/2307-8960/full/v11/i22/5322.htm>

**DOI:** <https://dx.doi.org/10.12998/wjcc.v11.i22.5322>

## INTRODUCTION

Lung cancer is the leading cause of cancer-related mortality worldwide, and non-small-cell lung cancer (NSCLC) accounts for approximately 85% cases of lung cancer[1]. Although curative resection is the optimal treatment for NSCLC, only 25% of these patients are eligible for surgical resection owing to delayed diagnosis. Compared with patients who are ineligible for surgery, NSCLC patients receiving surgical resection show significant survival benefit[2].

Neoadjuvant therapy refers to the administration of chemotherapy or radiotherapy before surgical resection of malignant tumors. With the advances in systemic and locoregional treatment modalities (such as targeted drugs and radiotherapy), neoadjuvant therapy has expanded the indications for surgical resection in cancer patients. Effective neoadjuvant therapy can reduce tumor size, achieve tumor downstaging, and eliminate occult micrometastases, thus improving surgical outcomes and prolonging the survival of patients with locally advanced NSCLC. Compared to clinical studies on neoadjuvant treatments for stage IIIA NSCLC, few studies have explored downstaging treatment regimens for patients with stage IIIB NSCLC[3]. Approximately 5%–6% of NSCLC patients have anaplastic lymphoma kinase (ALK) rearrangements, among which echinoderm microtubule-associated protein-like 4-ALK variant (EML4-ALK) is the most common fusion type[4]. EML4-ALK fusion protein is the therapeutic target for ALK-tyrosine kinase inhibitors (TKIs), and has shown promising results in NSCLC patients with ALK rearrangements[5]. In recent years, ALK inhibitors have shown better therapeutic efficacy compared to conventional chemotherapy in patients with ALK-positive NSCLC. Alectinib, a highly selective second-generation ALK inhibitor, is approved as a first-line therapy for ALK-positive advanced NSCLC. Here, we presented the application of neoadjuvant alectinib in a patient with ALK-positive locally advanced NSCLC (stage IIIB-N3), where the tumor was radically resected after downstaging and pathological complete response (pCR) was achieved.

## CASE PRESENTATION

### Chief complaints

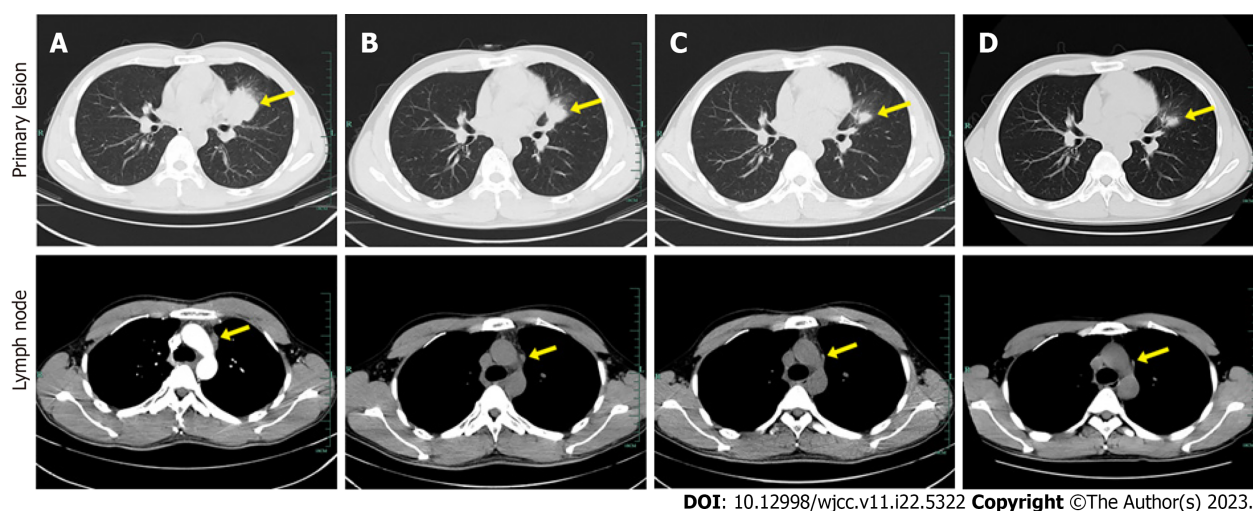
A 41-year-old Chinese man presented to our hospital because of detection of pulmonary nodules in another hospital.

### History of present illness

In August 2019, pulmonary nodules were detected on routine physical examination. He was preliminarily diagnosed with locally advanced NSCLC by bronchoalveolar lavage in a local hospital. Then the patient visited our hospital for further management. Chest computed tomography (CT) displayed a 39 mm × 34 mm lesion in the upper lobe of the left lung near the pulmonary hilum (Figure 1A). A CT-guided percutaneous biopsy was performed in the left lung neoplasm, and immunohistochemical examination showed the neoplasm was ALK positive.

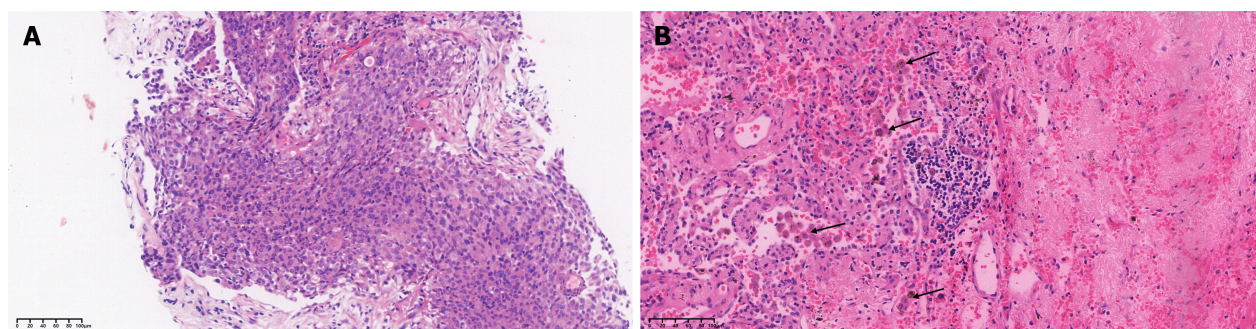
### Personal and family history

The personal and family history was unremarkable. There was no history of underlying diseases (such as hypertension) or smoking. He denied any family history of malignant tumors.



DOI: 10.12998/wjcc.v11.i22.5322 Copyright ©The Author(s) 2023.

**Figure 1** Computed tomography images of lungs in different treatment stages. A: Baseline computed tomography scan performed in August 2019 shows primary lesion in the upper lobe of left lung near the hilum with mediastinal lymph node metastases; B: 10 wk after initiation of alectinib treatment (November 2019); C: Sustained response to disease is observed in June 2020; D: 14 mo after initiation of alectinib treatment (November 2020). The tumor lesions are indicated by yellow arrow.



DOI: 10.12998/wjcc.v11.i22.5322 Copyright ©The Author(s) 2023.

**Figure 2** hematoxylin-eosin stained sections of tumor tissue at baseline and 14 mo later. A: Hematoxylin-eosin staining (200×) results of lung puncture biopsy confirming lung adenocarcinoma; B: HE staining (200×) results showing interstitial vascular and fibrous tissue hyperplasia, eosinophil infiltration, and chronic inflammation of the lung tissue. The arrows point to activated eosinophils.

### Physical examination

On physical examination, the vital signs were as follows: Body temperature, 36.6 °C; blood pressure, 130/80 mmHg; heart rate, 80 beats per min; respiratory rate, 20 breaths per min. Heart, lung, and abdominal examinations showed no remarkable changes.

### Laboratory examinations

On immunohistochemical examination, the neoplasm was positive for CK7, TTF-1, and Napsina A, and negative for p40 and CK5/6. ALK rearrangement was detected by both immunohistochemistry and next-generation sequencing, which indicated EML4-ALK (E13:A20; abundance 17.1%) rearrangement (Figure 2A).

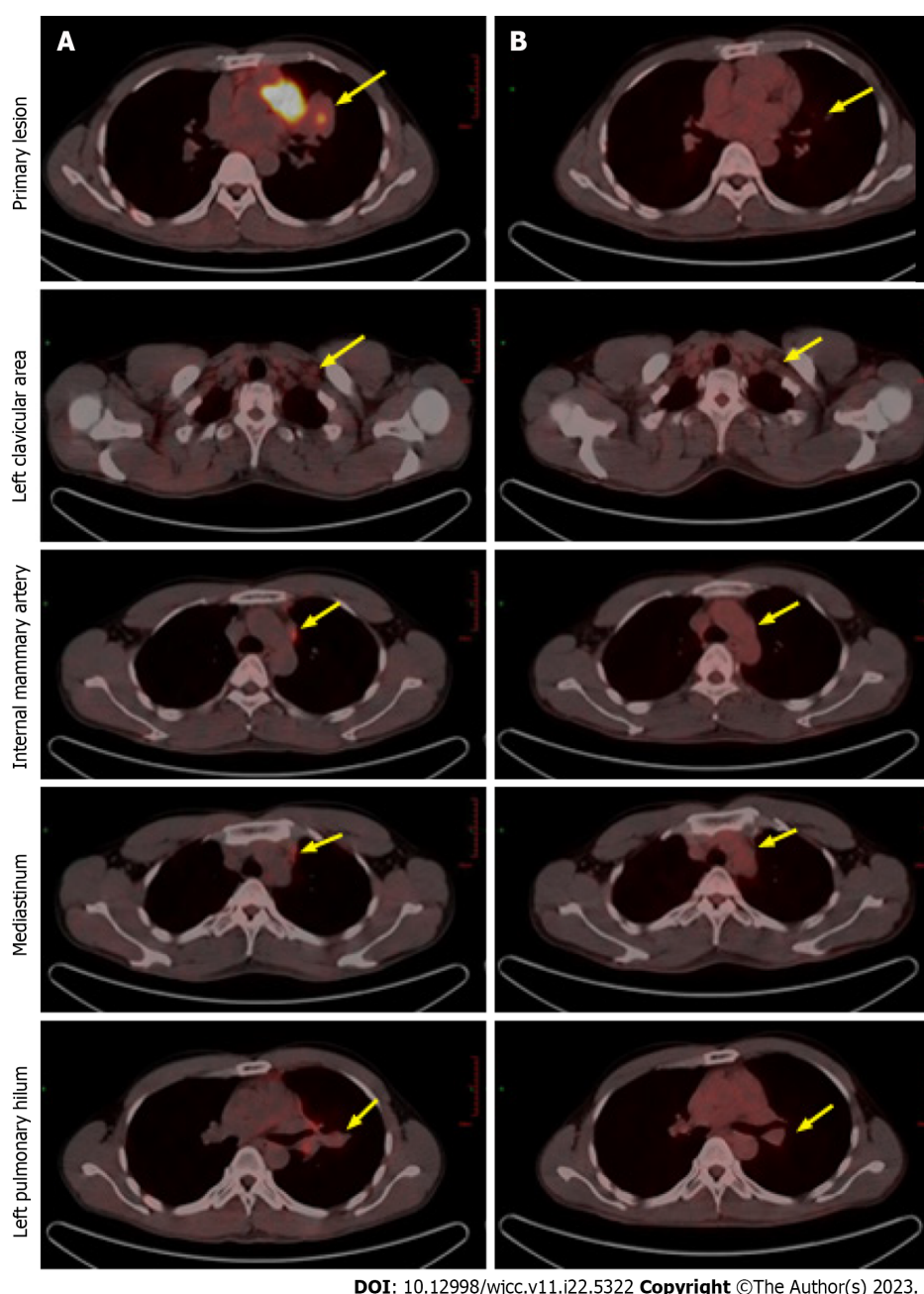
### Imaging examinations

Positron emission tomography (PET) revealed multiple metastatic lymph nodes located in left clavicular, mediastinal, and left hilar region, with no distant metastasis (Figure 3A).

## MULTIDISCIPLINARY EXPERT CONSULTATION

Based on the recommendations of multidisciplinary consultation and willingness of the patient, neoadjuvant alectinib was prescribed to induce tumor downstaging and facilitate the subsequent surgical resection.





DOI: 10.12998/wjcc.v11.i22.5322 Copyright ©The Author(s) 2023.

**Figure 3** Positron emission tomography computed tomography images after alectinib treatment demonstrating partial remission. A: Compared to baseline; B: The primary lesion has shrunk and the enlarged lymph nodes have almost disappeared after 14 mo of treatment. Positron emission tomography computed tomography, positron emission tomography-computed tomography.

## FINAL DIAGNOSIS

Locally advanced ALK-positive stage IIIB-N3 NSCLC.

## TREATMENT

Based on the recommendations of multidisciplinary consultation and willingness of the patient, neoadjuvant alectinib was prescribed to induce tumor downstaging and facilitate the subsequent surgical resection. From September 17, 2019, the patient received 600 mg alectinib twice per day. After 10 wk, the patient showed a partial response (PR) at the first radiologic evaluation with the size of target lesion shrinking to 27 mm × 24 mm (Figure 1B). Routine biochemical screening detected asymptomatic elevation of liver enzymes (serum alanine aminotransferase: 118 U/L; serum aspartate aminotransferase: 71 U/L). Therefore, the patient received hepatoprotective therapy with diammonium glycyrrhizinate at a dose of 150 mg tid for two weeks, then serum liver enzymes became normal. Repeat radiological assessments conducted regularly during treatment showed constant PR. In June 2020, the size of the primary lesion had decreased to 15 mm × 10



mm (Figure 1C). A second multidisciplinary discussion yielded the following two recommendations: (1) Continuation of alectinib; or (2) suspending the usage of alectinib and receiving surgical resection. After thorough consideration, the patient opted for continuation of alectinib with close radiological surveillance. On follow-up chest CT examination in November 2020, only a slight change was found in the tumor size (12 mm × 11 mm) (Figure 1D). Compared with baseline PET-CT, the PET-CT performed at 14 mo after initiation of alectinib showed significant reduction in tumor size and uptake of 18F-fluorodeoxyglucose as well as disappearance of metastatic hypermetabolic lymph nodes (Figure 3). Owing to concerns about drug resistance, video-assisted thoracoscopic surgery was performed for left upper lobectomy with mediastinal lymph node dissection at two weeks after discontinuation of alectinib. After an uneventful postoperative course, the patient was discharged on the fifth day after operation. Histopathological examination of the surgical specimen showed no viable tumor cell, indicating pCR. Interstitial vascular and fibrous tissue hyperplasia, eosinophil infiltration, and chronic inflammation were detected in the lung tissue (Figure 2B).

## OUTCOME AND FOLLOW-UP

Postoperatively, the patient has continued to receive adjuvant alectinib till date. The recurrence-free survival as of writing this report is more than 29 mo.

## DISCUSSION

Lung cancer is one of the most common malignancies worldwide in terms of morbidity and mortality. Stage IIIB NSCLC, also known as inoperable locally advanced NSCLC, is a highly heterogeneous disease with a poor prognosis. Approximately 20% of lung cancer patients are initially diagnosed at this stage[6]. For years, concurrent chemoradiotherapy has been the standard treatment for inoperable locally advanced NSCLC. However, the prognosis remains dismal with the median progression-free survival (PFS) of 8–12 mo and the 5-year overall survival rate of 15%–25% [6]. Since ALK-TKI treatment was proven superior to chemotherapy for advanced ALK-positive NSCLC, the indications for ALK-TKI have tentatively been extended to the neoadjuvant settings[7]. This case report describes the application of neoadjuvant alectinib in a patient with ALK-positive locally advanced NSCLC (stage IIIB-N3), where the tumor was radically resected after downstaging and pCR was achieved.

ALK inhibitors have become the first-line treatment for advanced or metastatic ALK-positive NSCLC. Alectinib, a novel ALK TKI, has shown good efficacy and safety as first-line treatment in patients with advanced ALK-positive NSCLC[7–9]. The majority of available data regarding targeted drugs as neoadjuvant therapy are limited to patients with epidermal growth factor receptor (EGFR)-mutated NSCLC[10,11]. There is a paucity of evidence on the feasibility and safety of ALK inhibitors as neoadjuvant treatments in ALK-positive NSCLC patients (Table 1). Zhang *et al*[12] first reported 11 cases of pathologically confirmed N3 ALK-positive NSCLC treated with neoadjuvant crizotinib followed by surgical resection, among whom 10 patients achieved R0 resection and 2 patients achieved pCR. Zhang *et al*[13] reported a patient with ALK-positive stage IIIB NSCLC in whom tumor downstaging (to stage Ib) was achieved after two cycles of neoadjuvant alectinib; the patient subsequently underwent radical surgical resection and a partial response (PR) was achieved with a tumor shrinkage of 47%. Yue *et al*[14] reported a patient with stage IIIA ALK-positive NSCLC in whom tumor shrinkage of 42.2% was achieved after a single cycle of neoadjuvant alectinib therapy. PR was achieved without any adverse events, although the tumor stage did not downgrade and major pathologic response (MPR) was not achieved. Leonetti *et al*[15] performed a phase II multicenter study to evaluate the efficacy and safety of neoadjuvant alectinib in resectable ALK-positive NSCLC. They reported a patient with stage IIIA ALK-positive NSCLC who received two cycles of neoadjuvant alectinib followed by surgery and achieved a MPR. Recently, Hu *et al*[16] reported a case of stage IIIA resectable ALK-positive NSCLC in which pCR was achieved with neoadjuvant alectinib. In the present case, neoadjuvant alectinib was prescribed to a patient with unresectable ALK-positive stage IIIB-N3 NSCLC, and the tumor was radically resected after successful downstaging. To the best of our knowledge, this is the first reported case of unresectable ALK-positive NSCLC in which pCR was achieved after receiving alectinib as neoadjuvant therapy.

Although the incidence of pCR is very low (approximately 5%) after neoadjuvant chemotherapy in resectable NSCLC, successful downstaging and pCR were achieved in this ALK-positive stage IIIB-N3 NSCLC patient after neoadjuvant alectinib[17]. The patient continued to receive 600 mg alectinib twice daily with good medication compliance. The PFS in this case (up to 29 mo) is longer than that in previously reported cases. Some plausible explanations for this good prognosis are as follows: (1) Sufficient preoperative dosing schedule: the patient received neoadjuvant alectinib for 14 mo which was significantly longer than that in previously reported cases; (2) achievement of pCR, which is known to confer a longer survival time in NSCLC patients after neoadjuvant treatments[18]; (3) Infiltration of activated eosinophils detected in pathological specimens (Figure 2B). Studies have shown that chemokines secreted by eosinophils can induce recruitment of CD8+T cells into tumor tissues. In addition, activated eosinophils can remodel the tumor microenvironment by inducing macrophage polarization and normalizing the tumor vasculature, which ultimately promotes elimination of tumor cells[19]. Based on our experience, we speculate that alectinib targeted therapy may have induced eosinophilia and thus promoted CD8+T recruitment, which may be one of the potential mechanisms of pCR in this patient.

**Table 1 Summary of all cases of anaplastic lymphoma kinase positive patient receiving neoadjuvant alectinib therapy**

	Zhang <i>et al</i> [13]	Yue <i>et al</i> [14]	Leonetti <i>et al</i> [15]	Hu <i>et al</i> [16]	Present case
Age/gender	46/male	51/male	62/male	58/female	41/male
Symptoms	Cough and hemoptysis	None	NA	Hemoptysis	None
Smoking status	Nonsmoker	Nonsmoker	Former smoker	Nonsmoker	Nonsmoker
Location	Left lower lobe	Right upper lobe	Left upper lobe	Right lower lobe	Left upper lobe
Tumor size (cm)	6.6	3.1	NA	4.2	3.9
Baseline cTNM	cIIIB (cT3N2M0)	cIIIA (cT2N2M0)	cIIIA (cT2aN2M0)	cIIIA (cT2bN2M0)	cIIIB (cT2aN3M0)
Operable/inoperable	Inoperable	Operable	Operable	Operable	Inoperable
Cycles	2	1	2	2	14
Radiologic response	PR	PR	PR	PR	PR
Pathologic response	Non-MPR	Non-MPR	MPR	pCR	pCR
Downstaging after alectinib therapy	Yes	No	Yes	Yes	Yes
Adverse effects	Grade 1 constipation	None	None	Grade 1 constipation; Grade 1 erythema	Grade 1 abnormal liver function
Follow-up	NA	Free of disease for 6 mo	NA	Free of disease for 8 mo	Free of disease for 26 mo

NA: Not available; PR: Partial response; MPR: Major pathologic response; pCR: Pathological complete response.

## CONCLUSION

This is the first case report describing the achievement of pCR in a patient with ALK-positive stage IIIB-N3 NSCLC after neoadjuvant alectinib. This case highlights the feasibility of alectinib as neoadjuvant therapy for unresectable ALK-positive locally advanced NSCLC. Further clinical trials are warranted to confirm these findings.

## FOOTNOTES

**Author contributions:** Wang LM and Zhao P contributed to manuscript writing and editing, and data collection; Sun XQ and Yan F contributed to data analysis; Guo Q contributed to conceptualization and supervision; all authors have read and approved the final manuscript.

**Informed consent statement:** Written informed consent was obtained from the patient for publication of this report and any accompanying images.

**Conflict-of-interest statement:** The authors declare that they have no conflict of interest to disclose.

**CARE Checklist (2016) statement:** The authors have read the CARE Checklist (2016), and the manuscript has been prepared and revised according to the CARE Checklist (2016).

**Open-Access:** This article is an open-access article that was selected by an in-house editor and fully peer-reviewed by external reviewers. It is distributed in accordance with the Creative Commons Attribution NonCommercial (CC BY-NC 4.0) license, which permits others to distribute, remix, adapt, build upon this work non-commercially, and license their derivative works on different terms, provided the original work is properly cited and the use is non-commercial. See: <https://creativecommons.org/licenses/by-nc/4.0/>

**Country/Territory of origin:** China

**ORCID number:** Peng Zhao 0000-0002-5479-899X; Qian Guo 0009-0002-3119-1009.

**S-Editor:** Liu JH

**L-Editor:** A

**P-Editor:** Zhao S

## REFERENCES

- 1 **Wen M**, Wang X, Sun Y, Xia J, Fan L, Xing H, Zhang Z, Li X. Detection of EML4-ALK fusion gene and features associated with EGFR mutations in Chinese patients with non-small-cell lung cancer. *Onco Targets Ther* 2016; **9**: 1989-1995 [PMID: [27103824](#) DOI: [10.2147/OTT.S100303](#)]
- 2 **David EA**, Canter RJ, Chen Y, Cooke DT, Cress RD. Surgical Management of Advanced Non-Small Cell Lung Cancer Is Decreasing But Is Associated With Improved Survival. *Ann Thorac Surg* 2016; **102**: 1101-1109 [PMID: [27293147](#) DOI: [10.1016/j.athoracsur.2016.04.058](#)]
- 3 **Yeh J**, Marrone KA, Forde PM. Neoadjuvant and consolidation immuno-oncology therapy in stage III non-small cell lung cancer. *J Thorac Dis* 2018; **10**: S451-S459 [PMID: [29593890](#) DOI: [10.21037/jtd.2018.01.109](#)]
- 4 **Kwak EL**, Bang YJ, Camidge DR, Shaw AT, Solomon B, Maki RG, Ou SH, Dezube BJ, Jänne PA, Costa DB, Varella-Garcia M, Kim WH, Lynch TJ, Fidias P, Stubbs H, Engelman JA, Sequist LV, Tan W, Gandhi L, Mino-Kenudson M, Wei GC, Shreeve SM, Ratain MJ, Settleman J, Christensen JG, Haber DA, Wilner K, Salgia R, Shapiro GI, Clark JW, Iafrate AJ. Anaplastic lymphoma kinase inhibition in non-small-cell lung cancer. *N Engl J Med* 2010; **363**: 1693-1703 [PMID: [20979469](#) DOI: [10.1056/NEJMoa1006448](#)]
- 5 **Shaw AT**, Yeap BY, Solomon BJ, Riely GJ, Gainor J, Engelman JA, Shapiro GI, Costa DB, Ou SH, Butaney M, Salgia R, Maki RG, Varella-Garcia M, Doebele RC, Bang YJ, Kulig K, Selaru P, Tang Y, Wilner KD, Kwak EL, Clark JW, Iafrate AJ, Camidge DR. Effect of crizotinib on overall survival in patients with advanced non-small-cell lung cancer harbouring ALK gene rearrangement: a retrospective analysis. *Lancet Oncol* 2011; **12**: 1004-1012 [PMID: [21933749](#) DOI: [10.1016/S1470-2045\(11\)70232-7](#)]
- 6 **Cheema PK**, Rothenstein J, Melosky B, Brade A, Hirsh V. Perspectives on treatment advances for stage III locally advanced unresectable non-small-cell lung cancer. *Curr Oncol* 2019; **26**: 37-42 [PMID: [30853796](#) DOI: [10.3747/co.25.4096](#)]
- 7 **Hida T**, Nokihara H, Kondo M, Kim YH, Azuma K, Seto T, Takiguchi Y, Nishio M, Yoshioka H, Imamura F, Hotta K, Watanabe S, Goto K, Satouchi M, Kozuki T, Shukuya T, Nakagawa K, Mitsudomi T, Yamamoto N, Asakawa T, Asabe R, Tanaka T, Tamura T. Alectinib vs crizotinib in patients with ALK-positive non-small-cell lung cancer (J-ALEX): an open-label, randomised phase 3 trial. *Lancet* 2017; **390**: 29-39 [PMID: [28501140](#) DOI: [10.1016/S0140-6736\(17\)30565-2](#)]
- 8 **Shaw AT**, Kim DW, Nakagawa K, Seto T, Crinó L, Ahn MJ, De Pas T, Besse B, Solomon BJ, Blackhall F, Wu YL, Thomas M, O'Byrne KJ, Moro-Sibilot D, Camidge DR, Mok T, Hirsh V, Riely GJ, Iyer S, Tassell V, Polli A, Wilner KD, Jänne PA. Crizotinib vs chemotherapy in advanced ALK-positive lung cancer. *N Engl J Med* 2013; **368**: 2385-2394 [PMID: [23724913](#) DOI: [10.1056/NEJMoa1214886](#)]
- 9 **Zhou C**, Kim SW, Reungwetwattana T, Zhou J, Zhang Y, He J, Yang JJ, Cheng Y, Lee SH, Bu L, Xu T, Yang L, Wang C, Liu T, Morcos PN, Lu Y, Zhang L. Alectinib vs crizotinib in untreated Asian patients with anaplastic lymphoma kinase-positive non-small-cell lung cancer (ALESIA): a randomised phase 3 study. *Lancet Respir Med* 2019; **7**: 437-446 [PMID: [30981696](#) DOI: [10.1016/S2213-2600\(19\)30053-0](#)]
- 10 **Rizvi NA**, Rusch V, Pao W, Chaft JE, Ladanyi M, Miller VA, Krug LM, Azzoli CG, Bains M, Downey R, Flores R, Park B, Singh B, Zakowski M, Heelan RT, Shen R, Kris MG. Molecular characteristics predict clinical outcomes: prospective trial correlating response to the EGFR tyrosine kinase inhibitor gefitinib with the presence of sensitizing mutations in the tyrosine binding domain of the EGFR gene. *Clin Cancer Res* 2011; **17**: 3500-3506 [PMID: [21558399](#) DOI: [10.1158/1078-0432.CCR-10-2102](#)]
- 11 **Zhong WZ**, Chen KN, Chen C, Gu CD, Wang J, Yang XN, Mao WM, Wang Q, Qiao GB, Cheng Y, Xu L, Wang CL, Chen MW, Kang X, Yan W, Yan HH, Liao RQ, Yang JJ, Zhang XC, Zhou Q, Wu YL. Erlotinib Versus Gemcitabine Plus Cisplatin as Neoadjuvant Treatment of Stage IIIA-N2 EGFR-Mutant Non-Small-Cell Lung Cancer (EMERGING-CTONG 1103): A Randomized Phase II Study. *J Clin Oncol* 2019; **37**: 2235-2245 [PMID: [31194613](#) DOI: [10.1200/JCO.19.00075](#)]
- 12 **Zhang C**, Li SL, Nie Q, Dong S, Shao Y, Yang XN, Wu YL, Yang Y, Zhong WZ. Neoadjuvant Crizotinib in Resectable Locally Advanced Non-Small Cell Lung Cancer with ALK Rearrangement. *J Thorac Oncol* 2019; **14**: 726-731 [PMID: [30408570](#) DOI: [10.1016/j.jtho.2018.10.161](#)]
- 13 **Zhang C**, Yan LX, Jiang BY, Wu YL, Zhong WZ. Feasibility and Safety of Neoadjuvant Alectinib in a Patient With ALK-Positive Locally Advanced NSCLC. *J Thorac Oncol* 2020; **15**: e95-e99 [PMID: [32471573](#) DOI: [10.1016/j.jtho.2019.12.133](#)]
- 14 **Yue P**, Zhang S, Zhou L, Xiang J, Zhao S, Chen X, Dong L, Yang W, Xiang Y. Perioperative alectinib in a patient with locally advanced anaplastic lymphoma kinase positive non-small cell lung cancer (NSCLC): a case report. *Transl Cancer Res* 2021; **10**: 3856-3863 [PMID: [35116684](#) DOI: [10.21037/tcr-21-642](#)]
- 15 **Leonetti A**, Minari R, Boni L, Gnetti L, Verzè M, Ventura L, Musini L, Tognetto M, Tiseo M. Phase II, Open-label, Single-arm, Multicenter Study to Assess the Activity and Safety of Alectinib as Neoadjuvant Treatment in Surgically Resectable Stage III ALK-positive NSCLC: ALNEO Trial. *Clin Lung Cancer* 2021; **22**: 473-477 [PMID: [33762169](#) DOI: [10.1016/j.clcc.2021.02.014](#)]
- 16 **Hu Y**, Ren S, Wang R, Han W, Xiao P, Wang L, Yu F, Liu W. Case Report: Pathological Complete Response to Neoadjuvant Alectinib in a Patient With Resectable ALK-Positive Non-Small Cell Lung Cancer. *Front Pharmacol* 2022; **13**: 816683 [PMID: [35873553](#) DOI: [10.3389/fphar.2022.816683](#)]
- 17 **Hellmann MD**, Chaft JE, William WN Jr, Rusch V, Pisters KM, Kallhor N, Pataer A, Travis WD, Swisher SG, Kris MG; University of Texas MD Anderson Lung Cancer Collaborative Group. Pathological response after neoadjuvant chemotherapy in resectable non-small-cell lung cancers: proposal for the use of major pathological response as a surrogate endpoint. *Lancet Oncol* 2014; **15**: e42-e50 [PMID: [24384493](#) DOI: [10.1016/S1470-2045\(13\)70334-6](#)]
- 18 **Betticher DC**, Hsu Schmitz SF, Tötsch M, Hansen E, Joss C, von Briel C, Schmid RA, Pless M, Habicht J, Roth AD, Spiliopoulos A, Stahel R, Weder W, Stupp R, Egli F, Furrer M, Honegger H, Wernli M, Cerny T, Ris HB; Swiss Group for Clinical Cancer Research (SAKK). Prognostic factors affecting long-term outcomes in patients with resected stage IIIA pN2 non-small-cell lung cancer: 5-year follow-up of a phase II study. *Br J Cancer* 2006; **94**: 1099-1106 [PMID: [16622435](#) DOI: [10.1038/sj.bjc.6603075](#)]
- 19 **Carretero R**, Sektioglu IM, Garbi N, Salgado OC, Beckhove P, Hämmerling GJ. Eosinophils orchestrate cancer rejection by normalizing tumor vessels and enhancing infiltration of CD8(+) T cells. *Nat Immunol* 2015; **16**: 609-617 [PMID: [25915731](#) DOI: [10.1038/ni.3159](#)]





Published by **Baishideng Publishing Group Inc**  
7041 Koll Center Parkway, Suite 160, Pleasanton, CA 94566, USA

**Telephone:** +1-925-3991568

**E-mail:** [bpgoffice@wjgnet.com](mailto:bpgoffice@wjgnet.com)

**Help Desk:** <https://www.f6publishing.com/helpdesk>

<https://www.wjgnet.com>

