



## Preserving finger length in a patient with symmetric digital gangrene under local anesthesia: A case report

Keun Hyung Kim, In Chang Ko, Hoon Kim, Soo Yeon Lim

**Specialty type:** Surgery

**Provenance and peer review:**

Unsolicited article; Externally peer reviewed.

**Peer-review model:** Single blind

**Peer-review report's scientific quality classification**

Grade A (Excellent): A

Grade B (Very good): 0

Grade C (Good): C

Grade D (Fair): 0

Grade E (Poor): 0

**P-Reviewer:** Glumac S, Croatia; Li Z, China

**Received:** July 5, 2023

**Peer-review started:** July 5, 2023

**First decision:** July 28, 2023

**Revised:** August 9, 2023

**Accepted:** August 31, 2023

**Article in press:** August 31, 2023

**Published online:** September 26, 2023



**Keun Hyung Kim, In Chang Ko, Hoon Kim,** Department of Plastic and Reconstructive Surgery, Konyang University Medical Center, Konyang University of College of Medicine, Daejeon 35365, South Korea

**Soo Yeon Lim,** Department of Plastic and Reconstructive Surgery, Konyang University Hospital, Konyang University of College of Medicine, Myunggok Medical Research Center, Daejeon 35365, South Korea

**Corresponding author:** Soo Yeon Lim, MD, Assistant Professor, Department of Plastic and Reconstructive Surgery, Konyang University Hospital, Konyang University of College of Medicine, Myunggok Medical Research Center, 685 Gasuwon-dong seo-gu, Daejeon 35365, South Korea. [lscan84@gmail.com](mailto:lscan84@gmail.com)

### Abstract

#### BACKGROUND

Case reports of symmetric digital gangrene resulting from high-dose vasopressors use in patients with alcoholic ketoacidosis, leading to cardiac arrest, are rare. To date, no specific treatment method for autolysis or surgical amputation or guidelines for determining the level of amputation have been established.

#### CASE SUMMARY

In this case report, we describe a treatment method that effectively preserved the function of fingers by surgical treatment under local anesthesia with a minimum operative time, while also preserving finger length to the maximum possible extent.

#### CONCLUSION

Our approach may contribute to improved postoperative quality of life by preserving finger length.

**Key Words:** Acidosis; Disseminated intravascular coagulation; Ketosis; Purpura fulminans; Surgical amputation; Case report

©The Author(s) 2023. Published by Baishideng Publishing Group Inc. All rights reserved.

**Core Tip:** In cases of symmetric digital gangrene, wherein multiple comorbidities exist, autolytic treatment is often considered. However, appropriate management *via* amputation under local anesthesia can aid in the patient's recovery.

**Citation:** Kim KH, Ko IC, Kim H, Lim SY. Preserving finger length in a patient with symmetric digital gangrene under local anesthesia: A case report. *World J Clin Cases* 2023; 11(27): 6640-6645

**URL:** <https://www.wjgnet.com/2307-8960/full/v11/i27/6640.htm>

**DOI:** <https://dx.doi.org/10.12998/wjcc.v11.i27.6640>

## INTRODUCTION

Acute necrosis of the distal limbs is associated with various etiological factors. However, symmetric digital gangrene (SDG), characterized by palpable peripheral blood flow and absence of occlusive disease in the major blood vessels, manifests with unique etiological factors, including vasculitis, autoimmune disease, frostbite, burns, and abnormal blood flow[1]. SDG can primarily occur accompanied by comorbidities such as disseminated intravascular coagulation (DIC) or low cardiac output. Moreover, it represents a significant medical concern owing to its high mortality rate. Although the treatment of SDG lacks a concrete foundation, the consensus among experts is to thoroughly assess the level of demarcation and subsequently excise necrotic tissue. In this report, we present a case of successful management of SDG in which favorable outcomes were achieved through a short-duration surgical approach performed under local anesthesia.

## CASE PRESENTATION

### Chief complaints

A 62-year-old man developed purpuric lesions on his fingertips during the use of vasopressors after hospitalization.

### History of present illness

The patient had been experiencing mental confusion due to consuming only alcohol for approximately 8 days without ingesting any food or medication. Initial evaluation revealed that the patient was drowsy with an undetectable pulse. Successful cardiopulmonary resuscitation was performed for 4 min, and return of spontaneous circulation (ROSC) was achieved. Thereafter, the patient developed a purpuric rash on both upper extremities.

### History of past illness

The patient had experienced repeated relapses and exacerbations of alcohol addiction over a period of 30 years.

### Personal and family history

The patient not only had diabetes mellitus and hypertension but was also a chronic alcoholic with alcoholic fatty liver disease.

### Physical examination

Initial evaluation revealed that the patient was drowsy with an undetectable pulse. Successful cardiopulmonary resuscitation was performed for 4 min, achieving ROSC.

### Laboratory examinations

Laboratory test results revealed ketone bodies level, 3631  $\mu\text{mol/L}$ ; severe acidosis (pH 6.792); lactate level,  $> 20 \text{ mmol/L}$ ; and pre-renal acute kidney injury (blood urea nitrogen, 33.5  $\text{mg/dL}$ ; creatinine, 2.63  $\text{mg/dL}$ ) without urine output. The patient received intravenous fluids and continuous renal replacement therapy. One day after hospitalization, the following blood test results were shown: Platelet count, 53000/ $\mu\text{L}$  (decreased); prothrombin time (PT), 21.9 s (increased); international normalized ratio (INR), 1.9 (increased); activated partial thromboplastin time (aPTT), 89.2 s (increased); and D-dimer level, 16.19  $\mu\text{g/mL}$  (increased).

### Imaging examinations

Doppler ultrasound examination of the radial and ulnar arteries in both upper extremities was performed, focusing on the digits. The examination was performed using biphasic sound, by which no evidence of stenosis or obstruction was observed.

## FINAL DIAGNOSIS

Combined diabetic and alcoholic ketoacidosis led to cardiopulmonary arrest and DIC and vasopressor-induced symmetrical peripheral gangrene.

## TREATMENT

Our nephrologist recommended the administration of inotropes to manage persistent hypotension and decreased pulse rate. Consequently, norepinephrine (NE; 40 µg/min), dopamine (20 µg/kg/min), and vasopressin (0.04 U/min) were administered to maintain blood pressure and pulse rate within normal range. On the first day after hospitalization, the radial pulse became palpable. However, gangrene developed in both hands and feet. Blood tests revealed platelet count, 53,000/µL (decreased); PT, 21.9 s (increased); INR, 1.9 (increased); aPTT, 89.2 s (increased); and D-dimer level, 16.19 µg/mL (increased); indicating the onset of DIC and necrosis in the extremities due to the complex interplay between these factors.

Initially, we decided to monitor the patient until demarcation of the lesions could be observed. Treatment was initiated with intravenous prostaglandin E1 (PGE1) analog, dressings, and antibiotics. The dosage of catecholamines was gradually reduced to the minimum required to stabilize the vital signs. However, it was completely discontinued on day nine after hospitalization. By the first month of hospitalization, the patient experienced relief from the pain and tenderness. In addition, demarcations became visible as the mummified tissue and skin inflammation at the border subsided. Subsequently, the amputation levels were determined while maximizing finger length with the patient's consent.

The demarcated areas near the distal interphalangeal joint of the right third finger and left first and fourth fingers were disarticulated (Figure 1). To preserve finger length, the remaining fingers were amputated only up to the demarcation of the necrotic area. V-Y island flaps were created from the volar sides of the third to fifth fingers and the first left finger to cover the resulting defects, all within 1 cm (Figure 2). Considering the risks associated with general anesthesia after cardiac arrest, all surgical procedures were performed under local anesthesia using a digital nerve block (1 mL of 2% lidocaine was used per area). Postoperatively, PGE1 and antibiotics were administered intravenously to stabilize the wounds.

## OUTCOME AND FOLLOW-UP

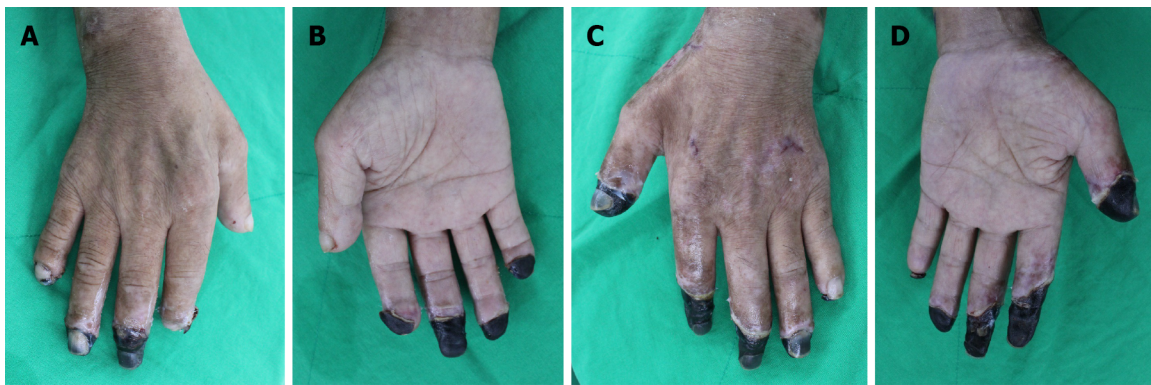
Subsequently, the wounds were managed with wet dressings, wherein complete healing was achieved one month after surgery without any complications. At the one-year follow-up, functional recovery was observed, and the patient reported no inconvenience in performing daily activities such as writing or using chopsticks (Figure 3). The patient recommenced his daily life activities without any relapse of alcohol addiction while receiving treatment at an alcohol rehabilitation facility.

## DISCUSSION

SDG in the distal extremities was first reported by Hutchinson[2] in 1891. It primarily affects the periphery and is typically not associated with occlusion of the major blood vessels. Given its association with DIC in over 85% of cases, SDG has a relatively high mortality rate[3]. However, to the best of our knowledge, none of the known causes of SDG were associated with alcoholic ketoacidosis. Therefore, we present an approach to treating SDG associated with alcoholic ketoacidosis, which is a rare condition. Alcoholic ketoacidosis leads to hypovolemia and increased serum lactate levels, resulting in severe metabolic acidosis and an electrolyte imbalance. These conditions could trigger cardiac arrhythmias and sudden cardiac arrest[4]. Additionally, uncontrolled diabetes and the post-cardiopulmonary resuscitation state in our patient contributed to the prothrombotic condition, further exacerbating DIC progression[5]. Moreover, persistence of acidosis could induce intracellular oxidative stress, leading to cellular injury and the establishment of a cycle of deteriorating acidosis and tissue damage[6].

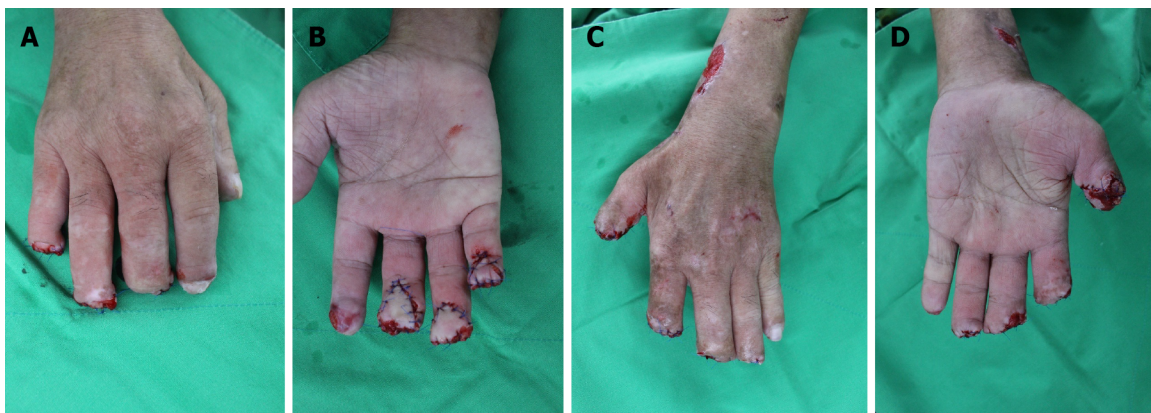Furthermore, vasopressors, specifically NE, were necessary after cardiac arrest, and a combination of these factors contributed to the development of SDG in this case. According to several studies, NE doses exceeding 1.23-22 µg/kg/min should be avoided. Dopamine doses ranging between 5.1 and 10.2 µg/kg/min may lead to gangrene in patients with DIC and hypovolemic conditions. Even low-dose vasopressors could contribute to limb necrosis in the context of DIC[6]. Given these conditions, SDG could be considered a potential complication associated with the general use of vasopressors, as most of these conditions could trigger DIC.

One limitation of our report is that computed tomography (CT) angiography was required for accurate confirmation of symmetrical peripheral gangrene and assessing the status of major blood vessels. However, owing to the consideration of acute kidney injury and the potential risk of additional renal damage, we did perform CT angiography. Instead, we performed Doppler ultrasonography, which allowed us to confirm the absence of any signs of stenosis or occlusion of the major blood vessels.



DOI: 10.12998/wjcc.v11.i27.6640 Copyright ©The Author(s) 2023.

**Figure 1** The final demarcation of the lesions before planning the surgery is shown. A: Right hand dorsal aspect; B: Right hand palmar aspect; C: Left hand dorsal aspect; D: Left hand palmar aspect.



DOI: 10.12998/wjcc.v11.i27.6640 Copyright ©The Author(s) 2023.

**Figure 2** The third, fourth, and fifth fingers on the right hand, and the first on the left hand, which do not have adequate soft tissue, are closed using V-Y flaps. A: Right hand dorsal aspect; B: Right hand palmar aspect; C: Left hand dorsal aspect; D: Left hand palmar aspect.

Currently, there is no standard treatment of SDG. Some studies have reported the use of epoprostenol and tissue plasminogen activator infusion to manage concomitant DIC. Other reported treatments include sympathetic blockade, plasmapheresis, leukapheresis, and antibiotic administration. Aspirin has also been reported as a potential therapeutic option. Fresh frozen plasma transfusion and anticoagulation therapy may be beneficial when necessary. However, previous studies have revealed conflicting results regarding the effectiveness of anticoagulants and antiplatelet agents[1, 3,7,8]. In cases similar to ours, addressing the underlying cause is crucial, such as DIC, before considering autolysis or amputation based on demarcation following general gangrene treatment, depending on the depth. Autolysis induction is a prolonged treatment that causes continuous pain, leading to a reduced quality of life and patient satisfaction[9].

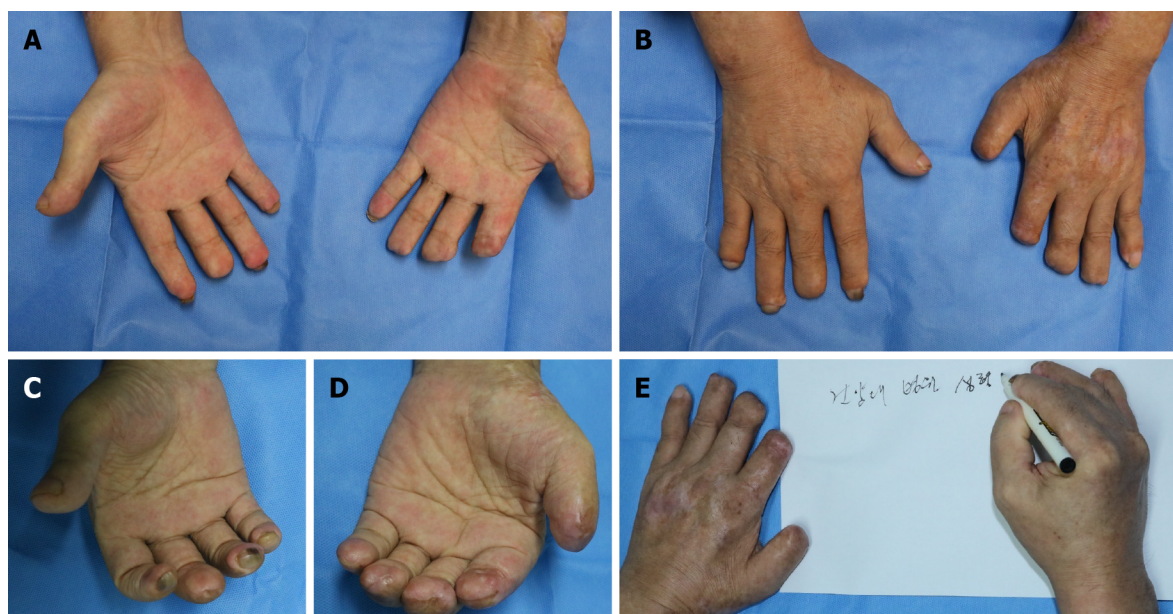
In this case, despite the patient's recovery in terms of vital signs and mental state, the defected state of the extremities of both fingers prevented the patient from performing daily activities independently and posed a risk of infection. Consequently, surgical intervention was deemed necessary. Our surgical approach aimed to maximize finger length. All procedures were performed under local anesthesia, considering the patient's general condition, and were completed within approximately 2 h. Amputations were performed according to the demarcation levels. The skin and soft tissues were debrided to the border of necrosis, where spot bleeding was observed. To minimize postoperative discomfort, the cross-section of the cut bone was trimmed and restored. All defect sites were within 1 cm of the amputation site. After the resection, V-Y island flaps with a pedicle at the distal end of the proper artery were created from the volar side of the third to fifth fingers and the left first finger to restore the bony surface[10].

No significant discomfort was reported in performing daily activities, and no specific complications occurred even after one year. Because this case report focused on a single patient, the generalizability of the findings may be limited. A more robust and widely applicable conclusion can be reached in future large-scale studies.

## CONCLUSION

Considering the multifactorial etiology of SDG, addressing the underlying cause is crucial. In this case, our focus was on





DOI: 10.12998/wjcc.v11.i27.6640 Copyright ©The Author(s) 2023.

**Figure 3** During the follow-up, one year after surgery, all wounds are healed, with no functional issues with the fingers. A: The palmar aspects of both hands; B: The dorsal aspects of both hands; C: The healed amputation wounds on the right hand; D: The healed amputation wounds on the left hand; E: There are no significant issues in handwriting and the activities of daily life.

recovery from conditions induced by alcoholic ketoacidosis by reducing and discontinuing the use of catecholamines at the earliest opportunity. Our approach may contribute to improved postoperative quality of life by preserving finger length.

## FOOTNOTES

**Author contributions:** Kim KH substantially contributed to the conception and design of the study, acquisition of data, or analysis and interpretation of data; Ko IC made critical revisions related to the important intellectual content of the manuscript; Kim H made critical revisions related to the important intellectual content of the manuscript; Lim SY contributed to the conception and design of the study, drafting of the article, and provided final approval of the version of the article to be published.

**Informed consent statement:** The patient provided informed consent for the publication of this report. This report was approved by Konyang University Hospital's Institutional Review Board (No. 2022-10-013).

**Conflict-of-interest statement:** The authors declare that they have no conflicts of interest.

**CARE Checklist (2016) statement:** The authors have read the CARE Checklist (2016), and the manuscript was prepared and revised according to the CARE Checklist (2016).

**Open-Access:** This article is an open-access article that was selected by an in-house editor and fully peer-reviewed by external reviewers. It is distributed in accordance with the Creative Commons Attribution NonCommercial (CC BY-NC 4.0) license, which permits others to distribute, remix, adapt, build upon this work non-commercially, and license their derivative works on different terms, provided the original work is properly cited and the use is non-commercial. See: <https://creativecommons.org/licenses/by-nc/4.0/>

**Country/Territory of origin:** South Korea

**ORCID number:** Keun Hyung Kim 0000-0003-3895-9850; In chang Ko 0000-0002-5902-5670; Hoon Kim 0000-0003-1261-9743; Soo Yeon Lim 0000-0002-2954-2191.

**S-Editor:** Yan JP

**L-Editor:** A

**P-Editor:** Yan JP

## REFERENCES

- 1 **Reyes AJ**, Ramcharan K, Harnarayan P, Mooteeram J. Symmetrical digital gangrene after a high dose intravenous infusion of epinephrine and dopamine following resuscitation from cardiac arrest. *BMJ Case Rep* 2016; **2016** [PMID: 27879306 DOI: 10.1136/bcr-2016-217977]
- 2 **Hutchinson J**. Severe symmetrical gangrene of the extremities. *Br Med J* 1891; **2**: 8-9
- 3 **Liao CY**, Huang SC, Lin CH, Wang CC, Liu MY, Ben RJ, Kuo WH, Lee CC. Successful resolution of symmetrical peripheral gangrene after severe acute pancreatitis: a case report. *J Med Case Rep* 2015; **9**: 213 [PMID: 26376919 DOI: 10.1186/s13256-015-0688-3]
- 4 **Long B**, Lentz S, Gottlieb M. Alcoholic Ketoacidosis: Etiologies, Evaluation, and Management. *J Emerg Med* 2021; **61**: 658-665 [PMID: 34711442 DOI: 10.1016/j.jemermed.2021.09.007]
- 5 **Grant PJ**. Diabetes mellitus as a prothrombotic condition. *J Intern Med* 2007; **262**: 157-172 [PMID: 17645584 DOI: 10.1111/j.1365-2796.2007.01824.x]
- 6 **Yazıcı MU**, Ayar G, Savas-Erdeve S, Azapağası E, Neşelioğlu S, Erel Ö, Çetinkaya S. Role of Ischemia Modified Albumin Serum Levels as an Oxidative Stress Marker in Children with Diabetic Ketoacidosis. *Comb Chem High Throughput Screen* 2019; **22**: 577-581 [PMID: 31595845 DOI: 10.2174/1386207322666191008214919]
- 7 **Kwon JW**, Hong MK, Park BY. Risk Factors of Vasopressor-Induced Symmetrical Peripheral Gangrene. *Ann Plast Surg* 2018; **80**: 622-627 [PMID: 29319574 DOI: 10.1097/SAP.0000000000001314]
- 8 **Jung KJ**, Nho JH, Cho HK, Hong S, Won SH, Chun DI, Kim B. Amputation of multiple limbs caused by use of inotropics: Case report, a report of 4 cases. *Medicine (Baltimore)* 2018; **97**: e9800 [PMID: 29384879 DOI: 10.1097/MD.0000000000009800]
- 9 **Al Wahbi A**. Operative versus non-operative treatment in diabetic dry toe gangrene. *Diabetes Metab Syndr* 2019; **13**: 959-963 [PMID: 31336551 DOI: 10.1016/j.dsx.2018.12.021]
- 10 **Lemmon JA**, Janis JE, Rohrich RJ. Soft-tissue injuries of the fingertip: methods of evaluation and treatment. An algorithmic approach. *Plast Reconstr Surg* 2008; **122**: 105e-117e [PMID: 18766028 DOI: 10.1097/PRS.0b013e3181823be0]



Published by **Baishideng Publishing Group Inc**  
7041 Koll Center Parkway, Suite 160, Pleasanton, CA 94566, USA

**Telephone:** +1-925-3991568

**E-mail:** [bpgoffice@wjgnet.com](mailto:bpgoffice@wjgnet.com)

**Help Desk:** <https://www.f6publishing.com/helpdesk>

<https://www.wjgnet.com>

