



Post-laparotomy heterotopic ossification of the xiphoid process: A case report

Seung Soo Lee

Specialty type: Medicine, research and experimental

Provenance and peer review: Unsolicited article; Externally peer reviewed.

Peer-review model: Single blind

Peer-review report's scientific quality classification

Grade A (Excellent): 0
Grade B (Very good): 0
Grade C (Good): 0
Grade D (Fair): 0
Grade E (Poor): 0

P-Reviewer: Augustin G, Croatia

Received: October 16, 2023

Peer-review started: October 16, 2023

First decision: November 21, 2023

Revised: November 24, 2023

Accepted: December 13, 2023

Article in press: December 13, 2023

Published online: December 26, 2023



Seung Soo Lee, Department of Surgery, Kyungpook National University Hospital, Daegu 41944, South Korea

Seung Soo Lee, Department of Surgery, School of Medicine, Kyungpook National University, Daegu 41944, South Korea

Corresponding author: Seung Soo Lee, MD, PhD, Associate Professor, Surgical Oncologist, Department of Surgery, Kyungpook National University Hospital, 130 Dongdeok-ro, Jung-gu, Daegu 41944, South Korea. peterleess@knu.ac.kr

Abstract

BACKGROUND

Heterotopic ossification (HO) represents all types of extraskeletal ossification in the body. It occurs in various areas, including the skin, subcutaneous tissue, muscle, and joints. Surgical excision is recommended for symptomatic HO. Postoperative radiotherapy, oral nonsteroidal anti-inflammatory drugs, and topical sealants, such as bone wax, have been recommended as preventive measures. As HO is rare in occurrence, these recommendations are based on personal experiences, and there is a lack of information on individualized treatments depending on its location.

CASE SUMMARY

A 62-year-old male was admitted for symptomatic HO along a laparotomy scar. Surgical excision was performed for an 11 cm-sized ossification originating from the xiphoid process, and bone wax was applied to the excisional margin. However, the surgical wound failed to heal. After several weeks of saline-soaked gauze dressing, delayed wound closure was performed. The patient was finally discharged eight weeks after the excision. Because HO can occur in various areas of the body, a treatment strategy that may be effective for some may not be for others. Bone wax has been used as a topical sealant over excisional margins in the shoulder, elbow, and temporomandibular joints. However, in our case, its application on an abdominal surgical wound delayed its primary healing intention. The valuable lesson was that, when choosing a treatment method for HO based on available research data, its location must be considered.

CONCLUSION

Complete excision should be the priority treatment option for symptomatic HO along the laparotomy scar. Bone wax application is not recommended.

Key Words: Heterotopic ossification; Joints; Laparotomy; Waxes; Wound healing; Case report

©The Author(s) 2023. Published by Baishideng Publishing Group Inc. All rights reserved.

Core Tip: Heterotopic ossification (HO) represents all types of extraskeletal ossification, and occurs in various areas, including the skin, muscle, and joints. There are some suggested treatment and preventive approaches for symptomatic HO, which include surgical excision and preventive measures such as postoperative radiotherapy, oral nonsteroidal anti-inflammatory drugs, and topical sealants (bone wax). However, these recommendations are based on personal experiences limited to HO in certain locations. It is important to individualize our treatment approaches depending on its location. For symptomatic HO along the laparotomy scar, complete surgical excision should be the priority treatment option, and bone wax application is not recommended.

Citation: Lee SS. Post-laparotomy heterotopic ossification of the xiphoid process: A case report. *World J Clin Cases* 2023; 11(36): 8568-8573

URL: <https://www.wjgnet.com/2307-8960/full/v11/i36/8568.htm>

DOI: <https://dx.doi.org/10.12998/wjcc.v11.i36.8568>

INTRODUCTION

Heterotopic ossification (HO) refers to the formation of trabecular bone outside the usual skeletal system[1,2]. Therefore, all extraskeletal bone formation in various areas of the body, including the skin, subcutaneous tissue, muscle, joints, and mesentery are included in this uncommon clinical entity[3,4]. As much as it covers all extraskeletal bone formation throughout the body, a wide range of factors contribute to each occurrence. Some of the most mentioned associated factors are trauma, burns, arthroplasty, and abdominal surgery[1,5]. As HO is highly associated with an external insult, the concern is higher in military settings where a high incidence of HO in combat-injured patients has been reported[2].

HO has been reported in various sites of the human body, and some hypotheses have been presented for its pathogenesis[6]. The generally recommended treatment for symptomatic HO has been selective surgical excision[2,7]. Some cases have been treated with open resection[8,9], and others, especially cases of HO in the joints, have been treated with arthroscopy[1]. Regardless of the HO site, recurrence has always been a concern for surgeons, and some preventive measures, such as postoperative radiotherapy[10], oral nonsteroidal anti-inflammatory drugs (NSAIDs)[11], and topical sealant (bone wax) over the osteotomy plane[1,7,12], have been recommended.

We experienced a case of symptomatic HO along a laparotomy scar following gastrectomy for gastric cancer. To search for the best treatment options, we vigorously reviewed the previous reports that were available at the time. While realizing that HO is a collective term representing all types of extraskeletal ossifications, we found a lack of information stating the need for individualizing our treatment efforts depending on the HO location. Our choice of treatment, which was a combination of surgical excision and the application of bone wax, did not turn out to be the best option.

CASE PRESENTATION

Chief complaints

A 62-year-old Asian man complained of persistent difficulties in bending his waist forward for six months.

History of present illness

The patient underwent a curative surgery for gastric cancer about a year earlier and had been making routine visits to our outpatient department for regular surveillance. After the gastrectomy, he continued to display a tendency toward excessive anxiety about his health. He kept complaining about memory loss, hair loss, and constipation, which were somewhat different from the usual postgastrectomy complaints, such as diarrhea, nausea, vomiting, and other gastrointestinal symptoms. Four months after the gastrectomy, he started complaining of stiffness along the surgical scar but received little medical attention at the time. The symptoms worsened over the next two months, and the patient started experiencing difficulties in bending his waist forward. The patient had a normal weight (62.7 kg) and body mass index (20.9 kg/m²). Postgastrectomy weight loss was minimal (weight loss of 1.3 kg). There were no signs of cancer recurrence.

History of past illness

The patient underwent distal subtotal gastrectomy, D2 lymphadenectomy, and Billroth II anastomosis for gastric cancer a year earlier. He did not undergo adjuvant chemotherapy as the surgical specimen confirmed stage I cancer according to the 8th edition of the Union for International Cancer Control classification. The patient had no history of smoking, alcohol

abuse, or previous illnesses except for well-controlled hypertension and type 2 diabetes.

Personal and family history

The patient had no significant personal or family history.

Physical examination

The vital signs were unremarkable. Abdominal physical examination revealed no distension or rigidity. Bowel sound was normal. There was a firm, fixed palpable mass along the surgical incision that was about 10 cm in size. There was no pain or tenderness.

Laboratory examinations

Routine blood and urine analysis results were normal. Serum tumor markers including carcinoembryonic antigen and carbohydrate antigen 19-9 were normal with 3.4 ng/mL and 21.4 U/mL, respectively.

Imaging examinations

An abdominal computerized tomography (CT), taken for 6-mo postgastrectomy surveillance, revealed a 10 cm-sized ossification along the surgical incision (Figure 1). The latest CT, taken for 1-year postgastrectomy surveillance just before the admission, confirmed an 11 cm-sized ossification along the surgical incision.

FINAL DIAGNOSIS

Based on the patient's medical history, physical examination, and CT findings, the final diagnosis was HO, originating from the xiphoid process.

TREATMENT

Surgery for symptomatic HO was performed under general anesthesia. At laparotomy, an 11 cm-sized ossification, originating from the xiphoid process, was noticed between the linea alba and preperitoneal adipose layer (Figure 2). The structure was densely adhered to the surrounding tissue. After careful dissection of the adhered tissue and separation of the bony attachment at the xiphoidal end, we completely removed the structure. As an extra precaution for bone hemostasis and HO recurrence, bone wax was applied to the excisional margin. The surgical wound was closed layer by layer.

OUTCOME AND FOLLOW-UP

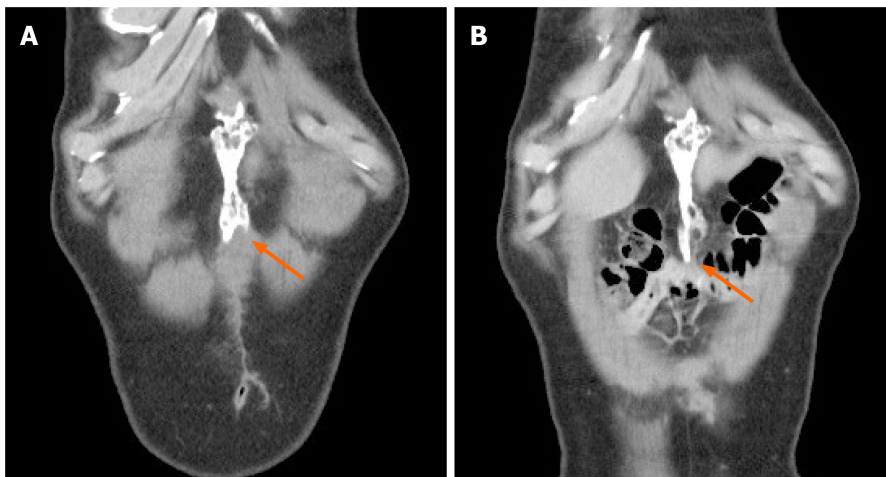
Histological examination of the surgical specimen confirmed HO. However, there was extensive discharge from the surgical wound over the following two weeks. The nature of the discharge slowly changed from serous to turbid, and we decided to open the surgical wound. The wound was somewhat waxy, and massive wound irrigation was performed. After three weeks of applying saline-soaked gauze dressings, delayed wound closure was performed, and the patient was finally discharged eight weeks after the HO excision. He underwent a follow-up CT two years postgastrectomy, which was about a year after the HO excision, and there were no signs of recurrence (Figure 3).

DISCUSSION

HO is rare and, yet, broad in that it represents all types of extraskeletal ossifications in the body. Therefore, depending on its location, a treatment strategy that may be effective for some may not be for others. An extensive literature search led us to the application of bone wax along the laparotomy scar following surgical HO excision. However, this turned out to be a grave misapplication of our treatment efforts.

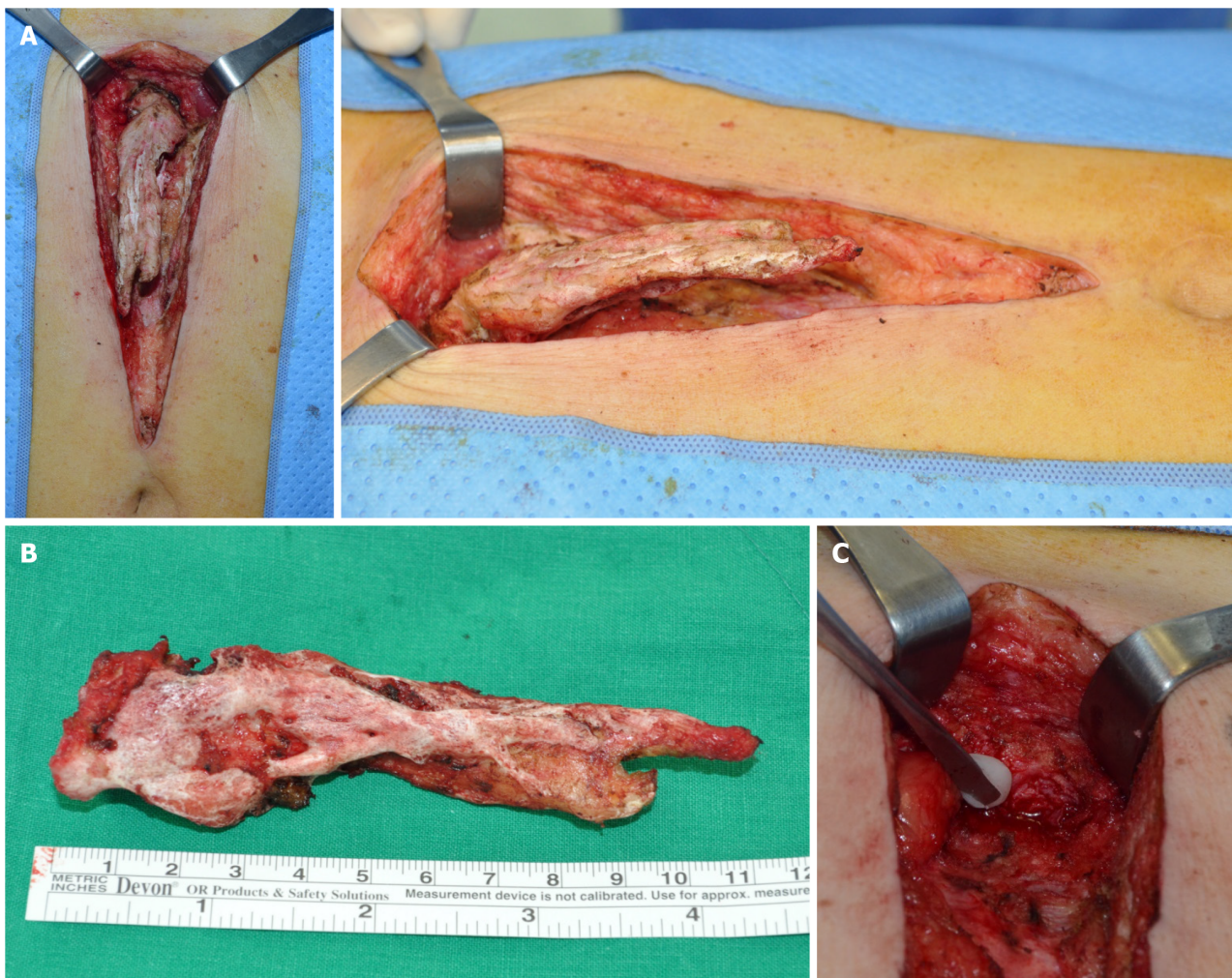
Two pathogenesis hypotheses for the HO of abdominal scar tissue have been suggested[6]. The first and more favored hypothesis is an aberrant inflammatory process in wound healing, leading to the differentiation of mesenchymal stromal cells into osteoblasts. This is highly favored in those with HO located at a distance from the adjacent bone. The second hypothesis emphasizes the iatrogenic spillage of periosteal cells from the adjacent bone during surgery. In our case, HO was connected with the xiphoid process, and we could not exclude the possibility of the iatrogenic spillage of periosteal cells from the xiphoid process.

Whatever the pathogenesis hypothesis, surgical excision has been recommended for symptomatic HO. Our literature search delved deeper into HO prevention. The search returned some recommendations for preventing HO recurrence, and bone wax was one of them. Bone wax is a nonabsorbable substance composed of beeswax and petroleum jelly, and has been used to achieve hemostasis after bone resection[13]. While it functions as a mechanical barrier to stop bleeding, using it to suppress bone formation in the resection surface has also been reported[14]. Despite concerns about a chronic



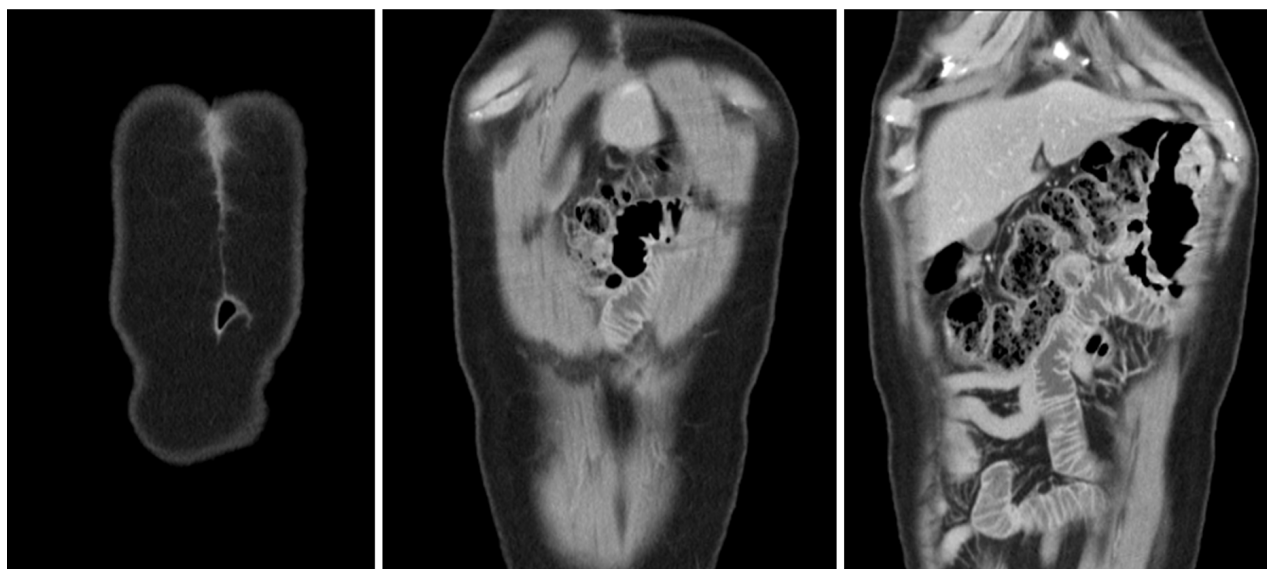
DOI: 10.12998/wjcc.v11.i36.8568 Copyright ©The Author(s) 2023.

Figure 1 Computerized tomography images showing heterotopic ossification (arrow). A: A 10 cm-sized ossification was located along the laparotomy scar six months after surgery; B: A slight increase in size was observed one year after surgery.



DOI: 10.12998/wjcc.v11.i36.8568 Copyright ©The Author(s) 2023.

Figure 2 Excision of heterotopic ossification. A: The structure originated from the xiphoid process, extending inferiorly along the midline of the abdomen; B: The 11 cm-sized ossification was excised completely; C: Bone wax was applied to the excisional margin.



DOI: 10.12998/wjcc.v11.i36.8568 Copyright ©The Author(s) 2023.

Figure 3 An abdominal computerized tomographic scan, taken one year after excision, showing no sign of recurred heterotopic ossification.

inflammatory reaction following the intraarticular use of bone wax[15], bone wax has been used as a topical sealant to prevent HO in shoulders[1], temporomandibular joints[7], and elbows[12].

Besides bone wax, postoperative radiotherapy and oral NSAIDs have been recommended as feasible preventive measures for HO[10,11]. However, we chose none of these because they are highly associated with gastrointestinal symptoms[16,17]. Gastric cancer survivors are known to experience gastrointestinal symptoms for years after surgery[18]. Our patient underwent distal subtotal gastrectomy a year earlier and was not free of gastrointestinal symptoms. Therefore, the clinical application of either radiotherapy or oral NSAIDs would have exacerbated postgastrectomy symptoms.

After much deliberation, we decided to use bone wax. Unfortunately, the outcome was an eight-week-long hospital stay and additional surgery for delayed wound closure. The application of bone wax on the abdominal surgical wound delayed its primary healing intention. A previous study reported the clinical use of bone wax in dermatologic surgery by exploiting such a distinguishing trait[19]. Bone wax has been used to cover deep tissue defects and create an ideal occlusive environment for secondary healing intention. In our case, our efforts to prevent HO recurrence left the surgical wound in a condition that was suitable only for secondary healing intention.

Complete excision may be a sufficient management strategy for HO along a laparotomy scar. We eventually made huge efforts to remove the bone wax as much as possible by massive wound irrigation and repeated cleansing with wet gauze, and there was no sign of recurrence after a year. Nevertheless, uncertainty regarding the remaining bone wax and its implication on HO prevention is a limitation of this finding. The strength would be sharing the valuable lesson that we need to be very careful about choosing a treatment method for HO using available research data and treatment should be individualized depending on the HO location. Previous reports suggesting the beneficial effect of bone wax against HO recurrence have focused on HO in joints[1,7,12]. Our effort of applying bone wax to an abdominal wound could have failed because we did not realize the distinction in treatment between different areas.

CONCLUSION

In conclusion, HO represents all types of extraskeletal ossifications in the body, and treatment approaches must be individualized depending on the surroundings. Complete surgical excision should be the priority treatment option for HO along a laparotomy scar, and the application of bone wax is not recommended.

FOOTNOTES

Author contributions: Lee SS contributed to conceptualization, design of the study, acquisition and analysis of data, drafting and revising the manuscript, and final approval of the version to be submitted.

Informed consent statement: The patient provided informed written consent prior to study enrollment.

Conflict-of-interest statement: All the authors report no relevant conflicts of interest for this article.

CARE Checklist (2016) statement: The authors have read the CARE Checklist (2016), and the manuscript was prepared and revised according to the CARE Checklist (2016).

Open-Access: This article is an open-access article that was selected by an in-house editor and fully peer-reviewed by external reviewers. It is distributed in accordance with the Creative Commons Attribution NonCommercial (CC BY-NC 4.0) license, which permits others to distribute, remix, adapt, build upon this work non-commercially, and license their derivative works on different terms, provided the original work is properly cited and the use is non-commercial. See: <https://creativecommons.org/licenses/by-nc/4.0/>

Country/Territory of origin: South Korea

ORCID number: Seung Soo Lee 0000-0003-4398-6300.

S-Editor: Wang JJ

L-Editor: A

P-Editor: Zhao S

REFERENCES

- 1 Hallock J, Field LD. Surgical Management of Shoulder Heterotopic Ossification. *Arthrosc Tech* 2019; **8**: e1057-e1062 [PMID: 31737484 DOI: 10.1016/j.eats.2019.05.019]
- 2 Edwards DS, Kuhn KM, Potter BK, Forsberg JA. Heterotopic Ossification: A Review of Current Understanding, Treatment, and Future. *J Orthop Trauma* 2016; **30** Suppl 3: S27-S30 [PMID: 27661424 DOI: 10.1097/BOT.0000000000000666]
- 3 Hogan NM, Caffrey E, Curran S, Sheehan M, Joyce MR. Heterotopic ossification of the abdominal wall. *Int J Surg Case Rep* 2012; **3**: 489-491 [PMID: 22858788 DOI: 10.1016/j.ijscr.2012.06.004]
- 4 Hakim M, McCarthy EF. Heterotopic mesenteric ossification. *AJR Am J Roentgenol* 2001; **176**: 260-261 [PMID: 11133585 DOI: 10.2214/ajr.176.1.1760260]
- 5 Brady RD, Shultz SR, McDonald SJ, O'Brien TJ. Neurological heterotopic ossification: Current understanding and future directions. *Bone* 2018; **109**: 35-42 [PMID: 28526267 DOI: 10.1016/j.bone.2017.05.015]
- 6 Fennema EM, de Boer J, Mastboom WJ. Ossification of abdominal scar tissue: a case series with a translational review on its development. *Hernia* 2014; **18**: 825-830 [PMID: 24668529 DOI: 10.1007/s10029-014-1240-x]
- 7 Ding R, Lu C, Zhao J, He D. Heterotopic ossification after alloplastic temporomandibular joint replacement: a case cohort study. *BMC Musculoskelet Disord* 2022; **23**: 638 [PMID: 35787680 DOI: 10.1186/s12891-022-05582-5]
- 8 Hong SP, Lee JB, Bae CH. Heterotopic Ossification of the Xiphoid Process after Abdominal Surgery for Traumatic Hemoperitoneum. *J Korean Med Sci* 2018; **33**: e62 [PMID: 29359542 DOI: 10.3346/jkms.2018.33.e62]
- 9 Tytherleigh-Strong G, Gill J, Sforza G, Copeland S, Levy O. Reossification and fusion across the acromioclavicular joint after arthroscopic acromioplasty and distal clavicle resection. *Arthroscopy* 2001; **17**: E36 [PMID: 11694940 DOI: 10.1053/jars.2001.26861]
- 10 Jensen AW, Viozzi CF, Foote RL. Long-term results of radiation prophylaxis for heterotopic ossification in the temporomandibular joint. *J Oral Maxillofac Surg* 2010; **68**: 1100-1105 [PMID: 20185221 DOI: 10.1016/j.joms.2009.12.018]
- 11 Naylor BH, Iturriaga CR, Bisen YB, Caid MJ, Reinhardt KR. Heterotopic Ossification Following Direct Anterior Total Hip Arthroplasty With and Without Postoperative Analgesic Nonsteroidal Anti-inflammatories. *J Arthroplasty* 2021; **36**: 3471-3477 [PMID: 34130870 DOI: 10.1016/j.arth.2021.05.017]
- 12 Kamineni S, Maritz NG, Morrey BF. Proximal radial resection for posttraumatic radioulnar synostosis: a new technique to improve forearm rotation. *J Bone Joint Surg Am* 2002; **84**: 745-751 [PMID: 12004015 DOI: 10.2106/00004623-200205000-00007]
- 13 Schonauer C, Tessitore E, Barbagallo G, Albanese V, Moraci A. The use of local agents: bone wax, gelatin, collagen, oxidized cellulose. *Eur Spine J* 2004; **13** Suppl 1: S89-S96 [PMID: 15221572 DOI: 10.1007/s00586-004-0727-z]
- 14 Krueger A, Leunig M, Siebenrock KA, Beck M. Hip arthroscopy after previous surgical hip dislocation for femoroacetabular impingement. *Arthroscopy* 2007; **23**: 1285-1289.e1 [PMID: 18063171 DOI: 10.1016/j.arthro.2007.07.002]
- 15 Solomon LB, Guevara C, Büchler L, Howie DW, Byard RW, Beck M. Does bone wax induce a chronic inflammatory articular reaction? *Clin Orthop Relat Res* 2012; **470**: 3207-3212 [PMID: 22760602 DOI: 10.1007/s11999-012-2457-6]
- 16 Dennis K, Poon M, Chow E. Nausea and vomiting induced by gastrointestinal radiation therapy: current status and future directions. *Curr Opin Support Palliat Care* 2015; **9**: 182-188 [PMID: 25872120 DOI: 10.1097/SPC.0000000000000130]
- 17 Koch M, Dezi A, Ferrario F, Capurso I. Prevention of nonsteroidal anti-inflammatory drug-induced gastrointestinal mucosal injury. A meta-analysis of randomized controlled clinical trials. *Arch Intern Med* 1996; **156**: 2321-2332 [PMID: 8911239]
- 18 Samrat R, Naimish M, Samiran N. Post-Gastrectomy Complications - An Overview. *Chirurgia (Bucur)* 2020; **115**: 423-431 [PMID: 32876015 DOI: 10.21614/chirurgia.115.4.423]
- 19 Alegre M, Garcés JR, Puig L. Bone wax in dermatologic surgery. *Actas Dermosifiliogr* 2013; **104**: 299-303 [PMID: 23582299 DOI: 10.1016/j.adengl.2013.03.001]



Published by **Baishideng Publishing Group Inc**
7041 Koll Center Parkway, Suite 160, Pleasanton, CA 94566, USA

Telephone: +1-925-3991568

E-mail: bpgoffice@wjgnet.com

Help Desk: <https://www.f6publishing.com/helpdesk>

<https://www.wjgnet.com>

