



Primary acinic cell carcinoma of the breast: A case report and review of literature

Jia-Sheng Ding, Min Zhang, Fang-Fang Zhou

Specialty type: Medicine, research and experimental

Provenance and peer review: Unsolicited article; Externally peer reviewed.

Peer-review model: Single blind

Peer-review report's scientific quality classification

Grade A (Excellent): 0
Grade B (Very good): 0
Grade C (Good): 0
Grade D (Fair): 0
Grade E (Poor): 0

P-Reviewer: Moshref L, Saudi Arabia

Received: October 12, 2023

Peer-review started: October 12, 2023

First decision: November 20, 2023

Revised: November 27, 2023

Accepted: December 20, 2023

Article in press: December 20, 2023

Published online: January 6, 2024



Jia-Sheng Ding, Department of Intensive Care Unit, Lishui Central Hospital, The Fifth Affiliated Hospital of Wenzhou Medical University, Lishui 323000, Zhejiang Province, China

Min Zhang, Department of Pathology, Lishui Central Hospital, The Fifth Affiliated Hospital of Wenzhou Medical University, Lishui 323000, Zhejiang Province, China

Fang-Fang Zhou, Department of Ultrasound, Lishui Central Hospital, The Fifth Affiliated Hospital of Wenzhou Medical University, Lishui 323000, Zhejiang Province, China

Corresponding author: Fang-Fang Zhou, BSc, Doctor, Department of Ultrasound, Lishui Central Hospital, The Fifth Affiliated Hospital of Wenzhou Medical University, No. 289 Kuocang Road, Lishui 323000, Zhejiang Province, China. zf1006835371@163.com

Abstract

BACKGROUND

In the current World Health Organization classification, acinic cell carcinoma (AcCC) of the breast is considered a rare histological subtype of triple-negative breast cancer. Because of the few reports in the literature, data concerning clinical outcomes are limited. Here, we report a case of AcCC of the breast in a 48-year-old woman.

CASE SUMMARY

A 48-year-old woman with a mass in her right breast came to our hospital for further diagnosis. Mammography and an ultrasound (US) scan showed a mass in the upper inner side of the right breast. She then underwent surgery to resect the mass in her right breast. Postoperative pathological examination revealed that the tumor had abundant acinar-like structures formed by tumor cells with prominent eosinophilic granules in the cytoplasm, consistent with acinar cell carcinoma. The results of immunohistochemical analysis supported the diagnosis of breast acinar cell carcinoma. Two months later, she underwent breast-conserving surgery and sentinel lymph node biopsy. The pTNM stage was T2N0M0. After surgery, the patient received 30 radiotherapy sessions. The patient was followed up for a period of one year, and no recurrence was found.

CONCLUSION

AcCC of the breast is a rare type of malignant tumor. Because it is usually asymptomatic and can be detected by imaging studies, routine breast US or mammograms are important. However, there are no characteristic diagnostic imaging findings or clinical manifestations, so immunohistochemical examination is

critical for an accurate diagnosis of AcCC of the breast.

Key Words: Acinic cell carcinoma; Breast; Malignant tumor; Immunohistochemical; Surgery; Case report

©The Author(s) 2024. Published by Baishideng Publishing Group Inc. All rights reserved.

Core Tip: Acinic cell carcinoma (AcCC) of the breast is extremely rare. It is considered a clinically low-grade malignancy. Few cases of breast AcCC have been reported. AcCC of the breast is usually asymptomatic and can be detected by imaging studies. Routine breast ultrasound or mammograms are important. Herein, a 48-year-old woman with AcCC of the breast is reported.

Citation: Ding JS, Zhang M, Zhou FF. Primary acinic cell carcinoma of the breast: A case report and review of literature. *World J Clin Cases* 2024; 12(1): 196-203

URL: <https://www.wjgnet.com/2307-8960/full/v12/i1/196.htm>

DOI: <https://dx.doi.org/10.12998/wjcc.v12.i1.196>

INTRODUCTION

Acinic cell carcinoma (AcCC) of the breast is recognized as a rare histological form of triple-negative breast cancer (TNBC) in the current World Health Organization classification[1]. It is a tumor unique to the salivary glands and can also occur in the breast[2]. It was first described in the breast in 1996 by Roncaroli *et al*[3]. To date, 64 cases of breast AcCC have been reported in the literature[3-34]. Here, we report a case of acinar cell carcinoma of the breast in a 48-year-old woman and review some of the literature.

CASE PRESENTATION

Chief complaints

A 48-year-old woman found a mass in her right breast during a routine breast ultrasound (US) 4 d prior.

History of present illness

The patient felt a lump in the right breast during a routine breast US examination 4 d prior, but the patient did not feel any discomfort. She had no nipple retraction, itching, pain, discharge, bleeding or ulcers. For further investigation, she came to our hospital.

History of past illness

The patient had no history of hypertension, heart disease, diabetes mellitus, alcohol consumption or smoking. She also had no history of surgery.

Personal and family history

The patient denied having any relevant family history.

Physical examination

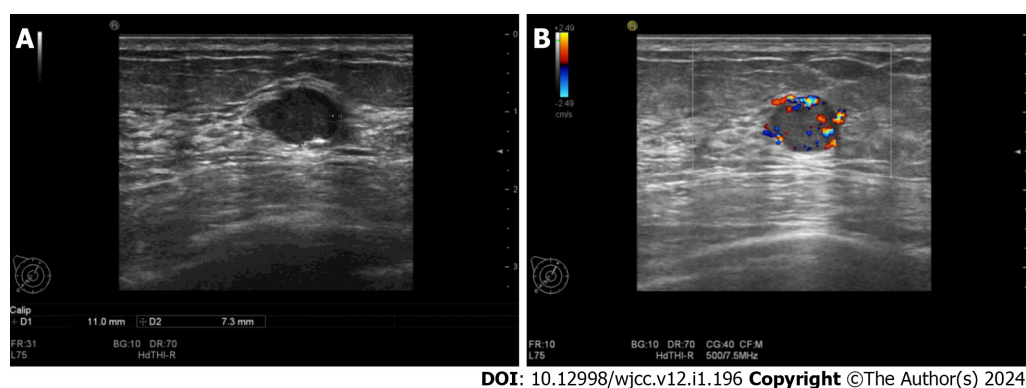
On examination, no palpable mass was discovered. We found no nipple discharge or palpable ipsilateral axillary or supraclavicular lymph nodes.

Laboratory examinations

The results of blood biochemistry and coagulation tests were normal. Hepatitis B surface antigen was positive, and anti-human immunodeficiency virus, syphilis and anti-hepatitis C virus tests were all negative.

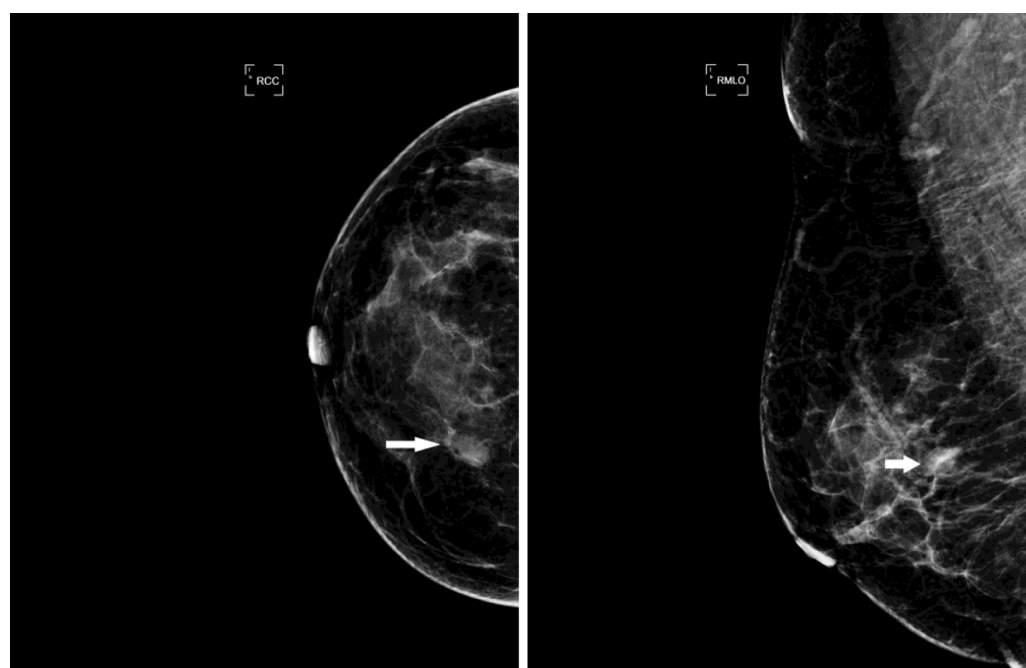
Imaging examinations

An US scan showed an 11 mm × 7 mm hypoechoic mass in the upper inner quadrant of the right breast, 30 mm away from the nipple, regular in shape, with a distinct margin. Color Doppler imaging showed hypervascularity (Figure 1). The mammogram showed a high-density mass in the upper inner quadrant of the right breast measuring 13 mm × 8 mm with indistinct margins. The subcutaneous tissue structure was clear, with no obvious calcification or thickening of the skin and no enlarged lymph nodes in the axilla (Figure 2). This case is classified as Breast Imaging Reporting and Data System (BI-RADS) 4A according to the BI-RADS category.



DOI: 10.12998/wjcc.v12.i1.196 Copyright ©The Author(s) 2024.

Figure 1 Ultrasound scan. A: An 11 mm × 7 mm hypoechoic mass in the upper inner quadrant of the right breast, regular in shape, with a distinct margin; B: Color Doppler imaging showed hypervascularity.



DOI: 10.12998/wjcc.v12.i1.196 Copyright ©The Author(s) 2024.

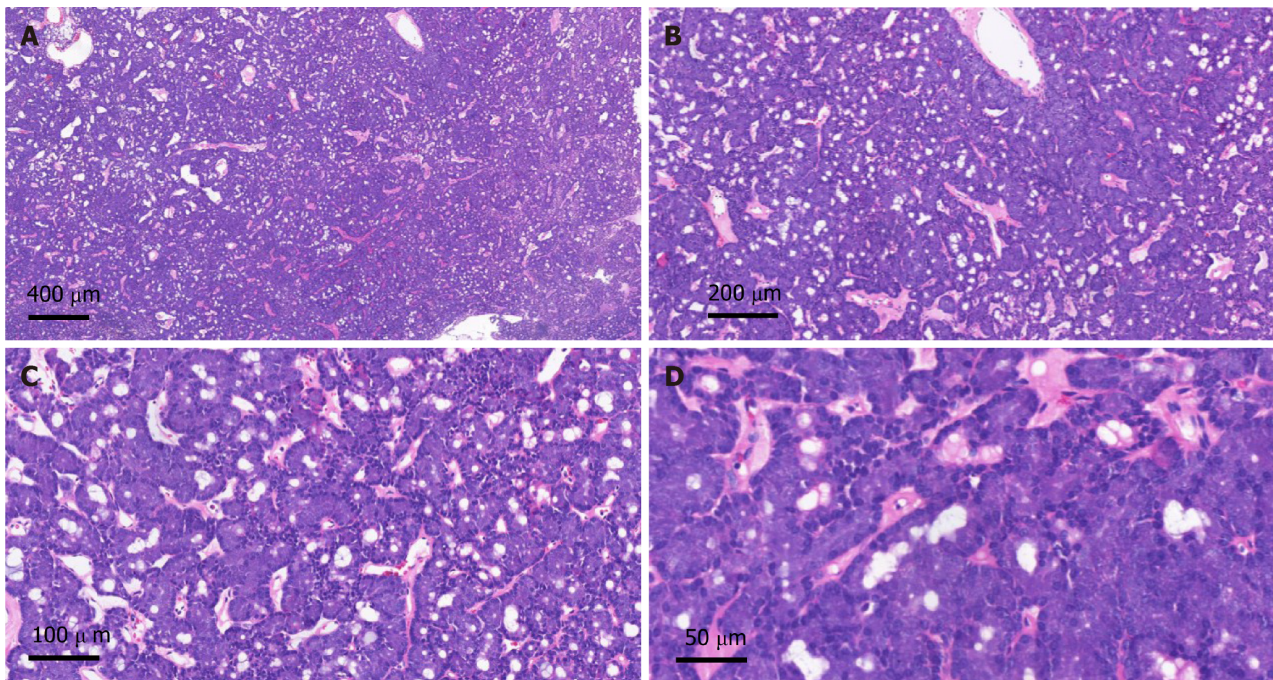
Figure 2 Mammography. A high-density mass in the upper inner quadrant of the right breast measuring 13 mm × 8 mm with indistinct margins (the white arrows indicate the location of the mass).

Further diagnostic work-up

She underwent a right breast mass excision. During the surgery, a 10 mm × 10 mm solid diseased mass was detected at the upper inner side of the right breast with an intact capsule. It had a smooth surface and intermediate texture. Intraoperative frozen pathology indicated a neuroendocrine tumor, and the final diagnosis needed immunohistochemical examination. The postoperative pathological examination confirmed that the tumor revealed abundant acinar-like structures formed by tumor cells with prominent eosinophilic granules in the cytoplasm, consistent with acinar cell carcinoma (Figure 3). Immunohistochemical staining showed that the tumor cells were positive for Ki67 (1% positive) and CerbB-2 but negative for ER, PR, HER-2, CK5/6, CgA, Syn, P63 and calponin (Figure 4).

FINAL DIAGNOSIS

The final diagnosis was acinar cell carcinoma of the right breast.



DOI: 10.12998/wjcc.v12.i1.196 Copyright ©The Author(s) 2024.

Figure 3 Histopathological findings. A: Hematoxylin and eosin (HE) staining ($\times 40$); B: HE staining ($\times 100$); C: HE staining ($\times 200$); D: HE staining ($\times 400$).

TREATMENT

Two months later, a right partial mastectomy was performed, and right axillary sentinel lymph node biopsy was appended. Both the surgical margins and lymph node status were negative. The pathologic stage on the synoptic report was T2N0M0. After surgery, the patient received 30 radiotherapy sessions.

OUTCOME AND FOLLOW-UP

No recurrence or metastasis was detected at the one-year follow-up of this patient, and the patient remains recurrence-free and metastasis-free to date.

DISCUSSION

Both breast and salivary glands are exocrine microtubule glands with similar morphological characteristics. Therefore, the same type of tumor may appear in two locations. Based on the current World Health Organization classification, it is considered a histological subtype of TNBC[1].

The first case of primary AcCC of the breast was reported in 1996, with morphological features similar to salivary glands[3]. To date, including the present case, approximately 64 cases have been reported in the literature[3-34]. The only case of male breast AcCA was reported by Shimao *et al*[4]. According to previous reports, the age of onset is 23 to 80 years, the average age is 49 years, the median age is 48 years, and the tumor size is 10 to 55 (average 28) mm[3-34]. The patient in this case was a 48-year-old female, which is consistent with the literature. Table 1 summarizes the clinical characteristics of the 64 previously reported cases and this case.

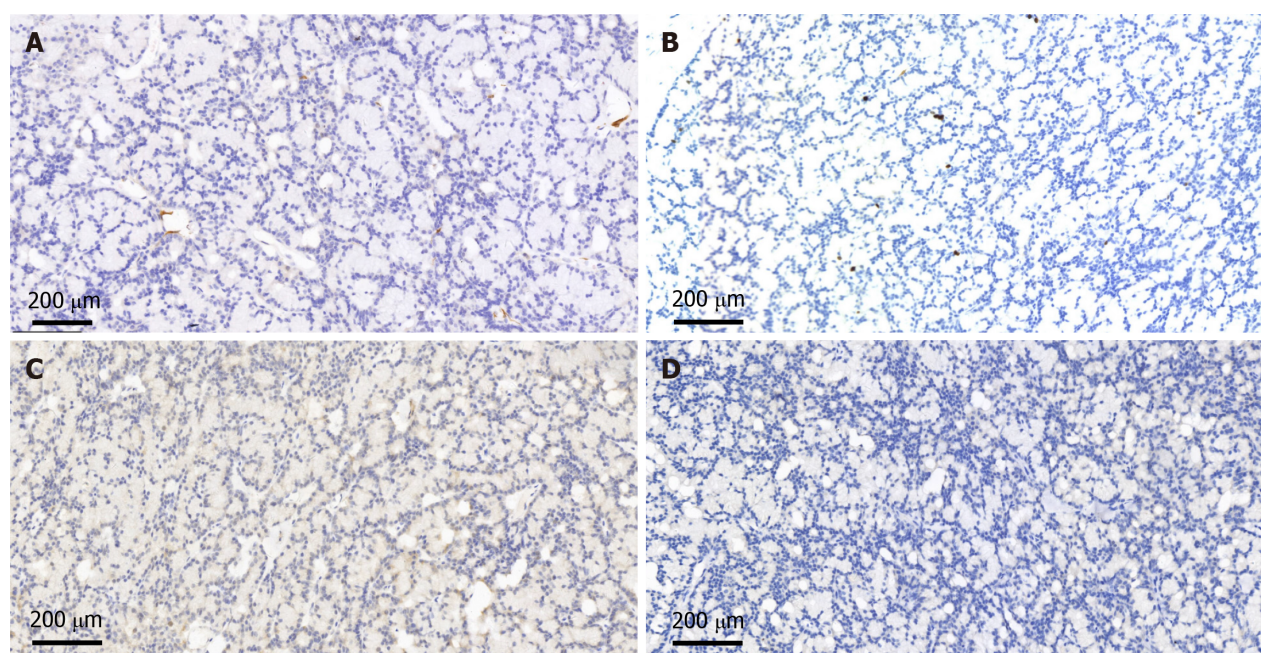
Regarding the diagnosis of breast AcCC, the clinical diagnosis of new breast masses is based on the “triple assessment” method, including inspection, imaging (mammogram and US) and histology (core biopsy), which together provide a comprehensive algorithm[34]. This combination of investigations is better than the diagnosis using a single investigation method. AcCC of the breast has no specific clinical manifestations. Most patients visit clinics because of the discovery of a painless breast mass. According to previous literature, none of the patients had a history of pruritus, bleeding, discharge, ulceration, skin alterations or retraction of the nipple. Routine laboratory examinations of breast AcCC have also shown no specificity.

Literature on AcCC of the breast is rare, and literature on radiological findings is even rarer. According to the literature, only 8 patients had undergone breast US examinations and mammography. Mammography imaging of breast AcCC usually presents as high-density masses and generally without skin or nipple retraction. Calcification was described for six cases, with 3 having microcalcifications and 3 having no calcifications. The typical US feature was hypoechoic. The shapes and borders of breast AcCC were oval/spiculated and circumscribed/indistinct according to the

Table 1 Summary of cases reported on characteristics of acinic cell carcinomas of the breast from 1996 to 2020

Characteristic	n (%)
Sex	64
Male	1 (1.6)
Female	63 (98.4)
Age	58
≤ 40	13 (22.4)
40-60	34 (58.6)
≥ 60	11 (19.0)
Tumor size (mm)	52
≤ 20	12 (23.1)
20-40	28 (53.8)
≥ 40	12 (23.1)
Site	40
Left	14 (35.0)
Right	26 (65.0)
Lymph node metastasis	38
Yes	9 (23.7)
No	29 (76.3)
Surgical approach	44
MRM + ALND	11 (25.0)
BCS + ALND	11 (25.0)
MRM	1 (2.2)
BCS	5 (11.4)
MRM + SLND	8 (18.2)
BCS + SLND	8 (18.2)
Adjuvant therapy	25
CT	6 (24.0)
Neo-CT	3 (12.0)
HT	2 (8.0)
RT	4 (16.0)
CT + RT	5 (20.0)
CT + HT	3 (12.0)
CT + RT + HT	2 (8.0)
Recurrences/metastasis	36
Yes	8 (22.2)
No	28 (77.8)
Status	36
Alive (NED)	33 (91.7)
Died (DWD)	3 (8.3)

MRM: Modified radical mastectomy; ALNA: Axillary lymph node dissection; BCS: Breast-conserving surgery; SLND: Sentinel lymph node dissection; CT: Chemotherapy; Neo-CT: Neoadjuvant chemotherapy; HT: Hormone therapy; RT: Radiation therapy; NED: No evidence of disease; DWD: Died with disease.



DOI: 10.12998/wjcc.v12.i1.196 Copyright ©The Author(s) 2024.

Figure 4 Immunohistochemical staining (× 100). A: Immunostaining for calponin; B: Immunostaining for Ki67 (1% positive); C: Immunostaining for P63; D: Immunostaining for PR.

summary in this review. Three cases were circumscribed, 4 were indistinct, 3 turned into an oval shape, and 4 showed a spiculated shape. Intratumoral cystic components were not common, as there were few reports describing this. Only one male has been reported to have this disease, namely, one 23-year-old man in the study by Shimao *et al*[4]. Ultrasonography of the breast showed a cystic mass with clear edges, consisting of hypoechoic intracystic effusion and a hyperechoic intracystic tumor. Unfortunately, reports on breast AcCC imaging are scarce, so characteristic imaging findings cannot be summarized well.

A review of previous reports shows that the morphological appearance of breast AcCC is very consistent. It has the same morphology as tumors found in salivary glands. Most reported cases of breast AcCC have described the tumor structure, where solid and nested components are mixed with renal tubules and microglandular morphological areas[5, 11,15]. In most cases, the immunohistochemical analysis of breast AcCA is negative for hormone receptors, while all specimens express lysozyme, S-100, and A1-ACT and are positive for amylase and PAS. Myoepithelial markers such as calponin and p63 are negative in breast AcCC, confirming the invasive growth pattern of the tumor[18]. In the case reported herein, the immunohistochemical results showed that the tumor cells were negative for ER, PR, HER-2, CK5/6, CgA, Syn, P63 and calcin, consistent with previous reports in the literature.

Standardized treatments for breast AcCC are lacking, perhaps due to its rarity. Treatment can involve surgery, radiotherapy, and chemotherapy. The surgical treatment options are either modified radical mastectomy (MRM) or breast-conserving surgery (BCS). The 44 patients reported in Table 1 underwent surgery, of whom 20 underwent MRM and 24 underwent BCS. Of the 38 patients treated for axillary disease, 22 underwent axillary lymph node dissection, and 16 underwent sentinel lymph node dissection (SLND). Three patients received neoadjuvant chemotherapy (CT) before surgery. According to reports, 22 patients received postoperative adjuvant therapy: 16 received CT, 7 received hormone therapy, and 11 received radiotherapy (Table 1). In our case, the patient underwent BCS and SLND, 30 radiotherapy sessions were performed after the operation, and the treatment effect was very good.

Of the 64 patients reported thus far, 36 were followed up for a period of 3 to 184.8 (mean 35.5) mo, of whom 28 (77.8%) had no recurrence, 8 (22.2%) had recurrence or distant metastasis (bone, liver, lung or leptomeningeal), and three of them died at 12, 32 and 34 mo after diagnosis. Due to the lack of early reports in the literature, it is generally believed that the prognosis of breast AcCC is good[31]. However, breast AcCC may also coexist with highly malignant TNBC, which could lead to recurrence, metastasis, and even death[7,15,32]. Therefore, more data on this rare tumor type are needed so that a clinical consensus can be reached for the treatment of this rare neoplasm.

CONCLUSION

We report an extremely rare case of AcCC of the breast. Because AcCC of the breast is usually asymptomatic and can be detected by imaging studies, routine breast US or mammograms are important. Unfortunately, there are no characteristic imaging findings or clinical manifestations of the disease, so immunohistochemical analysis is critical for an accurate diagnosis of AcCC of the breast.

FOOTNOTES

Author contributions: Ding JS was responsible for collecting the medical history of the patient and drafting the paper; Zhang M is a pathologist who provided the pathological results; Zhou FF reviewed the literature and revised the manuscript; and all authors issued final approval for the version to be submitted.

Informed consent statement: Informed written consent was obtained from the patient for publication of this report and any accompanying images.

Conflict-of-interest statement: All the authors report no relevant conflicts of interest for this article.

CARE Checklist (2016) statement: The authors have read the CARE Checklist (2016), and the manuscript was prepared and revised according to the CARE Checklist (2016).

Open-Access: This article is an open-access article that was selected by an in-house editor and fully peer-reviewed by external reviewers. It is distributed in accordance with the Creative Commons Attribution NonCommercial (CC BY-NC 4.0) license, which permits others to distribute, remix, adapt, build upon this work non-commercially, and license their derivative works on different terms, provided the original work is properly cited and the use is non-commercial. See: <https://creativecommons.org/licenses/by-nc/4.0/>

Country/Territory of origin: China

ORCID number: Jia-Sheng Ding 0000-0002-3914-7398; Min Zhang 0000-0003-2822-8528; Fang-Fang Zhou 0000-0002-8650-1150.

S-Editor: Wang JJ

L-Editor: A

P-Editor: Zhang YL

REFERENCES

- 1 Frank GA, Danilova NV, Andreeva Iulu, Nefedova NA. [WHO classification of tumors of the breast, 2012]. *Ark Patol* 2013; **75**: 53-63 [PMID: 24006766]
- 2 Foschini MP, Krausz T. Salivary gland-type tumors of the breast: a spectrum of benign and malignant tumors including "triple negative carcinomas" of low malignant potential. *Semin Diagn Pathol* 2010; **27**: 77-90 [PMID: 20306833 DOI: 10.1053/j.semdp.2009.12.007]
- 3 Roncaroli F, Lamovec J, Zidar A, Eusebi V. Acinic cell-like carcinoma of the breast. *Virchows Arch* 1996; **429**: 69-74 [PMID: 8865856 DOI: 10.1007/bf00196823]
- 4 Damiani S, Pasquinelli G, Lamovec J, Peterse JL, Eusebi V. Acinic cell carcinoma of the breast: an immunohistochemical and ultrastructural study. *Virchows Arch* 2000; **437**: 74-81 [PMID: 10963383 DOI: 10.1007/s004280000206]
- 5 Shimao K, Haga S, Shimizu T, Imamura H, Watanabe O, Kinoshita J, Nagumo H, Utada Y, Okabe T, Kajiwarra T, Oshibe N, Aiba M. Acinic Cell Adenocarcinoma Arising in the Breast of a Young Male: A Clinicopathological, Immunohistochemical and Ultrastructural Study. *Breast Cancer* 1998; **5**: 77-81 [PMID: 11091630 DOI: 10.1007/BF02967419]
- 6 Schmitt FC, Ribeiro CA, Alvarenga S, Lopes JM. Primary acinic cell-like carcinoma of the breast--a variant with good prognosis? *Histopathology* 2000; **36**: 286-289 [PMID: 10809602 DOI: 10.1046/j.1365-2559.2000.0872f.x]
- 7 Coyne JD, Dervan PA. Primary acinic cell carcinoma of the breast. *J Clin Pathol* 2002; **55**: 545-547 [PMID: 12101208 DOI: 10.1136/jcp.55.7.545]
- 8 Elster EA, Markusic J, Ball R, Soballe P, Henry M, Louie A, Clare S. Primary acinic cell carcinoma of the breast. *Am Surg* 2002; **68**: 993-995 [PMID: 12455793]
- 9 Hirokawa M, Sugihara K, Sai T, Monobe Y, Kudo H, Sano N, Sano T. Secretory carcinoma of the breast: a tumour analogous to salivary gland acinic cell carcinoma? *Histopathology* 2002; **40**: 223-229 [PMID: 11895487 DOI: 10.1046/j.1365-2559.2002.01346.x]
- 10 Kahn R, Holtveg H, Nissen F, Holck S. Are acinic cell carcinoma and microglandular carcinoma of the breast related lesions? *Histopathology* 2003; **42**: 195-196 [PMID: 12558752 DOI: 10.1046/j.1365-2559.2003.01532_1.x]
- 11 Peintinger F, Leibl S, Reitsamer R, Moirfar F. Primary acinic cell carcinoma of the breast: a case report with long-term follow-up and review of the literature. *Histopathology* 2004; **45**: 645-648 [PMID: 15569060 DOI: 10.1111/j.1365-2559.2004.01957.x]
- 12 Kinkor Z, Skálová A. [Acinic cell-like differentiation in invasive ductal carcinoma and in ductal hyperplasia of the breast--report of two cases]. *Cesk Patol* 2005; **41**: 29-33 [PMID: 15816121]
- 13 Tanahashi C, Yabuki S, Akamine N, Yatabe Y, Ichihara S. Pure acinic cell carcinoma of the breast in an 80-year-old Japanese woman. *Pathol Int* 2007; **57**: 43-46 [PMID: 17199742 DOI: 10.1111/j.1440-1827.2007.02055.x]
- 14 Reis-Filho JS, Natrajan R, Vatcheva R, Lambros MB, Marchió C, Mahler-Araújo B, Paish C, Hodi Z, Eusebi V, Ellis IO. Is acinic cell carcinoma a variant of secretory carcinoma? A FISH study using ETV6'split apart' probes. *Histopathology* 2008; **52**: 840-846 [PMID: 18462362 DOI: 10.1111/j.1365-2559.2008.03046.x]
- 15 Huo L, Bell D, Qiu H, Sahin A, Wu Y, Sneige N. Paneth cell-like eosinophilic cytoplasmic granules in breast carcinoma. *Ann Diagn Pathol* 2011; **15**: 84-92 [PMID: 21163678 DOI: 10.1016/j.anndiagpath.2010.08.007]
- 16 Chang ED, Lee EJ, Lee AW, Kim JS, Kang CS. Primary acinic cell carcinoma of the breast: a case report with an immunohistochemical and ultrastructural studies. *J Breast Cancer* 2011; **14**: 160-164 [PMID: 21847414 DOI: 10.4048/jbc.2011.14.2.160]
- 17 Choh CT, Komar V, Courtney SP. Primary acinic cell carcinoma of the breast: a rare lesion with good prognosis. *Breast J* 2012; **18**: 610-611 [PMID: 23003197 DOI: 10.1111/tbj.12013]
- 18 Sakuma T, Mimura A, Tanigawa N, Takamizu R. Fine needle aspiration cytology of acinic cell carcinoma of the breast. *Cytopathology* 2013;

- 24: 403-405 [PMID: [22734799](#) DOI: [10.1111/j.1365-2303.2012.00996.x](#)]
- 19 **Shingu K**, Ito T, Kaneko G, Itoh N. Primary acinic cell carcinoma of the breast: a clinicopathological and immunohistochemical study. *Case Rep Oncol Med* 2013; **2013**: 372947 [PMID: [24191209](#) DOI: [10.1155/2013/372947](#)]
 - 20 **Osako T**, Takeuchi K, Horii R, Iwase T, Akiyama F. Secretory carcinoma of the breast and its histopathological mimics: value of markers for differential diagnosis. *Histopathology* 2013; **63**: 509-519 [PMID: [23944930](#) DOI: [10.1111/his.12172](#)]
 - 21 **Winkler N**, Morrell G, Factor RE. Invasive carcinoma with acinic cell-like features of the breast. *Breast J* 2013; **19**: 334-335 [PMID: [23600952](#) DOI: [10.1111/tbj.12119](#)]
 - 22 **Falletti J**, Coletti G, Rispoli E, Scarabeo F, Cervasio M, Tornillo L, Pettinato G, Insabato L. Acinic cell carcinoma of the breast arising in microglandular adenosis. *Case Rep Pathol* 2013; **2013**: 736048 [PMID: [24369519](#) DOI: [10.1155/2013/736048](#)]
 - 23 **Ripamonti CB**, Colombo M, Mondini P, Siranoush M, Peissel B, Bernard L, Radice P, Carcangiu ML. First description of an acinic cell carcinoma of the breast in a BRCA1 mutation carrier: a case report. *BMC Cancer* 2013; **13**: 46 [PMID: [23374397](#) DOI: [10.1186/1471-2407-13-46](#)]
 - 24 **Limite G**, Di Micco R, Esposito E, Sollazzo V, Cervotti M, Pettinato G, Varone V, Benassai G, Monda A, Luglio G, Maisto V, Izzo G, Forestieri P. The first case of acinic cell carcinoma of the breast within a fibroadenoma: case report. *Int J Surg* 2014; **12** Suppl 1: S232-S235 [PMID: [24859396](#) DOI: [10.1016/j.ijssu.2014.05.005](#)]
 - 25 **Zhao Y**, Li W, Lang R, Yang Y, Gao X, Zheng Y, Zhang C, Fu X, Fu L. Primary acinic cell carcinoma of the breast: a case report and review of the literature. *Int J Surg Pathol* 2014; **22**: 177-181 [PMID: [23564703](#) DOI: [10.1177/1066896913483898](#)]
 - 26 **Piscuoglio S**, Hodi Z, Katabi N, Guerini-Rocco E, Macedo GS, Ng CK, Edelweiss M, De Mattos-Arruda L, Wen HY, Rakha EA, Ellis IO, Rubin BP, Weigelt B, Reis-Filho JS. Are acinic cell carcinomas of the breast and salivary glands distinct diseases? *Histopathology* 2015; **67**: 529-537 [PMID: [25688711](#) DOI: [10.1111/his.12673](#)]
 - 27 **Conlon N**, Sadri N, Corben AD, Tan LK. Acinic cell carcinoma of breast: morphologic and immunohistochemical review of a rare breast cancer subtype. *Hum Pathol* 2016; **51**: 16-24 [PMID: [27067778](#) DOI: [10.1016/j.humpath.2015.12.014](#)]
 - 28 **Kawai H**, Sugimoto R, Iga N, Ikeda H, Yoshida R, Waki N, Ishizaki M, Nishi H, Yamashita K. [A Case of Primary Acinic Cell Carcinoma(ACC)of the Breast]. *Gan To Kagaku Ryoho* 2016; **43**: 2019-2021 [PMID: [28133208](#)]
 - 29 **Li H**, Wang F, Shen P, Zhou F. Pure acinic cell carcinoma of the breast: A case report and literature review. *Medicine (Baltimore)* 2017; **96**: e8866 [PMID: [29382006](#) DOI: [10.1097/MD.00000000000008866](#)]
 - 30 **Sen R**, Bhutani N, Kamboj J, Dahiya S. Primary acinic cell carcinoma of the breast: A case report with a clinicopathological and immunohistochemical study of a rare breast cancer subtype. *Ann Med Surg (Lond)* 2018; **35**: 137-140 [PMID: [30305896](#) DOI: [10.1016/j.amsu.2018.09.030](#)]
 - 31 **Agafonoff S**, Sobolewski A, Braverman TS. Adenoid cystic carcinoma of the breast - Discordant size on imaging and pathology: A case report and review of literature. *Ann Med Surg (Lond)* 2019; **43**: 1-4 [PMID: [31193457](#) DOI: [10.1016/j.amsu.2019.04.007](#)]
 - 32 **Sardana R**, Parwani AV, Cui X, Balakrishna J. Unusual cerebrospinal fluid finding of intracytoplasmic granules in metaplastic carcinoma of the breast with acinar differentiation. *Diagn Cytopathol* 2021; **49**: E152-E155 [PMID: [33118313](#) DOI: [10.1002/dc.24648](#)]
 - 33 **Makino Y**, Kawamata A, Hikino H, Murata Y, Takahashi T, Miura H. [A Case of Primary Acinic Cell Carcinoma of the Breast]. *Gan To Kagaku Ryoho* 2020; **47**: 1945-1947 [PMID: [33468761](#)]
 - 34 **Agha RA**, Borrelli MR, Farwana R, Koshy K, Fowler AJ, Orgill DP, SCARE Group. The SCARE 2018 statement: Updating consensus Surgical CAsE RReport (SCARE) guidelines. *Int J Surg* 2018; **60**: 132-136 [PMID: [30342279](#) DOI: [10.1016/j.ijssu.2018.10.028](#)]



Published by **Baishideng Publishing Group Inc**
7041 Koll Center Parkway, Suite 160, Pleasanton, CA 94566, USA

Telephone: +1-925-3991568

E-mail: bpgoffice@wjgnet.com

Help Desk: <https://www.f6publishing.com/helpdesk>

<https://www.wjgnet.com>

