



Malignant triton tumor in the abdominal wall: A case report

Ho Jik Yang, Donghyun Kim, Won Suk Lee, Sang-Ha Oh

Specialty type: Oncology

Provenance and peer review:

Unsolicited article; Externally peer reviewed.

Peer-review model: Single blind

Peer-review report's scientific quality classification

Grade A (Excellent): 0
Grade B (Very good): B
Grade C (Good): 0
Grade D (Fair): 0
Grade E (Poor): 0

P-Reviewer: Mei LC, China

Received: November 24, 2023

Peer-review started: November 24, 2023

First decision: January 9, 2024

Revised: January 16, 2024

Accepted: February 6, 2024

Article in press: February 6, 2024

Published online: March 16, 2024



Ho Jik Yang, Department of Plastic and Reconstructive Surgery, Chungnam National University Sejong Hospital, Sejong 30099, South Korea

Donghyun Kim, Department of Plastic and Reconstructive Surgery, Chungnam National University Hospital, Daejeon 35015, South Korea

Won Suk Lee, Department of Emergency, Eulji University Hospital, Daejeon 35233, South Korea

Sang-Ha Oh, Department of Plastic and Reconstructive Surgery, Chungnam National University College of Medicine, Daejeon 35015, South Korea

Corresponding author: Sang-Ha Oh, MD, PhD, Professor, Surgeon, Department of Plastic and Reconstructive Surgery, Chungnam National University College of Medicine, 282, Munwha-ro, Jung-gu, Daejeon 35015, South Korea. djplastic@cnu.ac.kr

Abstract

BACKGROUND

Malignant triton tumors (MTTs) comprise a subgroup of malignant peripheral nerve sheath tumors (MPNSTs) that exhibits rhabdomyosarcomatous differentiation and follow an aggressive course. MTTs are primarily located along peripheral nerves. Cases of MTTs in the abdominal wall have not been reported. MTT has a poorer prognosis than classic MPNSTs, and accurate diagnosis necessitates a keen understanding of the clinical history and knowledge of its differential diagnosis intricacies. Treatment for MTTs mirrors that for MPNSTs and is predominantly surgical.

CASE SUMMARY

A 49-year-old woman presented with a subcutaneous mass in her lower abdominal wall and a pre-existing surgical scar that had grown slowly over 3-4 months before the consultation. She had previously undergone radical hysterectomy and concurrent chemo-radiotherapy for cervical cancer approximately 5 years prior to the consultation. Abdominal computed tomography (CT) showed a 1.3 cm midline mass in the lower abdomen with infiltration into the rectus abdominis muscle. There was no sign of metastasis (T1N0M0). An incisional biopsy identified sporadic MTT of the lower abdomen. A comprehensive surgical excision with a 3 cm margin inclusive of the peritoneum was executed. Subsequently, the general surgeon utilized an approach akin to the open peritoneal onlay mesh technique. The patient underwent additional treatment with an excision shaped as a mini-abdominoplasty for the skin defect. No complications arose, and annual follow-up CTs did not show signs of recurrence or metastasis.

CONCLUSION

An abdominal MTT was efficaciously treated with extensive excision and abdominal wall reconstruction, eliminating the need for postoperative radiotherapy.

Key Words: Malignant triton tumor; Abdominal wall; Surgical excision; Reconstruction; Case report

©The Author(s) 2024. Published by Baishideng Publishing Group Inc. All rights reserved.

Core Tip: Malignant triton tumor is an uncommon condition characterized by a poor prognosis. Cases emerging in the abdominal wall are especially rare. Swift differential diagnosis and comprehensive surgical removal play a pivotal role in management. In this instance, we managed to treat the patient without the necessity for postoperative radiotherapy, thanks to a wide excision complemented by suitable reconstruction.

Citation: Yang HJ, Kim D, Lee WS, Oh SH. Malignant triton tumor in the abdominal wall: A case report. *World J Clin Cases* 2024; 12(8): 1467-1473

URL: <https://www.wjgnet.com/2307-8960/full/v12/i8/1467.htm>

DOI: <https://dx.doi.org/10.12998/wjcc.v12.i8.1467>

INTRODUCTION

Malignant peripheral nerve sheath tumors (MPNSTs) constitute approximately 5%-10% of soft tissue sarcomas and are believed to originate from Schwann cells or adjacent cells with perineural differentiation[1]. Malignant triton tumor (MTT), a subtype of MPNST displaying rhabdomyoblastic differentiation, presents in two primary forms: sporadic, and neurofibromatosis type 1 (NF-1)-associated forms. MTT represents approximately 5% of all MPNSTs, and its nomenclature references early experiments with the amphibian Triton, which can regenerate limbs containing muscle following ectopic implantation of the transected end of the sciatic nerve[2].

MTTs are predominantly located along peripheral nerves, frequently near the spine, in the head and neck region, or within the upper and lower extremities. Other uncommon sites include the buttocks, viscera, retroperitoneum, mediastinum, and intracranial locations such as the parieto-occipital lobe, lateral ventricle, and cerebellopontine angle[2-6]. The extreme rarity of this tumor in the abdominal wall motivated this case report.

The presentation, progression, and response to treatment of MTTs remain largely undefined, as published data predominantly consist of case reports and limited patient series. MTT displays aggressive biological behavior, with various factors like location, size, and tumor stage potentially impacting patient prognosis and survival. Non-extremity MTTs often result in a poor prognosis. The metastasis rate for MTT stands at 31.4% and correlates with reduced survival in its sporadic form[7]. Adjuvant radiotherapy plays a crucial role in treatment, with complete surgical excision of MTT providing a survival advantage[8]. However, no studies have explored the relationship between the quality of surgical margins and treatment outcomes.

To shed light on the progression and prognosis of this infrequent neoplasm in the abdominal wall, we detail a case of sporadic MTT originating in the abdominal wall with a distinct prognosis.

CASE PRESENTATION

Chief complaints

A 49-year-old woman presented with a subcutaneous mass in her lower abdominal wall alongside a previous surgical scar.

History of present illness

A subcutaneous mass had enlarged over the 3-4 months prior to consultation.

History of past illness

Approximately 5 years before this consultation, the patient had undergone a radical hysterectomy and concurrent chemo-radiotherapy (135 Gy) for cervical cancer.

Personal and family history

The patient did not display café-au-lait spots or cutaneous neurofibromas. Both her medical and family histories related to NF-1 were unremarkable.

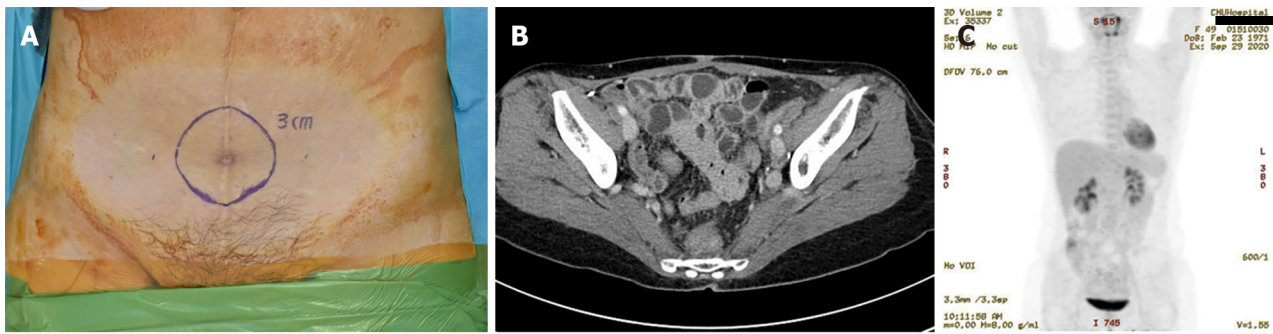


Figure 1 Imaging and macroscopic examination of malignant triton tumor in the lower abdomen. A: Preoperative design for wide resection on the lower abdomen; B: Preoperative computed tomography (CT) depicting a 1.3 cm nodular mass in the middle of the lower abdomen; C: Preoperative positron emission tomography/CT showing mildly increased glucose metabolism at the lesion without any other significant hypermetabolic lesions.

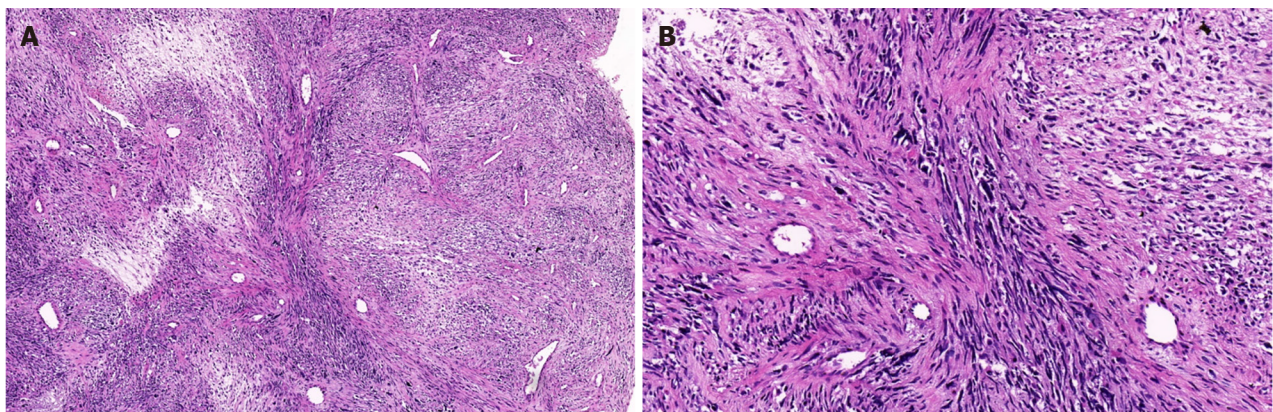


Figure 2 Histopathologic analysis of the resected specimen. A: Photomicrograph displaying hypocellular regions of the tumor with spindle cells, wavy nuclei, thick-walled blood vessels, perivascular accentuation of tumor cells, and some rhabdomyoblasts. Pathological biopsy revealed an MPNST with rhabdomyosarcomatous differentiation [hematoxylin and eosin (H&E staining), $\times 100$]; B: Area showing admixture of undifferentiated small malignant cells and ovoid to round rhabdomyoblasts bearing dense hypereosinophilic cytoplasm (H&E staining, $\times 300$).

Physical examination

A firm, painless subcutaneous mass measuring approximately 1 cm was identified. No inguinal lymphadenopathy was detected upon palpation.

Laboratory examinations

There were no specific findings.

Imaging examinations

Abdominal computed tomography (CT) showed a 1.3 cm midline mass in the lower abdomen with infiltration into the rectus abdominis muscle. Comprehensive CT scans (encompassing the chest, abdomen, and pelvis), combined with positron emission tomography/CT and colonoscopy, found no signs of metastasis (T1N0M0) (Figure 1).

Incisional biopsy

An incisional biopsy identified sporadic MTT in the lower abdomen. Immuno-histochemical analysis revealed that the wavy spindle cells were diffusely and intensely positive for S-100 protein, confirming their neurogenic lineage. The large pleomorphic cells displayed myogenic differentiation, as evidenced by strong positivity for desmin and moderate positivity for myoglobin. These microscopic findings coupled with the expression of the mentioned markers solidified the MTT diagnosis (Figures 2 and 3).

FINAL DIAGNOSIS

Combined with the patient's medical history, the final diagnosis was MTT in the lower abdomen.

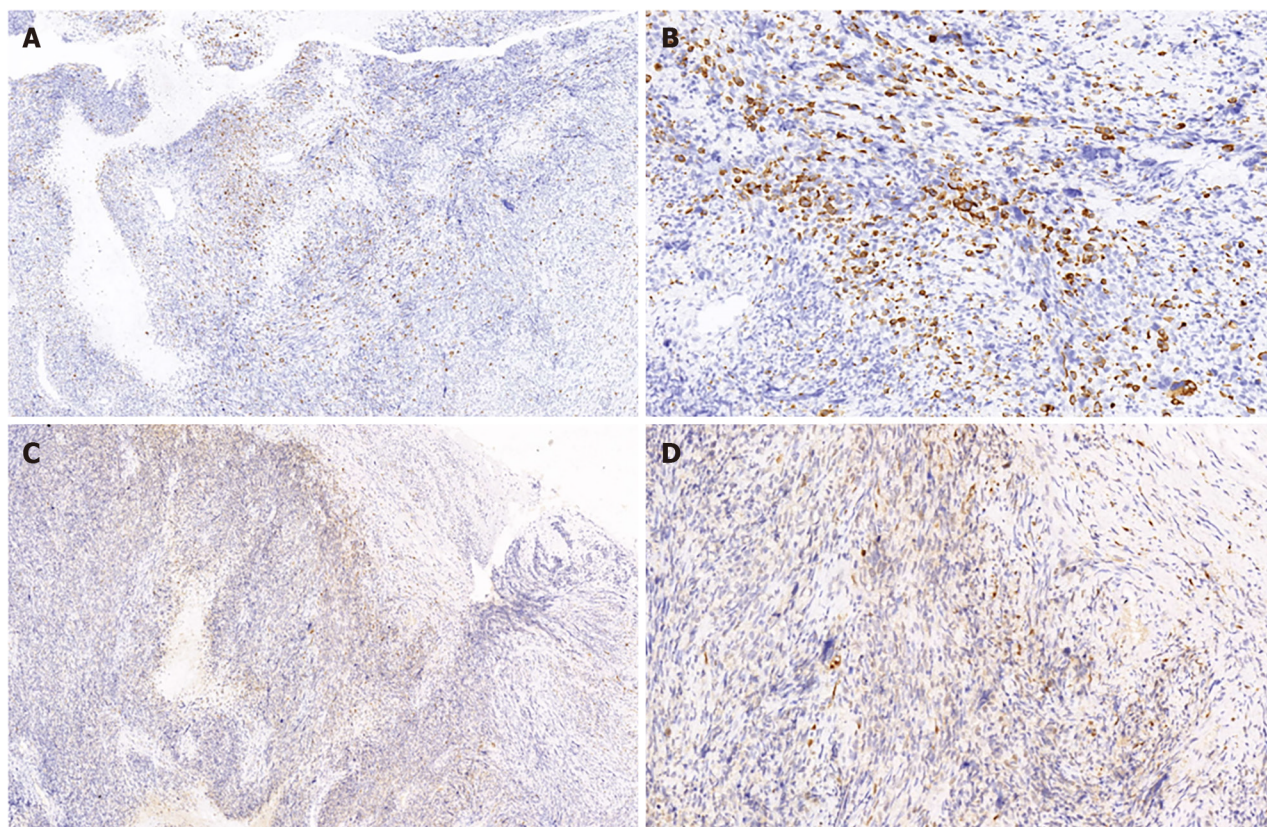


Figure 3 Immunohistochemical examination of the resected specimen. A: Rhabdomyoblasts exhibited focal positivity for desmin (immunohistochemical staining, $\times 100$); B: Desmin (immunohistochemical staining, $\times 300$); C: S-100 was also detected in the malignant cells (immunohistochemical staining, $\times 100$); D: S-100 (immunohistochemical staining, $\times 300$).

TREATMENT

Under general anesthesia, a wide surgical excision of the mass ensuring a 3 cm margin that included the peritoneum was performed. The resected margins were found to be clear. Following this, the general surgeon employed a technique akin to the open peritoneal onlay mesh method to prevent herniation of abdominal wall defects. For reinforcement, a composite mesh (Parietene composite mesh; COVIDIEN, Dublin, Ireland) was introduced and anchored to both pelvic symphyses. The peritoneum was subsequently advanced and repaired on both sides. The anterior fascia's deficit was addressed using an acellular dermal matrix (SureDerm; Hans BioMed, Seoul, South Korea) with further reinforcement and rectification. For minimal effects of scarring, the skin defect was excised in the pattern of a mini-abdominoplasty and was sutured in layers (Figure 4).

OUTCOME AND FOLLOW-UP

The post-operative period was uneventful, and annual follow-up CT scans showed no recurrence or metastasis. Three years post-diagnosis, the patient remains alive and shows no sign of recurrence (Figure 5).

DISCUSSION

MTT presents in two principal forms: sporadic and associated with NF-1. The sporadic form must be distinguished from other spindle cell sarcomas, such as fibrosarcoma, malignant fibrous histiocytoma, and rhabdomyosarcoma, during differential diagnosis[2]. The most widely accepted view suggests that MTT originates from Schwann or ectodermal cells of the neural crest. More than 50% of patients with MTT develop NF-1, with the remainder being disseminated[5]. MTT associated with NF-1 is notably more prevalent in men, particularly in younger age groups (28-36-years-old). The sporadic form tends to appear in older women (40-44-years-old). Divergent differentiation strongly suggests NF-1, and 57% of patients with MTT, which manifests after a prolonged latent period of 10-20 years, have NF-1[9,10]. As many as 6% of malignant or atypical peripheral nerve tumors inclusive of MTT are associated with prior radiotherapy[11], a crucial factor highlighted in our case report. In this instance, the tumor emerged sporadically in a 49-year-old woman and was linked to prior radiotherapy.

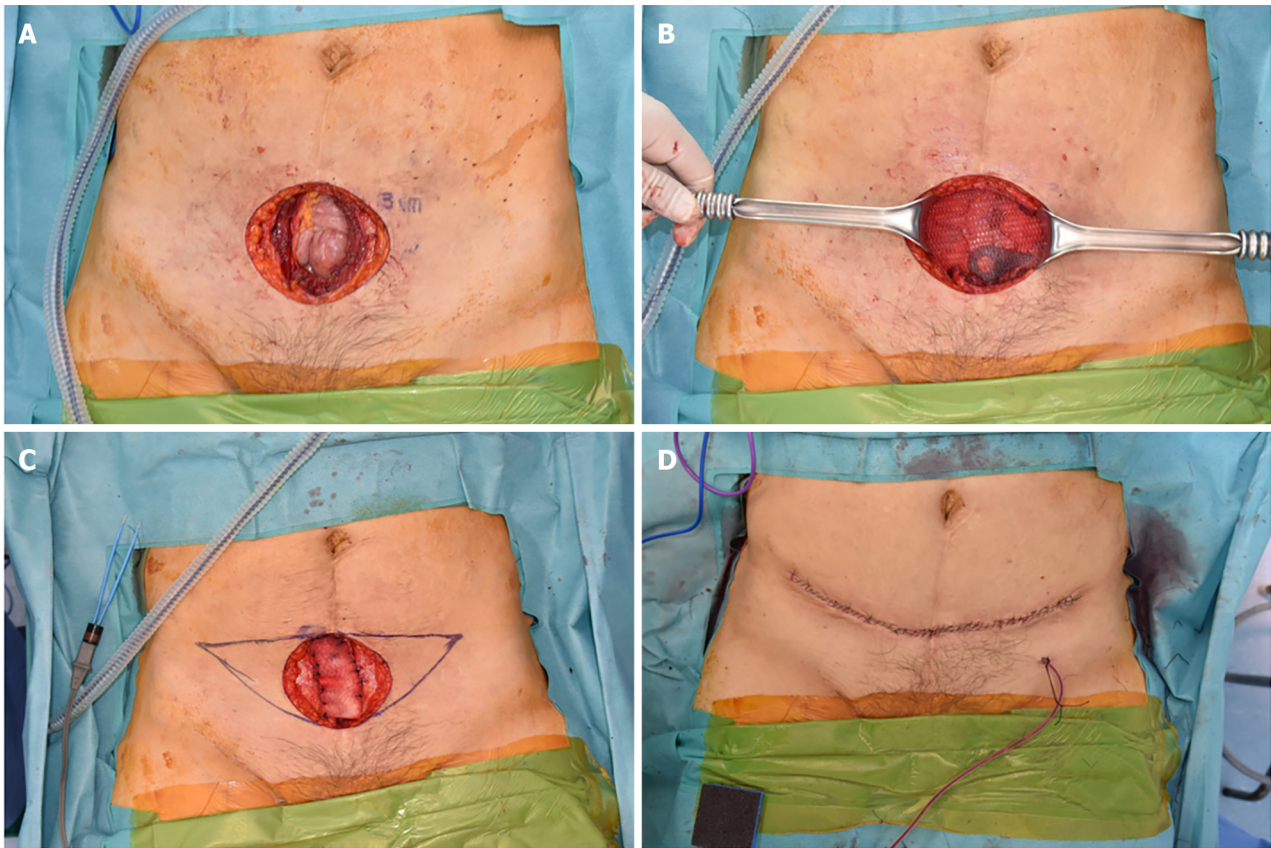


Figure 4 Surgical treatment. A: Wide surgical excision of the mass with a 3 cm margin, inclusive of the peritoneum; B: Both sides of the peritoneum were advanced and repaired; for reinforcement, a composite mesh was inserted and affixed to both pelvic symphyses; C: The anterior fascia's deficiency was filled using an acellular dermal matrix; D: To minimize scarring, the skin defect underwent an additional excision shaped like a mini-abdominoplasty and was sutured layer-by-layer.

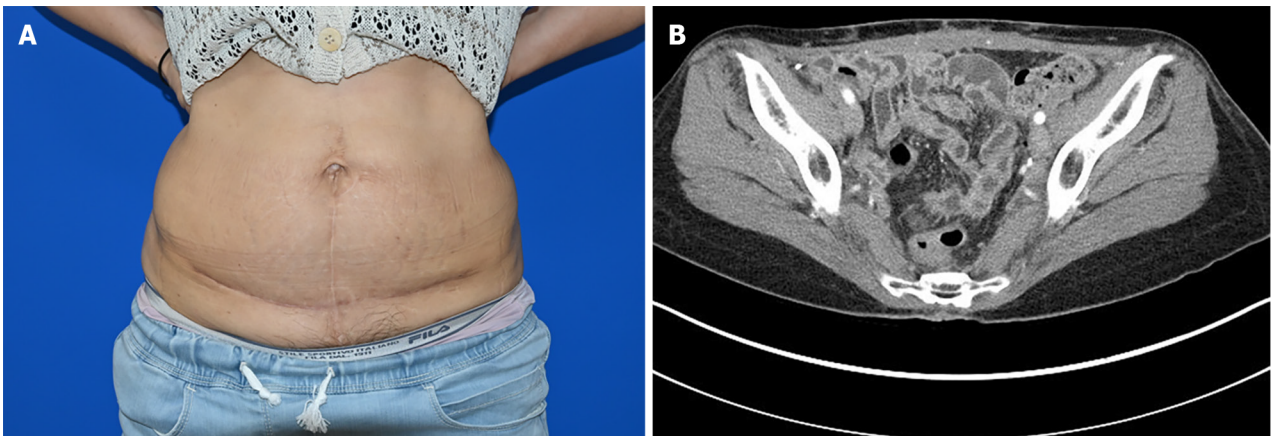


Figure 5 Follow-up. A: Gross photo; B: Sequential follow-up abdominal computed tomography scans taken roughly every 3 mo post-resection. No instances of recurrence or complications were noted during the follow-up period.

The MTT diagnosis chiefly rests on the histopathological and immune-histochemical attributes of the tumor. There is consensus that an MPNST diagnosis can be rooted in morphological features, bolstered by S-100 protein expression. Morphological characteristics include alternating hypocellular and hypercellular regions, the presence of thin wavy comma-shaped or bullet-shaped nuclei in hypocellular areas, nuclear palisading, nerve whorls or tactoid bodies resembling Wagner-Meissner corpuscles, prominent thick-walled vasculature, and heterologous elements like rhabdomyoblasts, cartilage, and bone. Such tumors exhibit focal positivity for the S-100 protein in 50%-90% of cases, pointing to a nerve sheath derivation. Rhabdomyoblasts test positive for desmin, myogenin, and myo-D1[2].

MTTs typically have an unfavorable prognosis depending on the tumor location, grade, and the completeness of surgical margins. Cases located in the head, neck, and extremities are less intricate than those found in other sites, like the buttocks. Past research indicates that in conjunction with NF-1, MTT has a worse prognosis relative to its sporadic

counterparts[9,12]. There was no discernible difference between MTT and MPNST groups regarding rates of local recurrence or metastasis. Nonetheless, the 5-year survival rate for MTTs stands at a mere 5%-15% compared to 50%-60% for MPNSTs. Several factors underlie these disparate survival rates. MTT proliferates swiftly and, in its nascent stages, is susceptible to local recurrence and hematogenous metastases. In comparison to MPNST, MTT often arises in more advanced-aged patients, predominantly manifests in the trunk, and results in larger tumors. Furthermore, patients diagnosed with MTT experience a reduced metastasis-free interval and diminished overall survival. Thus, MTT's aggressive nature sets it apart from MPNST, underscoring the significance of differential diagnosis[13]. Although the association of genomic alteration and prognosis of MTT has not been fully investigated, there have been a few studies that evaluated such a relationship; worse survival was associated with tumors having gains and loss of particular genes, suggesting promise for understanding this disease[14-16].

The treatment approach for MTT mirrors that of MPNST and is predominantly surgical. The Oncology Consensus Group endorses postoperative radiotherapy as a standard treatment protocol for MTT. Typically, radical excision followed by high-dose radiotherapy is employed, and recent studies hint at the potential of neoadjuvant therapy and adjuvant chemotherapy in eliminating micro-metastases. However, this treatment remains controversial. A gluteal MTT case underwent full resection with postoperative chemoradiotherapy and there were no recurrence symptoms for 4 years after treatment[17]. In contrast, another case adopted the same treatment for a patient with rectal MTT, who passed away under palliative therapy and survived only 9 mo[4]. Therefore, it is necessary to seek effective methods for MTT treatment[6]. In the discussed case, the MTT developed post-radiotherapy, a modality that can induce significant side effects when aimed at the abdomen[18]. Given the comprehensive nature of the surgical excision of the abdominal wall tumor, postoperative radiotherapy was deemed unnecessary. While no recurrence or metastasis has been observed, consistent follow-up is imperative, especially since the post-surgery window is under 5 years.

MTT is a rare condition with an unfavorable prognosis. Prompt differential diagnosis and thorough surgical removal are crucial. However, in the presented case, extensive surgical removal was deemed sufficient without the need for postoperative radiotherapy.

CONCLUSION

MTT is an uncommon condition characterized by a poor prognosis. Cases emerging in the abdominal wall are especially rare. Swift differential diagnosis and comprehensive surgical removal play a pivotal role in management. In this instance, we managed to treat the patient without the necessity for postoperative radiotherapy, thanks to a wide excision complemented by suitable reconstruction.

FOOTNOTES

Author contributions: Yang HJ and Kim D wrote and edited the manuscript and performed data collection; Lee WS contributed to data analysis; Oh SH contributed to conceptualization and supervision; All authors have read and approved the final manuscript.

Informed consent statement: Informed written consent was obtained from the patient for publication of this report and any accompanying images.

Conflict-of-interest statement: The authors declare that they have no conflict of interest to disclose.

CARE Checklist (2016) statement: The authors have read the CARE Checklist (2016), and the manuscript was prepared and revised according to the CARE Checklist (2016).

Open-Access: This article is an open-access article that was selected by an in-house editor and fully peer-reviewed by external reviewers. It is distributed in accordance with the Creative Commons Attribution Non-Commercial (CC BY-NC 4.0) license, which permits others to distribute, remix, adapt, build upon this work non-commercially, and license their derivative works on different terms, provided the original work is properly cited and the use is non-commercial. See: <https://creativecommons.org/licenses/by-nc/4.0/>

Country/Territory of origin: South Korea

ORCID number: Ho Jik Yang 0000-0003-2354-3983; Donghyun Kim 0000-0001-8296-9920; Won Suk Lee 0000-0002-1252-1714; Sang-Ha Oh 0000-0003-3734-5005.

S-Editor: Gong ZM

L-Editor: Filipodia

P-Editor: Yu HG

REFERENCES

- 1 **Woodruff JM**, Chernik NL, Smith MC, Millett WB, Foote FW Jr. Peripheral nerve tumors with rhabdomyosarcomatous differentiation (malignant "Triton" tumors). *Cancer* 1973; **32**: 426-439 [PMID: [4198700](#)]
- 2 **Tripathy K**, Mallik R, Mishra A, Misra D, Rout N, Nayak P, Samantray S, Rath J. A Rare Malignant Triton Tumor. *Case Rep Neurol* 2010; **2**: 69-73 [PMID: [20671860](#) DOI: [10.1159/000315621](#)]
- 3 **Kabir S**, Kapetanakis EI, Shabbo F. Intracardiac malignant Triton tumor: a first presentation. *Ann Thorac Surg* 2010; **89**: 968-969 [PMID: [20172170](#) DOI: [10.1016/j.athoracsur.2009.07.052](#)]
- 4 **Bins RB**, Pinzon CE, da Silva Pereira LD, Bertuol M, Isolan PMBS, Takamatu EE. Malignant triton tumor of the kidney in a child: A case report. *Int J Surg Case Rep* 2021; **85**: 106252 [PMID: [34358962](#) DOI: [10.1016/j.ijscr.2021.106252](#)]
- 5 **Liu M**, Bian J. Malignant Triton tumor of the retroperitoneum in a male unaffected by neurofibromatosis 1: A case report and literature review. *Asian J Surg* 2022; **45**: 2766-2768 [PMID: [35725797](#) DOI: [10.1016/j.asjsur.2022.06.030](#)]
- 6 **Jiang TL**, Liu Y, Ji B, Sheng DH, He QC, Song JC, Wang G, Wang K. Malignant triton tumor of uterus: A case report and literature review. *J Clin Ultrasound* 2023 [PMID: [38126255](#) DOI: [10.1002/jcu.23630](#)]
- 7 **Omar T**, Raslan H, El Sheikh S, Rizq M, Draz A. Low-grade malignant triton tumor of the neck: a case report and review of the literature. *Case Rep Pathol* 2014; **2014**: 674094 [PMID: [25328740](#) DOI: [10.1155/2014/674094](#)]
- 8 **Tsagozis P**, Gaston CL, Haglund F, Balko J, Sumathi V, Grimer R, Parry M. The importance of surgical margins in malignant Triton tumour of the trunk and extremities. *Oncol Lett* 2021; **21**: 120 [PMID: [33376551](#) DOI: [10.3892/ol.2020.12381](#)]
- 9 **Brooks JS**, Freeman M, Enterline HT. Malignant "Triton" tumors. Natural history and immunohistochemistry of nine new cases with literature review. *Cancer* 1985; **55**: 2543-2549 [PMID: [3922610](#) DOI: [10.1002/1097-0142\(19850601\)55:11<2543::aid-cnrcr2820551105>3.0.co;2-4](#)]
- 10 **Stasik CJ**, Tawfik O. Malignant peripheral nerve sheath tumor with rhabdomyosarcomatous differentiation (malignant triton tumor). *Arch Pathol Lab Med* 2006; **130**: 1878-1881 [PMID: [17149968](#) DOI: [10.5858/2006-130-1878-MPNSTW](#)]
- 11 **Victoria L**, McCulloch TM, Callaghan EJ, Bauman NM. Malignant triton tumor of the head and neck: A case report and review of the literature. *Head Neck* 1999; **21**: 663-670 [PMID: [10487955](#) DOI: [10.1002/\(sici\)1097-0347\(199910\)21:7<663::aid-hed12>3.0.co;2-4](#)]
- 12 **Kudo M**, Matsumoto M, Terao H. Malignant nerve sheath tumor of acoustic nerve. *Arch Pathol Lab Med* 1983; **107**: 293-297 [PMID: [6687792](#)]
- 13 **Mae K**, Kato Y, Usui K, Abe N, Tsuboi R. A case of malignant peripheral nerve sheath tumor with rhabdomyoblastic differentiation: malignant triton tumor. *Case Rep Dermatol* 2013; **5**: 373-378 [PMID: [24474920](#) DOI: [10.1159/000357610](#)]
- 14 **Johannessen CM**, Reczek EE, James MF, Brems H, Legius E, Cichowski K. The NF1 tumor suppressor critically regulates TSC2 and mTOR. *Proc Natl Acad Sci U S A* 2005; **102**: 8573-8578 [PMID: [15937108](#) DOI: [10.1073/pnas.0503224102](#)]
- 15 **Yang J**, Ylipää A, Sun Y, Zheng H, Chen K, Nykter M, Trent J, Ratner N, Lev DC, Zhang W. Genomic and molecular characterization of malignant peripheral nerve sheath tumor identifies the IGF1R pathway as a primary target for treatment. *Clin Cancer Res* 2011; **17**: 7563-7573 [PMID: [22042973](#) DOI: [10.1158/1078-0432.CCR-11-1707](#)]
- 16 **Ghafari RS**, Hakim NM, Konstantinidis IT, Kafchinski L, Philipovskiy A. A Rare Case of Progressive Malignant Triton Tumor With Rare Somatic Mutation in TSC2 Gene. *Anticancer Res* 2021; **41**: 3029-3036 [PMID: [34083294](#) DOI: [10.21873/anticancer.15085](#)]
- 17 **Merter A**, Başarır K, Yıldız Y, Sağlık Y. Malignant triton tumor of the gluteal region in a patient unaffected by neurofibromatosis: A case report. *Acta Orthop Traumatol Turc* 2018; **52**: 236-239 [PMID: [29110923](#) DOI: [10.1016/j.aott.2017.07.005](#)]
- 18 **Shadad AK**, Sullivan FJ, Martin JD, Egan LJ. Gastrointestinal radiation injury: symptoms, risk factors and mechanisms. *World J Gastroenterol* 2013; **19**: 185-198 [PMID: [23345941](#) DOI: [10.3748/wjg.v19.i2.185](#)]



Published by **Baishideng Publishing Group Inc**
7041 Koll Center Parkway, Suite 160, Pleasanton, CA 94566, USA

Telephone: +1-925-3991568

E-mail: office@baishideng.com

Help Desk: <https://www.f6publishing.com/helpdesk>

<https://www.wjgnet.com>

