



## Rare causes of acute non-variceal upper gastrointestinal bleeding: A comprehensive review

Alberto Martino, Marco Di Serafino, Luigi Orsini, Francesco Giurazza, Roberto Fiorentino, Enrico Crolla, Severo Campione, Carlo Molino, Luigia Romano, Giovanni Lombardi

**Specialty type:** Gastroenterology and hepatology

**Provenance and peer review:** Invited article; Externally peer reviewed.

**Peer-review model:** Single blind

**Peer-review report's scientific quality classification**

Grade A (Excellent): 0  
Grade B (Very good): B, B  
Grade C (Good): 0  
Grade D (Fair): 0  
Grade E (Poor): 0

**P-Reviewer:** Mori H, Belgium; Zhang JW, United Kingdom

**Received:** February 4, 2023

**Peer-review started:** February 4, 2023

**First decision:** April 3, 2023

**Revised:** April 11, 2023

**Accepted:** May 8, 2023

**Article in press:** May 8, 2023

**Published online:** July 21, 2023



**Alberto Martino, Luigi Orsini, Giovanni Lombardi,** Department of Gastroenterology and Digestive Endoscopy, AORN “Antonio Cardarelli”, Naples 80131, Italy

**Marco Di Serafino, Luigia Romano,** Department of General and Emergency Radiology, AORN “Antonio Cardarelli”, Naples 80131, Italy

**Francesco Giurazza,** Department of Interventional Radiology, AORN “Antonio Cardarelli”, Naples 80131, Italy

**Roberto Fiorentino,** Department of Oncology, AORN “Antonio Cardarelli”, Naples 80131, Italy

**Enrico Crolla, Carlo Molino,** Department of Oncological Surgery, AORN “Antonio Cardarelli”, Naples 80131, Italy

**Severo Campione,** Department of Pathology, AORN “Antonio Cardarelli”, Naples 80131, Italy

**Corresponding author:** Alberto Martino, MD, Staff Physician, Department of Gastroenterology and Digestive Endoscopy, AORN “Antonio Cardarelli”, Via Antonio Cardarelli, 9, Naples 80131, Italy. [albertomartinomd@gmail.com](mailto:albertomartinomd@gmail.com)

### Abstract

Non-variceal upper gastrointestinal bleeding (NVUGIB) is a common gastroenterological emergency associated with significant morbidity and mortality. Gastroenterologists and other involved clinicians are generally assisted by international guidelines in its management. However, NVUGIB due to peptic ulcer disease only is mainly addressed by current guidelines, with upper gastrointestinal endoscopy being recommended as the gold standard modality for both diagnosis and treatment. Conversely, the management of rare and extraordinary rare causes of NVUGIB is not covered by current guidelines. Given they are frequently life-threatening conditions, all the involved clinicians, that is emergency physicians, diagnostic and interventional radiologists, surgeons, in addition obviously to gastroenterologists, should be aware of and familiar with their management. Indeed, they typically require a prompt diagnosis and treatment, engaging a dedicated, patient-tailored, multidisciplinary team approach. The aim of our review was to extensively summarize the current evidence with regard to the management of rare and extraordinary rare causes of NVUGIB.

**Key Words:** Gastrointestinal bleeding; Upper gastrointestinal bleeding; Non-variceal upper gastrointestinal bleeding; Rare causes; Vascular causes; Upper endoscopy

©The Author(s) 2023. Published by Baishideng Publishing Group Inc. All rights reserved.

**Core Tip:** Rare and extraordinary rare causes of non-variceal upper gastrointestinal bleeding (NVUGIB) are commonly life-threatening conditions. Thus, a prompt diagnosis and a subsequent equally early treatment are required, typically involving a patient-tailored, multidisciplinary team approach. However, given the rare occurrence, their management is not covered by NVUGIB current guidelines. Our study aimed to review the current evidence with regard to the management of rare and extraordinary rare causes of NVUGIB.

**Citation:** Martino A, Di Serafino M, Orsini L, Giurazza F, Fiorentino R, Crolla E, Campione S, Molino C, Romano L, Lombardi G. Rare causes of acute non-variceal upper gastrointestinal bleeding: A comprehensive review. *World J Gastroenterol* 2023; 29(27): 4222-4235

**URL:** <https://www.wjgnet.com/1007-9327/full/v29/i27/4222.htm>

**DOI:** <https://dx.doi.org/10.3748/wjg.v29.i27.4222>

## INTRODUCTION

Acute upper gastrointestinal bleeding (UGIB) is a common medical emergency with an annual incidence of approximately 50/100000-150/100000 adults[1-3]. It is defined as hemorrhage originating above the ligament of Treitz, in the esophagus, stomach, or duodenum. According to its etiology and reflecting differences in its management, UGIB tends to be subclassified to variceal and non-variceal UGIB (NVUGIB). Peptic ulcer disease (PUD) is the most common cause for UGIB and accounts for approximately 35%-50% of cases, followed by erosive disease, esophagitis and Mallory-Weiss tear. Varices are another common source of UGIB, representing approximately 10% of all UGIB hospitalizations. Less common causes of UGIB include neoplasm, angiodysplasia, gastric antral vascular ectasia and portal hypertensive gastropathy. Finally, up to 5% of all UGIB cases are caused by rare and extraordinary rare sources[1-5].

Despite marked advances in its diagnosis and treatment, UGIB is still associated with high morbidity and mortality. Indeed, the overall mortality rate is approximately 8%-10% in *de novo* UGIB hospitalizations[5,6], increasing up to 40% in high-risk patients[7]. In accordance to current international guidelines, esophagogastroduodenoscopy (EGD) is recommended as the procedure of choice for both diagnosis and treatment of NVUGIB, with transcatheter angiographic embolization (TAE) or surgery only in case of refractory bleeding[8-12]. However, merely NVUGIB due to PUD is largely addressed by current guidelines. Conversely, rare and extraordinary rare NVUGIB causes very often require a dedicated, multidisciplinary approach, in order to provide prompt diagnosis and effective treatment[13-16]. The aim of our review was to summarize and discuss the current evidence with regard to most relevant rare and extraordinary rare causes of NVUGIB, in order to enrich the gastroenterologists and all involved physicians' knowledge of the etiology of NVUGIB and to broaden their judgment in its management.

## RARE CAUSES OF NVUGIB

### Aorto-enteric fistula

First described by Cooper[17], aorto-enteric fistulas (AEF) are rare though life-threatening pathological communications between the aorta and the wall of an adjacent segment of the gastrointestinal (GI) tract. Pathogenesis is still not fully understood, most likely encompassing a combination of infection, aortic and GI wall degeneration, and chronic mechanical pulsatile trauma, finally resulting in erosion and fistula creation[18]. AEF are traditionally classified as either primary (PAEF) or secondary (SAEF). PAEF arise from the native aorta, in the setting most commonly of aortic aneurysm or less frequently of infection, malignancy, foreign bodies, radiation, trauma or inflammation[19]. Conversely, SAEF generally develop as late complication of either surgical or endovascular aortic reconstruction[20]. SAEF are much more common than PAEF, with a reported incidence of 0.3%-1.6% in patients after aortic reconstruction[21] and 0.02%-0.07% among general population[22], respectively. Reported mortality is still extremely high, even with prompt diagnosis and treatment[20].

The most frequent involved site is the duodenum (62%), followed by the jejunum and ileum (12%), and the colon (5%). Aorto-esophageal and aorto-gastric fistula are only rarely encountered[18,20]. The classic triad of NVUGIB, abdominal pain, and pulsatile abdominal mass was initially described by Cooper[17]. However, it is currently believed that the combination of all 3 facets of the triad tends to occur infrequently[19]. The most common clinical presentation of AEF is NVUGIB, with or without sepsis[18]. AEF patients often present with a "sentinel or herald bleed", in which self-limited episodes of bleeding are followed by the recurrence of massive exsanguinous hemorrhage hours or even to days later[23].

Multidetector computed tomography angiography (MDCTA) is the diagnostic modality of choice for AEF[18,24,25]. It has a relatively high sensitivity and specificity for the diagnosis of AEF, approximately of 94% and 85% respectively[25]. Although pathognomonic of AEF, active contrast medium extravasation from the aorta into the GI lumen is an exceptional MDCTA feature usually seen with ongoing exsanguination. MDCTA findings of AEF include para-aortic or intra-aortic foci of gas, loss of the fat plane between the aorta and the GI wall, and disruption of aortic wall or pseudoaneurysm. Moreover, MDCTA signs of SAEF encounter perigraft gas persisting more than 4 wk following repair of ruptured abdominal aortic aneurysm (AAA) and perigraft fluid and edema persisting more than 3 mo after elective AAA repair[24-26]. Although EGD is the first line diagnostic modality in acute NVUGIB, its usefulness in the setting of AEF is limited. AEF may occasionally be suspected by means of EGD, with endoscopic findings suggestive of AEF including visible graft, bleeding, adherent clot, GI wall defect, ulcer/erosion or pulsatile mass[27-29]. However, the experience of the GI endoscopist, a high index of suspicion and the careful exploration of the distal duodenum, are key factors to properly endoscopically identify AEF. Furthermore, given EGD may disturb the clot which had been preventing exsanguinous bleeding from the AEF, it should be performed in the operating theater and its adoption limited to hemodynamically stable patients, with other imaging suggestive of an occult AEF[18]. Among patients admitted with massive NVUGIB and with an history and a clinical presentation suggestive for AEF, emergent MDCTA should be performed as the first-line diagnostic modality.

Treatment of AEF includes either an open surgical or an endovascular approach[30]. Surgery aims to maintain perfusion while extirpating the infection and restoring GI patency. Strategies to maintain perfusion are grouped into *in situ* aortic reconstruction and extra-anatomic bypass with aortic ligation[18]. Conversely, the most commonly used endovascular technique is stent-graft repair[18,25]. Being associated with lower perioperative mortality rate as compared with open surgery, it is frequently adopted as the first-line treatment modality for AEF[20]. Moreover, endovascular balloon occlusion may be used to gain rapid control of the aortic bleeding source in hemodynamically unstable patients. Similarly, coil and plug embolization might be used as a temporizing measure to stop bleeding[18,25]. Of note, surgical and endovascular management of AEF could be integrated in a complementary approach, by the adoption of endovascular treatment as a bridge to open repair[31].

Finally, endoscopic treatment mainly as a part of multidisciplinary approach or as a bridge to definitive therapy has been anecdotally reported. The adopted endoscopic techniques mostly included clips, fully covered self-expanding metal stents, plastic stents and injection therapy[32-35]. However, evidence regarding the role of endoscopic treatment is scarce and it may not be currently recommended. Worth pointing out, especially in the absence of active bleeding (*i.e.*, adherent blood clot), the authors discourage any attempt of endoscopic hemostasis for AEF. Given the recent advent of endoscopic devices capable to realize full-thickness GI defect closure, such as endoscopic suturing systems and over-the-scope clips (OTSC), in the next future endoscopy might probably play a crucial role for the mini-invasive closure of the GI defect after endovascular aortic repair[36]. A case of AEF is shown in Figure 1.

### Ruptured visceral artery aneurysms

First reported in 1809 by Wilson[37], ruptured visceral artery aneurysms (VAA) are a rare but potentially lethal cause of acute NVUGIB. Histopathologically, VAA are broadly divided into true aneurysms (TVAA) and pseudoaneurysms (VAPA). TVAA are defined as focal arterial dilatations greater than 1.5 times the diameter of the original vessel involving all 3 layers of the arterial wall, whereas VAPA, also termed false aneurysms, result from a tear in the vessel wall with extravasated blood contained by only 1 or 2 arterial wall layers[38,39]. The main cause of TVAA is atherosclerosis, followed by fibromuscular dysplasia, connective tissue diseases, inflammatory conditions, and other rare inherited illnesses. Conversely, VAPA may be secondary to trauma, inflammatory conditions such as pancreatitis, cholecystitis, and ulcer, infection, or iatrogenic injury, including surgical, endoscopic and interventional radiological procedures. To be noted, the leading cause of VAPA is chronic pancreatitis (CP). Indeed, more than half of VAPA are secondary to pancreatitis and pseudocyst formation, with up to 17% of CP patients developing VAPA[38,39].

Their reported incidence is approximately 0.1%-2%[38-40]. However, because of the widespread use of advanced imaging techniques and increased aging population, VAA are being incidentally diagnosed with increased frequency[41]. Depending on size, location, and associated clinical conditions (*i.e.*, pregnancy), VAA rupture may be associated with a 20%-80% mortality rate[42].

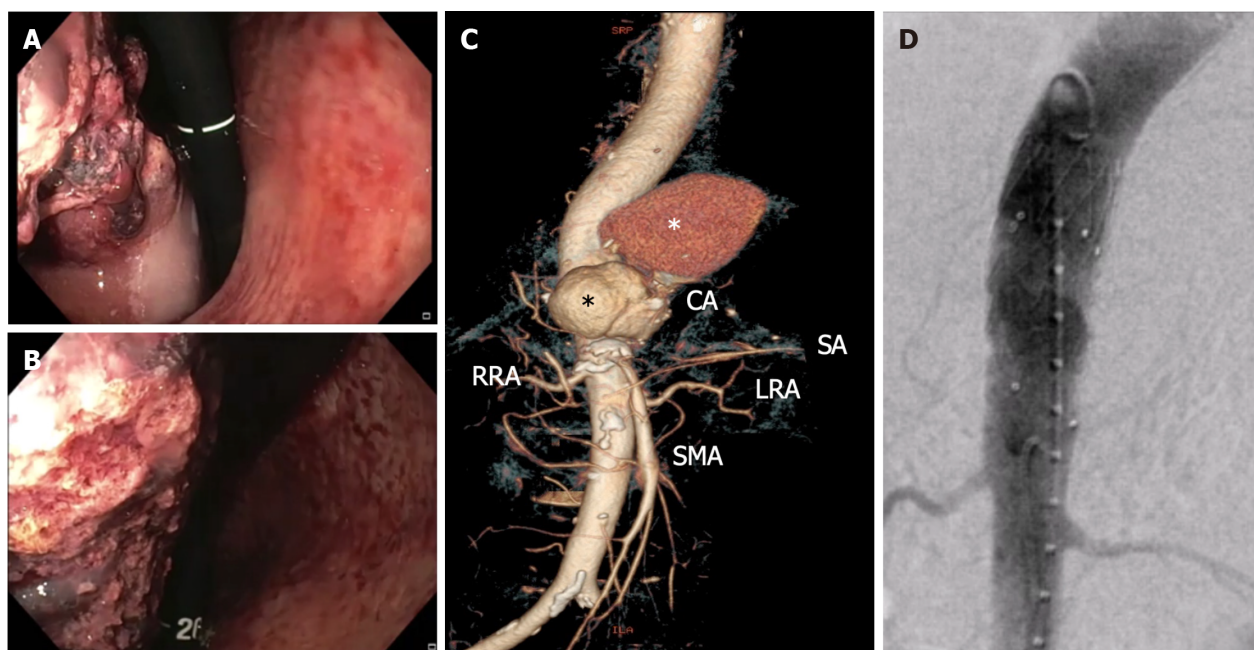
The splenic artery (SA) is the most common site of VAA, followed by the hepatic artery (HA), accounting for nearly 60% and 20% of cases, respectively. Less common sites include in decreasing order of frequency superior mesenteric (SMA) and coeliac arteries (CA). The gastric or gastroepiploic, jejunal-ileal-colic, pancreaticoduodenal (PDA), gastroduodenal (GDA), and inferior mesenteric arteries are rarely involved[39,43].

The natural history of VAA and their potential for rupture or other complications are relatively poorly defined because of their overall scarcity. However, depending on location, size, etiology, subtype, and associated clinical conditions (*i.e.*, pregnancy), the reported risk of rupture ranges widely from 2% up to 80%[42]. Furthermore, pseudoaneurysms, CA, SMA, gastric and gastroepiploic, GDA, PDA and colic aneurysms are associated with a significantly higher risk of rupture regardless of size, requiring prompt treatment upon diagnosis[41,44].

Rupture of VAA occurs more frequently within the GI tract, manifesting with life-threatening NVUGIB, or into the peritoneal cavity. Rupture may less commonly occur into the retroperitoneal space. Finally, rupture within the hepatobiliary tract or the pancreatic duct may be rarely observed, causing hemobilia or hemosuccus pancreaticus (HP), respectively[39,43].

MDCTA is currently regarded as the diagnostic tool of choice, providing accurate vascular anatomy characterization and interventional planning. Indeed, it is frequently regarded as the “new” gold-standard, alongside with angiography[39]. Rupture is seen as an extravasation of contrast medium which is not contained within a round structure and often flows away from the point of injury. On delayed images, there will be washout of the aneurysm, whereas extravasation





DOI: 10.3748/wjg.v29.i27.4222 Copyright ©The Author(s) 2023.

**Figure 1** Non-variceal upper gastrointestinal bleeding due to primary aorto-gastric fistula. A and B: Retroflexed endoscopic view showing gastric bulging mass partially covered by blood clots, originating from the fundus and extending to the posterior wall of the proximal body; C: Three-dimensional computed tomography angiography showing ruptured thoracoabdominal aortic aneurysm (black asterisk), retained by a periaortic hematoma (white asterisk); D: Endovascular stent graft aortic repair. CA: Celiac artery; RRA: Right renal artery; SA: Splenic artery; LRA: Left renal artery; SMA: Superior mesenteric artery.

will persist[39]. Given the common presentation with NVUGIB, patients with ruptured VAA may undergo EGD if hemodynamically stable. However, the role of EGD in this setting is limited, mainly directed to exclude more common sources of NVUGIB. GI rupture of VAA may occasionally be suspected by means of EGD, with unspecific reported endoscopic findings mainly encountering gastric or duodenal ulcer/erosion with or without adherent clot, submucosal bulging mass and visible vessel[45,46]. However, a highly experienced GI endoscopist along with a high index of suspicion are necessary to suspect GI rupture of VAA. Furthermore, a detailed medical history focusing on well known risk factors for VAA development and rupture, including pancreatitis and its local complications, atherosclerosis, and recent traumatic or iatrogenic injury, such as percutaneous or endoscopic ultrasound (EUS)-guided procedures, is crucial in the diagnostic process of ruptured VAA within the GI tract.

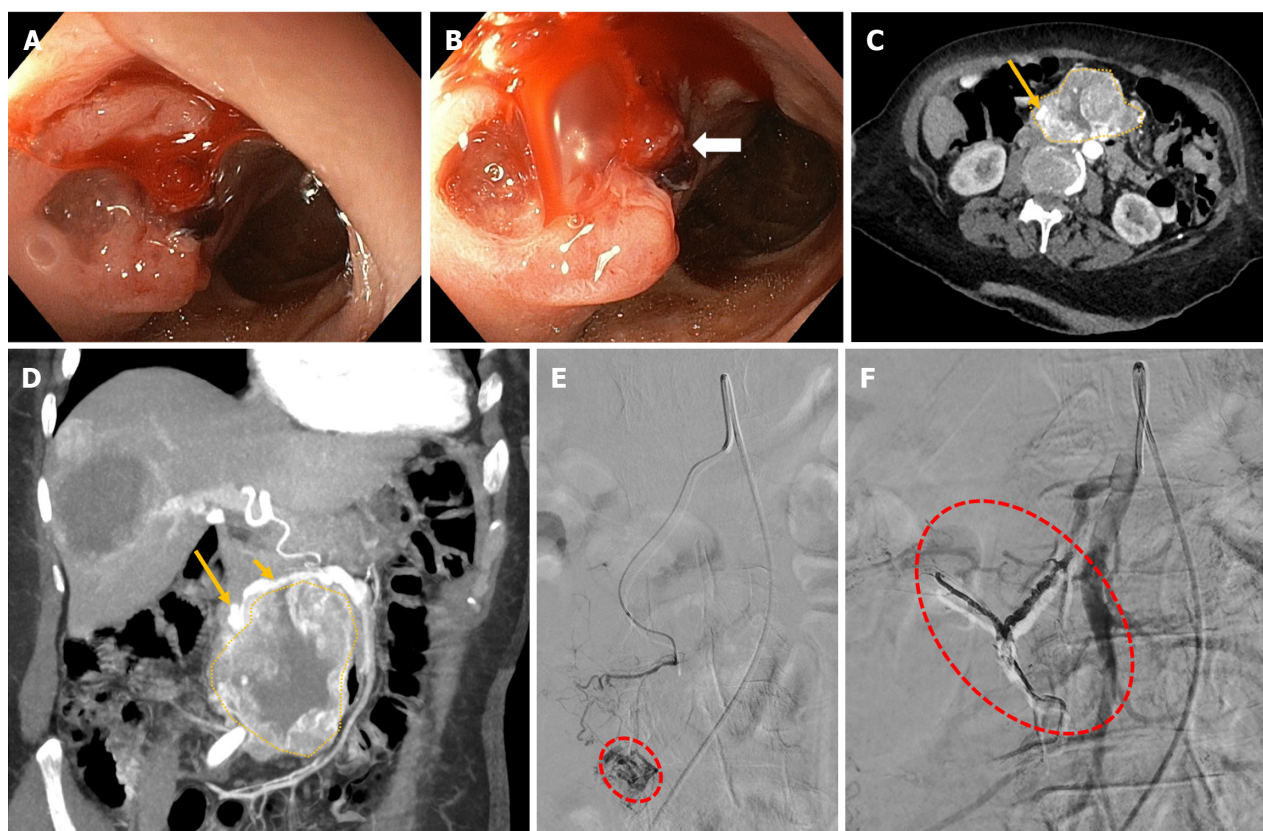
Being associated with lower perioperative morbidity and mortality than open surgery, emergent endovascular treatment, most commonly by means of coil embolization, is currently recommended as the first-line interventional modality for ruptured VAA. Conversely, open surgery is nowadays generally reserved in case of anatomically unfeasible or failed EVT[41,44]. To date, endoscopy plays no role in the treatment of ruptured VAA. Endoscopic cyanoacrylate or epinephrine injection has been anecdotally reported[45,46]. However, we do not recommend endoscopic hemostasis attempt when GI VAA rupture is suspected or diagnosed, especially in the absence of active bleeding during endoscopic examination. Finally, EUS-guided embolization by the use of thrombin or glue injection, alone or in combination with coil deployment, has been successfully reported for the treatment of VAPA[47-49]. Although evidence is currently lacking, with growing experience, EUS-guided obliteration could represent a minimally-invasive and fashionable alternative to an endovascular approach for the treatment of selected ruptured VAPA among referral centers[50]. A case of rupture of VAA into the GI tract is shown in [Figure 2](#).

### Gastric submucosal arterial collaterals

First reported by Spriggs[51] in 1984, bleeding gastric submucosal arterial collaterals (GSAC) are an extraordinary rare cause of severe NVUGIB, with only few cases reported up to date, including a fatal one[52]. They result from either occlusion or congenital absence of the SA, being not related to portal hypertension. SA occlusion may be congenital, idiopathic, or secondary to various conditions, including surgery, endovascular intervention, trauma and extrinsic compression. In the case of SA occlusion, in order to provide splenic blood supply, extensive collaterals may arise from adjacent proximal patent arteries, such as the pancreatic, left gastric, gastroepiploic, and short gastric arteries, and pass through the gastric wall[53]. GSAC may be clinically asymptomatic or may less frequently present with severe NVUGIB from erosion of GSAC.

Since GSAC appear endoscopically as varicose shaped and tortuous submucosal vessels located at the gastric fundus [52], the differential diagnosis mainly includes type 1 isolated gastric varices (IGV)[54]. Indeed, GSAC have a very similar endoscopic appearance to IGV, being frequently misinterpreted on EGD[52]. However, they are, as opposed to GSAC, secondary to cirrhotic portal hypertension or left-sided portal hypertension[54]. Therefore, given their different management, an accurate differential diagnosis between these two entities is crucial. Indeed, endoscopic cyanoacrylate





DOI: 10.3748/wjg.v29.i27.4222 Copyright ©The Author(s) 2023.

**Figure 2** Non-variceal upper gastrointestinal bleeding due rupture of a superior mesenteric artery pseudoaneurysm into the duodenum. A and B: Upper endoscopy showing a bulging, focally ulcerated, lesion in the second-third part of the duodenum, with a suspected small fistulous orifice on its surface (arrow); C and D: Contrast-enhanced computed tomography axial scan in the arterial phase (C) and its maximum intensity projection oblique-coronal reconstruction (D) showing a large lesion (dotted area, C and D) arising from the second-third part of the duodenum, with peripheral vascularity and a pseudoaneurysm (long arrow, C and D) arising from branches of the superior mesenteric artery (short arrow, B); E: Superselective superior mesenteric artery angiography showing a pseudoaneurysm (red dotted circle) fed by the inferior pancreaticoduodenal artery; F: Successful endovascular embolization by the use of cohesive glue (Onyx-18®, Medtronic, Dublin, Ireland) with disappearance of the pseudoaneurysm and visibility of the Onyx-18® cast (red dotted circle).

glue injection (ECGI), currently recommended as the first-line therapeutic option for bleeding IGV[55], may be complicated by systemic embolization and life-threatening adverse events when applied to an arterial source[56,57]. Conversely, being potentially associated with severe adverse events, endoscopic mechanical hemostasis is currently not recommended for the treatment of IGV[55].

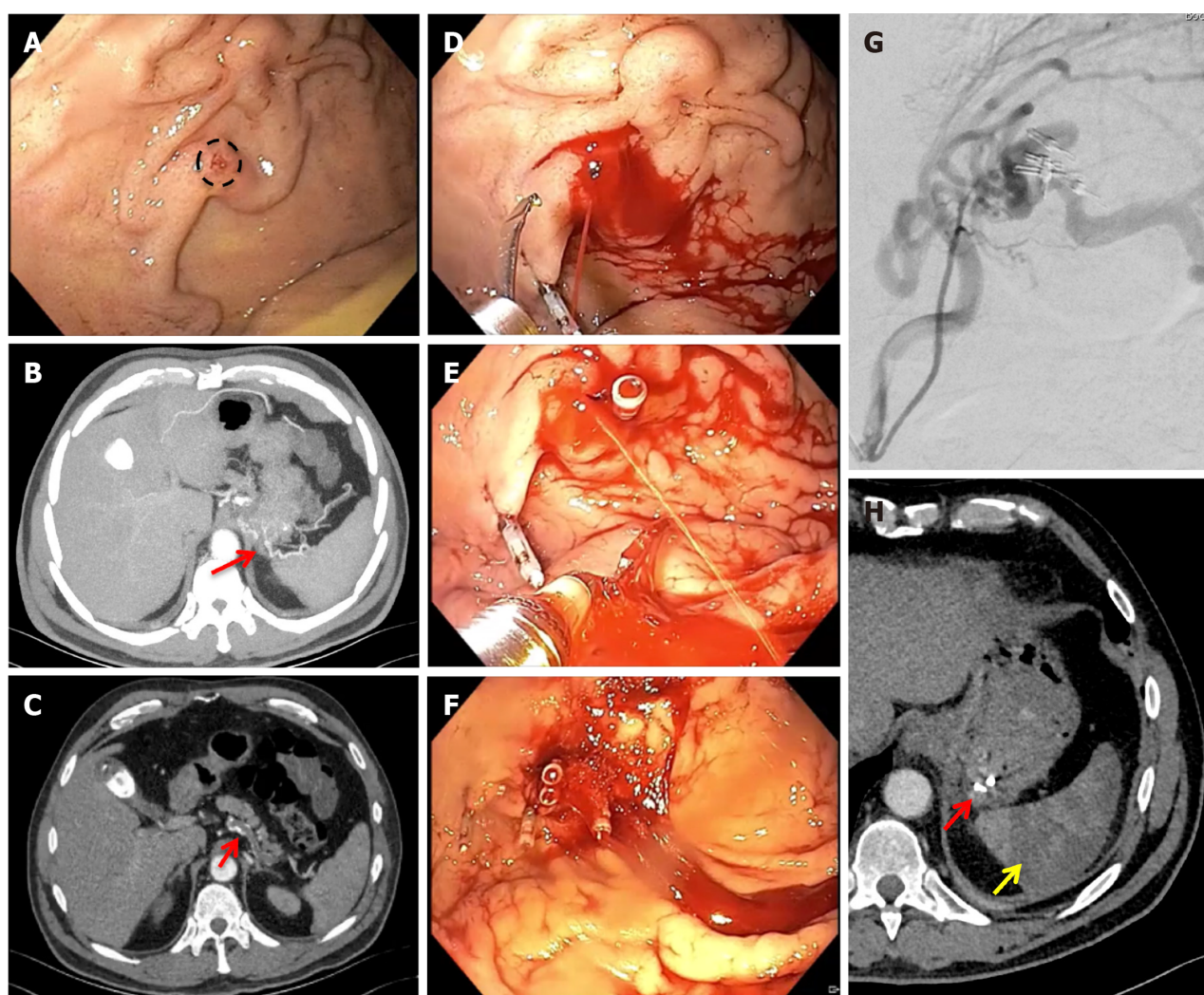
Proper diagnosis is only made by MDCTA and/or digital subtraction angiography (DSA)[52]. Thus, in case of endoscopic evidence of fundal varicose shaped submucosal vessels among UGIB patients without portal hypertension history or clinico-laboratory signs, emergent MDCTA should be performed prior to any endoscopic treatment attempt, if feasible (*i.e.*, absence of active bleeding at the time of EGD).

Definitive treatment is mainly represented by surgical splenectomy and arterial ligation with or without gastrectomy. However, effective treatment by means of endovascular embolization has also been reported. As mentioned before, endoscopic mechanical hemostasis rather than ECGI may be used for the bleeding control among experienced centers, if needed, mainly in a step-up approach[52]. A case of bleeding GSAC is shown in Figure 3.

### Dieulafoy's lesions

Dieulafoy's lesion (DL) is a rare cause of acute NVUGIB, accounting for approximately 1.5% of cases, with a tendency to cause severe, life-threatening, recurrent GI bleeding[58,59]. It was originally reported by Gallard[60] in 1884 and subsequently referred to as "exulceratio simplex" in 1898 by the French surgeon Dieulafoy[61], who believed it was the first stage of a gastric ulcer. DL is a vascular abnormality, consisting of a pathologically dilated submucosal caliber-persistent artery, that typically protrudes through a small 2-5 mm mucosal defect and erodes into the GI lumen, in the absence of any abnormality such as ulcers, erosions or aneurysms[58,59]. Similarly to primary AEF, DL bleeding is thought to occur as a result of the mucosal surface disruption due to the persistent mechanical pressure perpetrated by the underlying submucosal ectatic artery[58,59].

The mortality has markedly declined from up to 80% during the pre-endoscopy era to 9%-13% currently with advances in endoscopic hemostasis[58,59]. The most common DL site is by far the stomach, typically the proximal lesser curvature within 6 cm from the gastroesophageal junction[58]. This predilection may be related to the local blood supply. Indeed, the gastric lesser curve is not irrigated by a submucosal plexus, receiving its arterial blood supply directly from the branches of the left and right gastric arteries[62]. Other less common locations include in decreasing order of frequency



DOI: 10.3748/wjg.v29.i27.4222 Copyright ©The Author(s) 2023.

**Figure 3 Non-variceal upper gastrointestinal bleeding due to gastric submucosal arterial collaterals secondary to splenic artery thrombosis.** A: Retroflexed endoscopic view of the gastric fundus showing varicose-shaped submucosal vessels with a small erosion (circle), in the absence of active bleeding; B and C: Pre-operative axial computed tomography arterial phase showing an arterial cluster at the gastric fundus (B: arrow) arising from splenic artery collateral vessels due to splenic artery complete thrombosis (C: arrow); D-F: Successful endoscopic mechanical hemostasis attempt, with intraprocedural spurting active bleeding following first endoclip application (D and E); G: Operative angiography with selective arterial embolization using microspheres; H: Post-operative axial computed tomography arterial phase showing gastric vascular lesion exclusion (red arrow) and splenic infarction (yellow arrow).

the duodenum, the colon, surgical anastomoses, the small bowel, and the esophagus[58].

Given the arterial nature of the bleeding, typical clinical presentation of DL include severe painless NVUGIB, most commonly manifesting with both hematemesis and melena and frequently associated with signs of hemodynamic instability[59]. In the absence of prompt treatment, recurrent bleeding within 72 h after the initial bleed is frequently observed, being commonly more severe. If unidentified and left untreated, DL mortality is extremely high[63].

Endoscopy is the first-line diagnostic modality and is regarded as the gold standard method for the diagnosis of DL[58, 59]. The reported endoscopic criteria for the diagnosis of DL include: (1) Active arterial spurting bleeding from a small (< 3 mm) mucosal defect or through normal mucosa; (2) Protruding vessel, with or without active bleeding, within a small mucosal defect or normal mucosa; or (3) Fresh adherent clot to a minute mucosal defect or to normal-appearing mucosa [64]. However, the reported diagnostic yield of initial EGD is only 70%, and repeat endoscopic examinations may thus be required. Main reasons for diagnostic failure of EGD encounter small lesion size, intermittently active bleeding, DL site between folds or underneath an adherent clot, or presence of a large amount of fresh blood within the gastric cavity[65]. Thus, especially in the setting of non-actively bleeding DL, endoscopic diagnosis may be challenging and a high index of clinical suspicion is required. A meticulous examination especially of the gastric cardia should be performed during EGD. In addition to adequate insufflation, in case of negative EGD, the execution of a provocative endoscopy by the use of water-jet irrigation to target wash as much of the gastric cardia as possible, particularly along the lesser curvature, has been suggested in order to disrupt a fibrin plug and provoke active bleeding from an underlying DL[15]. Of interest, in the setting of non-active bleeding, EUS may be useful to confirm the diagnosis of DL, being capable to clearly depict the pathological submucosal vessel penetrating the muscularis propria[66].



Further diagnostic modalities include MDCTA and DSA. MDCTA findings encounter abnormally enlarged submucosal vessel, which may appear tortuous, linear or as a non-specific “blush” of contrast medium at the mucosal/submucosal level[14]. However, diagnosis of DL by the use of MDCTA is usually challenging, and requires highly experienced radiologists. Conversely, angiographically, DL appears as a non-tapering, tortuous vessels in the arterial phase with no early venous return, with or without contrast medium extravasation within the GI tract[67].

Treatment is recommended for virtually all identified DL, even in the absence of recent bleeding stigmata. Dual combination endoscopic therapy with epinephrine injection followed by mechanical or thermal contact hemostasis is recommended as the first-line treatment modality for DL, being effective in more than 90% of cases. Although requiring higher endoscopic skill and experience, especially if performed in a gastric retroflexion position as frequently needed, mechanical therapy by means of band ligation or endoclip placement is currently favored over thermal hemostasis[59]. Moreover, given the risk of perforation, especially in GI tracts with thin walls such as the gastric fundus, and the risk of bands drop off with rebleeding, endoscopic band ligation may be less desirable than endoscopic clipping, especially in inexperienced hands[59,68]. Finally, mechanical hemostasis by means of OTSC has been successfully reported with good outcomes, not only for refractory cases[69,70].

If feasible (*i.e.*, absence of active bleeding), the so called acoustic Doppler mapping technique, by the use of a through-the-scope endoscopic Doppler ultrasound (DopUS) probe to delineate the subsurface route and path of the pathologically large-caliber artery, may be performed prior to endoscopic treatment, in order to treat the entire length of the superficially located artery, thus maximizing its efficacy. Furthermore, following endoscopic hemostasis achievement, the DopUS may be used to show the blood flow cessation, thus proving the successful eradication of the lesion[71].

Worth mentioning, endoscopic tattooing of the DL site should also be performed, in order to facilitate endoscopic or surgical localization in case of rebleeding occurrence[58,59]. Intriguingly, various EUS-guided treatments have been reported with good outcomes among case reports and small case series, mainly in the setting of DL refractory to standard endoscopic hemostasis. As previously mentioned, despite standard endoscopic treatment, complete ablation of a DL may be accurately evaluated at the end of treatment by Doppler EUS showing the absence of blood flow in the targeted vessel. However, up to date, evidence is still anecdotal and their adoption should be limited to referral centers in a research context[72]. TAE represents a useful second-line treatment modality, whereas surgical wedge resection has currently become the last resort for uncontrolled or unidentified DL bleeding[58,59]. A case of DL is shown in [Figure 4](#).

### Cameron lesions

Initially reported by Truesdale[73] in 1924 and subsequently extensively illustrated by Cameron[74] in 1976, Cameron lesions (CL) refer to linear gastric erosions or ulcerations located on the mucosal folds at the distal neck of a hiatal hernia (HH), in close proximity to the diaphragmatic impression. CL are thought to occur as a result of mechanical trauma and local ischemia, secondary to repetitive movement of the hernia sac against the diaphragm during respiratory excursions, and acid injury[75]. Their estimated prevalence is between 3% and 5% in the presence of a HH, reaching up to 10%-20% among patients with large HH (> 5 cm)[76-78]. Moreover, they have been reported to be the source of overt UGIB in 0.2% of cases[79].

Although commonly incidentally diagnosed during EGD, CL may clinically present with either acute or chronic NVUGIB[75,80]. EGD is considered the gold standard for the diagnosis of CL. However, they may often be missed at the index EGD[81,82]. Meticulous endoscopic evaluation of the HH neck and sac, especially in a retroflexed view, is thus required.

Although technically demanding, due to CL anatomical location requiring a retroflexed position and the movement of the HH sac with respiration, endoscopic hemostasis is indicated in case of active bleeding, visible vessel or adherent clot, similarly to peptic ulcers. Injection of epinephrine, thermal contact therapy, clipping and band ligation may be adopted [14,83,13]. However, because of the thin wall and the lack of fibrous support tissue in the gastroesophageal junction, caution is needed when attempting endoscopic therapy, given the potential risk of deep ulcer or perforation[15,75]. Finally, a surgical approach with laparoscopic or open fundoplication should be considered in patients with refractory or recurrent CL bleeding[75,80]. A case of CL is shown in [Figure 5](#).

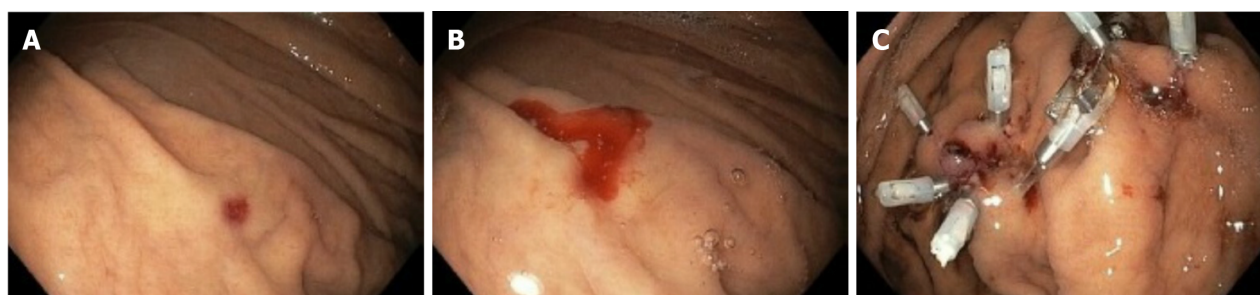### HP

First described in 1931 by Lower and Farrell[84], HP is an exceptionally rare cause of potentially fatal NVUGIB, with a reported incidence of about one in 1500 cases[85]. Also referred to as pseudohemobilia or wirsungorrhagia, the term HP was coined in 1970 by Sandblom[86]. It is defined as bleeding within the pancreatic duct exteriorizing through the major duodenal papilla. Of note, hemorrhage can also occur *via* the minor duodenal papilla, also known as santorinorrhage, in case of pancreas divisum. The reported mortality rate of HP is high, reaching up to approximately 10%[85]. If untreated, the mortality rate may increase up to 90%[87].

HP is commonly observed among patients with an history of pancreatic diseases, mainly including acute or CP and less frequently pancreatic neoplasms[87]. The most common cause of HP is ruptured VAPA[87]. Indeed, VAPA formation and rupture in the setting of pancreatitis, are thought to be secondary to local leakage of proteolytic enzymes with destruction of the arterial wall. Alternatively, they may also result from erosion of nearby pseudocysts or walled-off necrosis into adjacent arteries[88]. Given its close anatomical relationship with the pancreas, SA is the most common involved site of pseudoaneurysm, followed by the GDA, the PDA, and the HA[87]. Less common causes of HP include pancreatic neoplasms, pseudocysts, pancreas divisum, vascular malformations, TVAA, and traumatic or iatrogenic injuries, including endoscopic retrograde cholangiopancreatography (ERCP) and EUS interventional procedures[87,88].

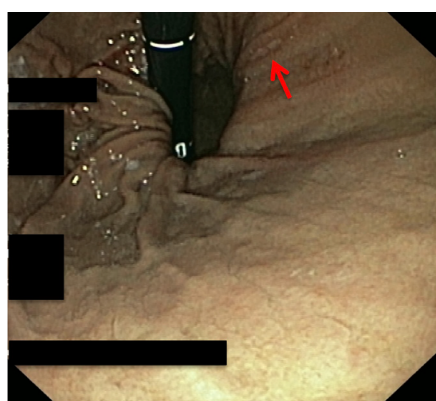
The classical Sandblom's triad of clinical presentation associated with HP consists of abdominal pain radiating to the back, intermittent UGIB manifesting as melena, hematemesis, and rarely, hematochezia, and hyperamylasemia[86]. Pain is secondary to transient increase in intraductal pancreatic pressure due pancreatic duct obstruction from blood clot. It is





DOI: 10.3748/wjg.v29.i27.4222 Copyright ©The Author(s) 2023.

**Figure 4 Non-variceal upper gastrointestinal bleeding due to Dieulafoy's lesion.** A: Retroflexed endoscopic view of the gastric fundus showing a minute mucosal defect, surrounded by normal-appearing mucosa, without active bleeding; B: Active bleeding following provocative water-jet endoscopic irrigation; C: Successful endoscopic mechanical hemostasis.



DOI: 10.3748/wjg.v29.i27.4222 Copyright ©The Author(s) 2023.

**Figure 5 Non-variceal upper gastrointestinal bleeding due to Cameron lesion.** Retroflexed endoscopic view of the gastric fundus showing a fibrin covered linear erosion (arrow) at the end of a large hiatal hernia.

alleviated following bleeding episodes, due to clots clearance. Icterus from retrograde biliary obstruction may also occur [88].

Diagnosis of HP is challenging, requiring a multidisciplinary and integrative approach. Given the hidden and intermittent nature of the bleeding and its anatomical location, EGD was reported to be able to directly visualize active bleeding *via* the major duodenal papilla in only about 30%-75% of cases [87,88]. Suspicion for HP should be increased by indirect signs of bleeding, including clots within the duodenum in the absence of an alternative explanation. Furthermore, when HP is suspected, repeated endoscopy and the adjunct of a duodenoscope to properly visualize the major papilla are often necessary to establish the diagnosis [87,88].

ERCP may highlight filling defects within the pancreatic ducts, favoring the diagnosis. However, being associated with potential bleeding worsening and pancreatic duct disruption, and having a limited therapeutic role especially in the setting of ruptured VAPA, ERCP is generally not recommended for the diagnosis and treatment of HP [15,89].

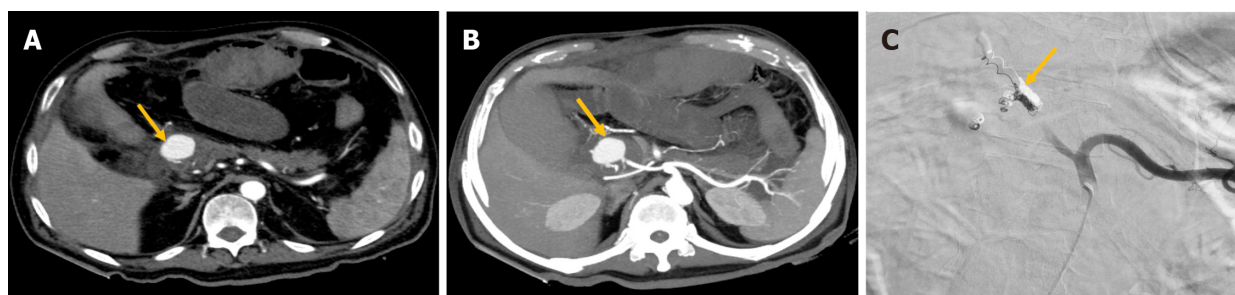
Intriguingly, EUS has been shown to be a promising tool in the diagnosis of HP, being capable to clearly depict bleeding within the pancreatic duct and its underlying cause [90,91]. Among experienced centers, EUS could be performed immediately after EGD in suspected cases, in order to provide prompt diagnosis and treatment.

MDCTA represents a very useful diagnostic tool for HP, providing characterization of the local anatomy, detection of bleeding within the pancreatic duct and its underlying etiology, thus effectively guiding further management in most of cases [15,87,88]. On pre-contrast MDCTA, the characteristic feature of clotted blood within the pancreatic duct, known as the sentinel clot sign, may also be observed. However, the diagnostic gold standard for HP is currently represented by DSA [87,88].

Percutaneous endovascular treatment, mainly by means of TAE, is currently recommended as the first choice of treatment for HP, with surgery being reserved for patients with persistent hemodynamic instability and unsuccessful embolization [89]. Although therapeutic ECRP with pancreatic multistenting has been successfully reported for the tamponade of a iatrogenic post-ERCP case of HP, its adoption may not be recommended, especially in the setting of ruptured VAPA [92]. Finally, the promising role of EUS-guided embolization in the treatment of VAPA has been previously discussed. A case of HP is shown in Figure 6.

### Hemobilia

First described in 1654 by Glisson [93] on autopsy, hemobilia is defined as bleeding into the intra- or extra-hepatic biliary system exteriorizing *via* the major duodenal papilla. It occurs as a result of a fistula formation between a splanchnic blood



DOI: 10.3748/wjg.v29.i27.4222 Copyright ©The Author(s) 2023.

**Figure 6** Non-variceal upper gastrointestinal bleeding due to hemosuccus pancreaticus. A and B: Contrast-enhanced computed tomography axial scan in the arterial phase (A) and its maximum intensity projection axial reconstruction (B) showing a large pancreaticoduodenal artery pseudoaneurysm (arrow, A and B); C: Successful endovascular coil embolization (arrow).

vessel and the biliary system. Arterial vessels are more commonly involved, due to their higher intravascular pressure. However, biliary venous fistulas have also been reported, especially in the setting of portal hypertension[94].

Due to their increased adoption, the most common reported etiology of hemobilia is currently represented by iatrogenic causes involving hepatopancreatobiliary (HPB) manipulation, including percutaneous radiological interventions, ERCP, interventional EUS, and HPB surgery. In these situations, hemobilia may be secondary to traumatic arteriobiliary fistula formation or less frequently to rupture of a HA, or rarely cystic artery, pseudoaneurysm. Less common etiologies include traumatogenic causes, HPB malignancies, portal biliopathy, chronic ductal obstruction, inflammatory conditions, such as cholecystitis, gallstone disease, ruptured HA true aneurysms, and intraductal infection[94].

The classic clinical presentation of hemobilia is Quincke's triad, consisting of right upper quadrant pain, jaundice and UGIB[95], but all three findings are simultaneously observed in only 22%-35% of cases[94,96]. The diagnosis of hemobilia may be challenging and a high index of suspicion, mainly based on a patient's clinical presentation and suggestive medical history, is crucial. Furthermore, as with HP, bleeding can be intermittent and difficult to visualize endoscopically, even with the use of a side-viewing endoscope or a forward-viewing endoscope with distal attachment cap[94,96]. ERCP can improve diagnosis by detecting findings suggestive of hemobilia, such as amorphous, tubular, or cast-like filling defects with unexplained dilation of the common or perihilar bile duct[97]. However, it is rarely performed with a solely diagnostic intent. Of note, the use of per oral cholangioscopy has been suggested in the management of unexplained hemobilia[98]. Finally, a promising role of EUS in the diagnosis of hemobilia has been reported. Indeed, EUS was shown to be able to detect aneurysm or pseudoaneurysm in the hepatic vasculature, presence of blood within the gallbladder and common bile duct, presenting as mobile hyperechoic material, and bleeding from intra- and para-choledochal varices in portal biliopathy[99-102].

In hemodynamically stable patients with suspected major hemobilia, MDCTA should be performed in order to rule out vascular complications, such as HA aneurysms, pseudoaneurysms and cholangiovenous or arterio-ductal fistulas, and thus guiding further management[94,96].

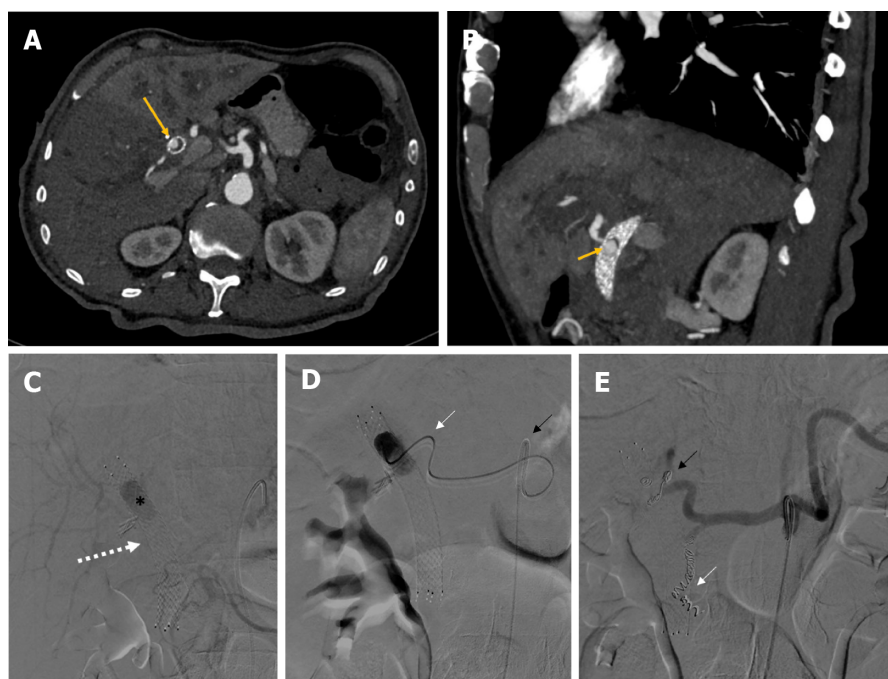
The aim of treatment consists of both hemorrhage control and maintenance of biliary patency. In the absence of vascular complications detected by MDCTA, ERCP is commonly the initial therapeutic procedure of choice, being able to provide simultaneous management of both bleeding and biliary obstruction[94,96]. Several endoscopic hemostatic techniques have been reported, varying according to etiology, location, and source of hemobilia. In case of post-sphincterotomy hemobilia, which typically is a result of injury to the posterior branch of the superior PDA, or distal hemobilia, hemostasis may be achieved by epinephrine spraying or injection, monopolar or bipolar coagulation, fibrin sealant injection, clipping, balloon tamponade, and stenting. Conversely, biliary stenting is the preferred option for proximal hemobilia[94,96]. In selected cases, biliary stents are capable to achieve immediate hemostasis, by creating a tamponade effect on the biliary wall, while maintaining luminal patency and thus bile flow. Of note, as compared with plastic stents, fully covered self-expanding metallic stents appear to have superior tamponade effect and greater patency, and should be favored in this setting[103-105]. Finally, ERCP may provide bile flow restoration, by directly extracting intraductal blood clots and/or by biliary stenting, thus preventing complications related to biliary obstruction[94,96].

In case of vascular complications, refractory hemodynamic instability, or endoscopic treatment failure, interventional radiology is recommended[94,96]. TAE is the most widely adopted technique. However, it is contraindicated in liver transplant recipients, portal vein thrombosis, and cirrhosis with concomitant shock, due to compromised collateral blood flow from the portal vein and the consequent risk of severe hepatic ischemia. In this setting, arterial stenting should be preferred[106].

Intriguingly, EUS-guided obliteration has been recently successfully reported also in the setting of hemobilia due to cystic artery pseudoaneurysm[107]. Surgery is typically reserved as a last resort, due to its high morbidity and mortality rate[94,96]. A case of hemobilia is shown in Figure 7.

## CONCLUSION

Upper GI endoscopy is currently recommended as the gold standard modality for both diagnosis and treatment of



DOI: 10.3748/wjg.v29.i27.4222 Copyright ©The Author(s) 2023.

**Figure 7 Non-variceal upper gastrointestinal bleeding due to hemobilia.** A and B: Contrast-enhanced computed tomography axial scan in the arterial phase (A) and its maximum intensity projection oblique-sagittal reconstruction (B) showing a pseudoaneurysm in the lumen of the metallic biliary stent (long arrow, A), arising from the hepatic artery (short arrow, B); C: Delayed phase celiac angiography showing a pseudoaneurysm (black asterisk) into the lumen of a metallic biliary stent (white arrow); D: The pseudoaneurysm of the proper hepatic artery was reached with a 2.7 Fr microcatheter (white arrow) coaxially through a 5 Fr catheter (black arrow) positioned into the celiac trunk; E: Successful coil embolization of both the proper hepatic artery (black arrow) and the gastroduodenal artery (white arrow), in order to avoid recanalization.

NVUGIB. However, NVUGIB due to PUD only is mainly addressed by current international guidelines, whereas rare causes of NVUGIB are not covered due to their scarcity. In these instances, EGD may often not represent the gold standard for the diagnosis and may not have any role in their treatment. Conversely, a multidisciplinary approach involving not only the GI endoscopists, but also the diagnostic and the interventional radiologists, and the general and the vascular surgeons, is in most cases needed for both diagnosis and treatment. Nevertheless, EGD is inevitably the most frequently first diagnostic modality performed or requested even in NVUGIB due to rare causes. Thus, the GI endoscopists are commonly the main actors in driving further diagnostic and therapeutic process, rising the suspect of rare NVUGIB causes when appropriated. In this setting, the diagnostic role of EGD is commonly limited, mainly directed to exclude common causes of NVUGIB, whereas the diagnostic gold standard is frequently represented by MDCTA and/or DSA.

Worth mentioning, NVUGIB due to rare causes are generally associated with morbidity and mortality significantly higher as compared with those secondary to common sources. Moreover, given any delay in proper diagnosis and/or treatment is inevitably associated with increased mortality, a prompt and effective management is crucial. Thus, not only the gastroenterologists, frequently the first actors involved in the management of NVUGIB due to both common and uncommon causes, should be aware and very confident with rare NVUGIB causes, but also the diagnostic and the interventional radiologists, and the general and the vascular surgeons.

Finally, a multidisciplinary, patient-tailored, and minimally-invasive, when feasible, approach should be pursued for the management of most of the rare NVUGIB causes. Given their complexity, often requiring a strict cooperation between different specialists, rare and extraordinary rare causes of NVUGIB should be desirably managed among highly-experienced referral centers.

## ACKNOWLEDGEMENTS

We are grateful to Velia De Magistris for English editing.

## FOOTNOTES

**Author contributions:** Martino A, Di Serafino M, and Orsini L designed research and wrote, edited and finalized the text; Martino A, Di Serafino M, Orsini L, Giurazza F, Fiorentino R, Crolla E, and Campione S performed literature search and analyzed the data; Molino C, Romano L, and Lombardi G reviewed the paper for important intellectual content.



**Conflict-of-interest statement:** All the authors report no relevant conflicts of interest for this article.

**Open-Access:** This article is an open-access article that was selected by an in-house editor and fully peer-reviewed by external reviewers. It is distributed in accordance with the Creative Commons Attribution NonCommercial (CC BY-NC 4.0) license, which permits others to distribute, remix, adapt, build upon this work non-commercially, and license their derivative works on different terms, provided the original work is properly cited and the use is non-commercial. See: <https://creativecommons.org/licenses/by-nc/4.0/>

**Country/Territory of origin:** Italy

**ORCID number:** Alberto Martino 0000-0002-8759-6518; Marco Di Serafino 0000-0001-6972-1859; Luigi Orsini 0000-0001-7029-3994; Francesco Giurazza 0000-0002-9080-8833; Enrico Crolla 0000-0001-7997-2715; Luigia Romano 0000-0002-5201-547X; Giovanni Lombardi 0000-0002-5957-3132.

**S-Editor:** Wang JJ

**L-Editor:** A

**P-Editor:** Zhang XD

## REFERENCES

- Enestvedt BK, Gralnek IM, Mattek N, Lieberman DA, Eisen G. An evaluation of endoscopic indications and findings related to nonvariceal upper-GI hemorrhage in a large multicenter consortium. *Gastrointest Endosc* 2008; **67**: 422-429 [PMID: 18206878 DOI: 10.1016/j.gie.2007.09.024]
- Tielleman T, Bujanda D, Cryer B. Epidemiology and Risk Factors for Upper Gastrointestinal Bleeding. *Gastrointest Endosc Clin N Am* 2015; **25**: 415-428 [PMID: 26142028 DOI: 10.1016/j.giec.2015.02.010]
- Wuerth BA, Rockey DC. Changing Epidemiology of Upper Gastrointestinal Hemorrhage in the Last Decade: A Nationwide Analysis. *Dig Dis Sci* 2018; **63**: 1286-1293 [PMID: 29282637 DOI: 10.1007/s10620-017-4882-6]
- British Society of Gastroenterology Endoscopy Committee. Non-variceal upper gastrointestinal haemorrhage: guidelines. *Gut* 2002; **51** Suppl 4: iv1-iv6 [PMID: 12208839 DOI: 10.1136/gut.51.suppl\_4.iv1]
- Oakland K. Changing epidemiology and etiology of upper and lower gastrointestinal bleeding. *Best Pract Res Clin Gastroenterol* 2019; **42-43**: 101610 [PMID: 31785737 DOI: 10.1016/j.bpg.2019.04.003]
- Hearnshaw SA, Logan RF, Lowe D, Travis SP, Murphy MF, Palmer KR. Acute upper gastrointestinal bleeding in the UK: patient characteristics, diagnoses and outcomes in the 2007 UK audit. *Gut* 2011; **60**: 1327-1335 [PMID: 21490373 DOI: 10.1136/gut.2010.228437]
- Walker TG. Acute gastrointestinal hemorrhage. *Tech Vasc Interv Radiol* 2009; **12**: 80-91 [PMID: 19853226 DOI: 10.1053/j.tvir.2009.08.002]
- Laine L, Barkun AN, Saltzman JR, Martel M, Leontiadis GI. ACG Clinical Guideline: Upper Gastrointestinal and Ulcer Bleeding. *Am J Gastroenterol* 2021; **116**: 899-917 [PMID: 33929377 DOI: 10.14309/ajg.0000000000001245]
- Gralnek IM, Stanley AJ, Morris AJ, Camus M, Lau J, Lanas A, Laursen SB, Radaelli F, Papanikolaou IS, Cúrdia Gonçalves T, Dinis-Ribeiro M, Awadie H, Braun G, de Groot N, Udd M, Sanchez-Yague A, Neeman Z, van Hooft JE. Endoscopic diagnosis and management of nonvariceal upper gastrointestinal hemorrhage (NVUGIH): European Society of Gastrointestinal Endoscopy (ESGE) Guideline - Update 2021. *Endoscopy* 2021; **53**: 300-332 [PMID: 33567467 DOI: 10.1055/a-1369-5274]
- Sung JJ, Chiu PW, Chan FKL, Lau JY, Goh KL, Ho LH, Jung HY, Sollano JD, Gotoda T, Reddy N, Singh R, Sugano K, Wu KC, Wu CY, Bjorkman DJ, Jensen DM, Kuipers EJ, Lanas A. Asia-Pacific working group consensus on non-variceal upper gastrointestinal bleeding: an update 2018. *Gut* 2018; **67**: 1757-1768 [PMID: 29691276 DOI: 10.1136/gutjnl-2018-316276]
- Mullady DK, Wang AY, Waschke KA. AGA Clinical Practice Update on Endoscopic Therapies for Non-Variceal Upper Gastrointestinal Bleeding: Expert Review. *Gastroenterology* 2020; **159**: 1120-1128 [PMID: 32574620 DOI: 10.1053/j.gastro.2020.05.095]
- Barkun AN, Almadi M, Kuipers EJ, Laine L, Sung J, Tse F, Leontiadis GI, Abraham NS, Calvet X, Chan FKL, Douketis J, Enns R, Gralnek IM, Jairath V, Jensen D, Lau J, Lip GYH, Loffroy R, Maluf-Filho F, Meltzer AC, Reddy N, Saltzman JR, Marshall JK, Bardou M. Management of Nonvariceal Upper Gastrointestinal Bleeding: Guideline Recommendations From the International Consensus Group. *Ann Intern Med* 2019; **171**: 805-822 [PMID: 31634917 DOI: 10.7326/M19-1795]
- Chang MA, Savides TJ. Endoscopic Management of Nonvariceal, Nonulcer Upper Gastrointestinal Bleeding. *Gastrointest Endosc Clin N Am* 2018; **28**: 291-306 [PMID: 29933776 DOI: 10.1016/j.giec.2018.02.003]
- Di Serafino M, Iacobellis F, Schillirò ML, Dell'Aversano Orabona G, Martino A, Bennato R, Borzelli A, Oliva G, D'Errico C, Pezzullo F, Barbuto L, Ronza R, Ponticello G, Corvino F, Giurazza F, Lombardi G, Niola R, Romano L. The Role of CT-Angiography in the Acute Gastrointestinal Bleeding: A Pictorial Essay of Active and Obscure Findings. *Tomography* 2022; **8**: 2369-2402 [PMID: 36287797 DOI: 10.3390/tomography8050198]
- Parikh K, Ali MA, Wong RC. Unusual Causes of Upper Gastrointestinal Bleeding. *Gastrointest Endosc Clin N Am* 2015; **25**: 583-605 [PMID: 26142040 DOI: 10.1016/j.giec.2015.02.009]
- Munteanu L, Iancu I, Breazu C, Cioltean C, Brânzila S, Odainii A, Furda P, Bocșe H, Herdean A, Bartoș D, Bartoș A. Rare Causes of Gastrointestinal Bleeding: Focus on Pancreatic Pathology and Visceral Artery Aneurysms. *Chirurgia (Bucur)* 2021; **116**: S5-S15 [PMID: 35274607]
- Cooper A. Lectures on principles and practice of surgery with additional notes and cases by tyrrrell. 5th edition. Philadelphia: Haswell, 1839
- Chung J. Management of Aortoenteric Fistula. *Adv Surg* 2018; **52**: 155-177 [PMID: 30098611 DOI: 10.1016/j.yasu.2018.03.007]
- Saers SJ, Scheltinga MR. Primary aortoenteric fistula. *Br J Surg* 2005; **92**: 143-152 [PMID: 15685700 DOI: 10.1002/bjs.4928]
- Kakkos SK, Bicknell CD, Tsolakis IA, Bergqvist D; Hellenic Co-operative Group on Aortic Surgery. Editor's Choice - Management of Secondary Aorto-enteric and Other Abdominal Arterio-enteric Fistulas: A Review and Pooled Data Analysis. *Eur J Vasc Endovasc Surg* 2016; **52**: 770-786 [PMID: 27838156 DOI: 10.1016/j.ejvs.2016.09.014]

- 21 **Burks JA Jr**, Faries PL, Gravereaux EC, Hollier LH, Marin ML. Endovascular repair of bleeding aortoenteric fistulas: a 5-year experience. *J Vasc Surg* 2001; **34**: 1055-1059 [PMID: [11743560](#) DOI: [10.1067/mva.2001.119752](#)]
- 22 **Voorhoeve R**, Moll FL, de Letter JA, Bast TJ, Wester JP, Slee PH. Primary aortoenteric fistula: report of eight new cases and review of the literature. *Ann Vasc Surg* 1996; **10**: 40-48 [PMID: [8688296](#) DOI: [10.1007/BF02002340](#)]
- 23 **Chopra A**, Cieciora L, Modrall JG, Valentine RJ, Chung J. Twenty-Year Experience with Aorto-Enteric Fistula Repair: Gastrointestinal Complications Predict Mortality. *J Am Coll Surg* 2017; **225**: 9-18 [PMID: [28161484](#) DOI: [10.1016/j.jamcollsurg.2017.01.050](#)]
- 24 **Sipe A**, McWilliams SR, Saling L, Raptis C, Mellnick V, Bhalla S. The red connection: a review of aortic and arterial fistulae with an emphasis on CT findings. *Emerg Radiol* 2017; **24**: 73-80 [PMID: [27553778](#) DOI: [10.1007/s10140-016-1433-y](#)]
- 25 **Partovi S**, Trischman T, Sheth RA, Huynh TTT, Davidson JC, Prabhakar AM, Ganguli S. Imaging work-up and endovascular treatment options for aorto-enteric fistula. *Cardiovasc Diagn Ther* 2018; **8**: S200-S207 [PMID: [29850432](#) DOI: [10.21037/cdt.2017.10.05](#)]
- 26 **Vu QD**, Menias CO, Bhalla S, Peterson C, Wang LL, Balfé DM. Aortoenteric fistulas: CT features and potential mimics. *Radiographics* 2009; **29**: 197-209 [PMID: [19168845](#) DOI: [10.1148/rg.291075185](#)]
- 27 **Busuttil SJ**, Goldstone J. Diagnosis and management of aortoenteric fistulas. *Semin Vasc Surg* 2001; **14**: 302-311 [PMID: [11740838](#) DOI: [10.1053/svas.2001.27888](#)]
- 28 **Martino A**, Bennato R, Oliva G, Pontarelli A, Picascia D, Romano L, Lombardi G. Primary aortogastric fistula: an extraordinary rare endoscopic finding in the setting of upper gastrointestinal bleeding. *Endoscopy* 2021; **53**: E60-E61 [PMID: [32559781](#) DOI: [10.1055/a-1180-7701](#)]
- 29 **Yang DY**, Wiebe E, Peerani F. Aortoenteric fistula: A rare cause of upper gastrointestinal bleed captured on endoscopy with exceptional clarity. *Dig Liver Dis* 2018; **50**: 1367 [PMID: [30049639](#) DOI: [10.1016/j.dld.2018.06.023](#)]
- 30 **Chakfé N**, Diener H, Lejay A, Assadian O, Berard X, Caillon J, Fourneau I, Glaudemans AWJM, Koncar I, Lindholt J, Melissano G, Saleem BR, Senneville E, Slart RHJA, Szeberin Z, Venermo M, Vermassen F, Wyss TR; Esvs Guidelines Committee, de Borst GJ, Bastos Gonçalves F, Kakkos SK, Kolh P, Tulumano R, Vega de Ceniga M, Document Reviewers, von Allmen RS, van den Berg JC, Debus ES, Koelemay MJW, Linares-Palomino JP, Moneta GL, Ricco JB, Wanhainen A. Editor's Choice - European Society for Vascular Surgery (ESVS) 2020 Clinical Practice Guidelines on the Management of Vascular Graft and Endograft Infections. *Eur J Vasc Endovasc Surg* 2020; **59**: 339-384 [PMID: [32035742](#) DOI: [10.1016/j.ejvs.2019.10.016](#)]
- 31 **Kakkos SK**, Antoniadis PN, Klonaris CN, Papazoglou KO, Giannoukas AD, Matsagkas MI, Kotsis T, Dervisis K, Gerasimidis T, Tsolakis IA, Liapis CD. Open or endovascular repair of aortoenteric fistulas? A multicentre comparative study. *Eur J Vasc Endovasc Surg* 2011; **41**: 625-634 [PMID: [21324718](#) DOI: [10.1016/j.ejvs.2010.12.026](#)]
- 32 **Berner-Hansen V**, Olsen AA, Brandstrup B. Endoscopic treatment of primary aorto-enteric fistulas: A case report and review of literature. *World J Gastrointest Endosc* 2021; **13**: 189-197 [PMID: [34163566](#) DOI: [10.4253/wjge.v13.i6.189](#)]
- 33 **Donato F**, Boskoski I, Vincenzoni C, Montanari F, Tinelli G, Donati T, Tshomba Y. A New Mini-Invasive Approach for a Catastrophic Disease: Staged Endovascular and Endoscopic Treatment of Aorto-Esophageal Fistulas. *J Pers Med* 2022; **12** [PMID: [36294876](#) DOI: [10.3390/jpm12101735](#)]
- 34 **Tsai SM**, Chen YY, Chin-Yuan Y, Lai WL. Closure of an aorto-esophageal fistula with an esophageal stent and hemoclip. *Endoscopy* 2011; **43** Suppl 2: E302-E303 [PMID: [21915838](#) DOI: [10.1055/s-0030-1256525](#)]
- 35 **Tseng KC**, Lin CW, Tan JW. Successful management of aorto-esophageal fistula by combining endoscopic cyanoacrylate injection and endovascular stent grafting. *Endoscopy* 2011; **43** Suppl 2: E135-E136 [PMID: [21425013](#) DOI: [10.1055/s-0030-1256167](#)]
- 36 **Celada-Sendino M**, Martín-Carro C, Turienzo-Santos EO, Fernández-Cadenas F, Fraile-López M. Acute upper gastrointestinal bleeding secondary to aorto-esophageal fistula. Endoscopic treatment using the over-the-scope clip (OTSC®) system. *Rev Esp Enferm Dig* 2022; **114**: 682-683 [PMID: [35510315](#) DOI: [10.17235/reed.2022.8881/2022](#)]
- 37 **Kibbler CC**, Cohen DL, Cruickshank JK, Kushwaha SS, Morgan MY, Dick RD. Use of CAT scanning in the diagnosis and management of hepatic artery aneurysm. *Gut* 1985; **26**: 752-756 [PMID: [4018639](#) DOI: [10.1136/gut.26.7.752](#)]
- 38 **Stanley JC**, Thompson NW, Fry WJ. Splanchnic artery aneurysms. *Arch Surg* 1970; **101**: 689-697 [PMID: [5489293](#) DOI: [10.1001/archsurg.1970.01340300045009](#)]
- 39 **Sousa J**, Costa D, Mansilha A. Visceral artery aneurysms: review on indications and current treatment strategies. *Int Angiol* 2019; **38**: 381-394 [PMID: [31284707](#) DOI: [10.23736/S0392-9590.19.04194-4](#)]
- 40 **Pulli R**, Dorigo W, Troisi N, Pratesi G, Innocenti AA, Pratesi C. Surgical treatment of visceral artery aneurysms: A 25-year experience. *J Vasc Surg* 2008; **48**: 334-342 [PMID: [18644480](#) DOI: [10.1016/j.jvs.2008.03.043](#)]
- 41 **Chaer RA**, Abularrage CJ, Coleman DM, Eslami MH, Kashyap VS, Rockman C, Murad MH. The Society for Vascular Surgery clinical practice guidelines on the management of visceral aneurysms. *J Vasc Surg* 2020; **72**: 3S-39S [PMID: [32201007](#) DOI: [10.1016/j.jvs.2020.01.039](#)]
- 42 **Cordova AC**, Sumpio BE. Visceral Artery Aneurysms and Pseudoaneurysms—Should They All be Managed by Endovascular Techniques? *Ann Vasc Dis* 2013; **6**: 687-693 [PMID: [24386016](#) DOI: [10.3400/avd.ra.13-00045](#)]
- 43 **Shanley CJ**, Shah NL, Messina LM. Common splanchnic artery aneurysms: splenic, hepatic, and celiac. *Ann Vasc Surg* 1996; **10**: 315-322 [PMID: [8793003](#) DOI: [10.1007/BF02001900](#)]
- 44 **Björck M**, Koelemay M, Acosta S, Bastos Goncalves F, Kölbel T, Kolkman JJ, Lees T, Lefevre JH, Menyhei G, Oderich G; Esvs Guidelines Committee, Kolh P, de Borst GJ, Chakfé N, Debus S, Hinchliffe R, Kakkos S, Koncar I, Sanddal Lindholt J, Vega de Ceniga M, Vermassen F, Verzini F, Document Reviewers, Geelkerken B, Gloviczki P, Huber T, Naylor R. Editor's Choice - Management of the Diseases of Mesenteric Arteries and Veins: Clinical Practice Guidelines of the European Society of Vascular Surgery (ESVS). *Eur J Vasc Endovasc Surg* 2017; **53**: 460-510 [PMID: [28359440](#) DOI: [10.1016/j.ejvs.2017.01.010](#)]
- 45 **Panzer F**, Inchingolo R, Rizzi M, Biscaglia A, Schievenin MG, Tallarico E, Pacifico G, Di Venere B. Giant splenic artery aneurysm presenting with massive upper gastrointestinal bleeding: A case report and review of literature. *World J Gastroenterol* 2020; **26**: 3110-3117 [PMID: [32587452](#) DOI: [10.3748/wjg.v26.i22.3110](#)]
- 46 **Binetti M**, Lauro A, Golfieri R, Vaccari S, D'Andrea V, Marino IR, Cervellera M, Renzulli M, Tonini V. False in Name Only-Gastroduodenal Artery Pseudoaneurysm in a Recurrently Bleeding Patient: Case Report and Literature Review. *Dig Dis Sci* 2019; **64**: 3086-3091 [PMID: [31559552](#) DOI: [10.1007/s10620-019-05853-7](#)]
- 47 **Roberts KJ**, Jones RG, Forde C, Marudanayagam R. Endoscopic ultrasound-guided treatment of visceral artery pseudoaneurysm. *HPB (Oxford)* 2012; **14**: 489-490 [PMID: [22672553](#) DOI: [10.1111/j.1477-2574.2012.00470.x](#)]
- 48 **Gamanagatti S**, Thingujam U, Garg P, Nongthombam S, Dash NR. Endoscopic ultrasound guided thrombin injection of angiographically

- occult pancreatitis associated visceral artery pseudoaneurysms: Case series. *World J Gastrointest Endosc* 2015; **7**: 1107-1113 [PMID: 26421108 DOI: 10.4253/wjge.v7.i13.1107]
- 49 **Maharshi S**, Sharma SS, Sapra B, Nijhawan S. Endoscopic ultrasound-guided thrombin injection, a management approach for visceral artery pseudoaneurysms. *Endosc Int Open* 2020; **8**: E407-E412 [PMID: 32118114 DOI: 10.1055/a-1070-9168]
  - 50 **Anderloni A**, Auriemma F, Samarasena J. Visceral artery pseudoaneurysm: Is EUS-guided treatment ready for prime time? *Endosc Int Open* 2020; **8**: E413-E414 [PMID: 32140558 DOI: 10.1055/a-1096-0617]
  - 51 **Spriggs DW**. Congenital absence of the splenic artery. *Cardiovasc Intervent Radiol* 1984; **7**: 303-305 [PMID: 6335674 DOI: 10.1007/BF02625116]
  - 52 **Martino A**, Di Serafino M, Zito FP, Maglione F, Bennato R, Orsini L, Iacobelli A, Niola R, Romano L, Lombardi G. Massive bleeding from gastric submucosal arterial collaterals secondary to splenic artery thrombosis: A case report. *World J Gastroenterol* 2022; **28**: 5506-5514 [PMID: 36312836 DOI: 10.3748/wjg.v28.i37.5506]
  - 53 **Stolze T**, Wienbeck M. [The collateral circulation in the chronic occlusion of the splenic artery]. *Rofo* 1976; **124**: 386-387 [PMID: 131773 DOI: 10.1055/s-0029-1230356]
  - 54 **Sarin SK**, Lahoti D, Saxena SP, Murthy NS, Makwana UK. Prevalence, classification and natural history of gastric varices: a long-term follow-up study in 568 portal hypertension patients. *Hepatology* 1992; **16**: 1343-1349 [PMID: 1446890 DOI: 10.1002/hep.1840160607]
  - 55 **Gralnek IM**, Camus Duboc M, Garcia-Pagan JC, Fuccio L, Karstensen JG, Hucl T, Jovanovic I, Awadie H, Hernandez-Gea V, Tantau M, Ebigo A, Ibrahim M, Vlachogiannakos J, Burgmans MC, Rosasco R, Triantafyllou K. Endoscopic diagnosis and management of esophagogastric variceal hemorrhage: European Society of Gastrointestinal Endoscopy (ESGE) Guideline. *Endoscopy* 2022; **54**: 1094-1120 [PMID: 36174643 DOI: 10.1055/a-1939-4887]
  - 56 **Lee GH**, Kim JH, Lee KJ, Yoo BM, Hahm KB, Cho SW, Park YS, Moon YS. Life-threatening intraabdominal arterial embolization after histoacryl injection for bleeding gastric ulcer. *Endoscopy* 2000; **32**: 422-424 [PMID: 10817185 DOI: 10.1055/s-2000-9002]
  - 57 **Lee KJ**, Kim JH, Hahm KB, Cho SW, Park YS. Randomized trial of N-butyl-2-cyanoacrylate compared with injection of hypertonic saline-epinephrine in the endoscopic treatment of bleeding peptic ulcers. *Endoscopy* 2000; **32**: 505-511 [PMID: 10917181 DOI: 10.1055/s-2000-3816]
  - 58 **Lee YT**, Walmsley RS, Leong RW, Sung JJ. Dieulafoy's lesion. *Gastrointest Endosc* 2003; **58**: 236-243 [PMID: 12872092 DOI: 10.1067/mge.2003.328]
  - 59 **Nojkov B**, Cappell MS. Gastrointestinal bleeding from Dieulafoy's lesion: Clinical presentation, endoscopic findings, and endoscopic therapy. *World J Gastrointest Endosc* 2015; **7**: 295-307 [PMID: 25901208 DOI: 10.4253/wjge.v7.i4.295]
  - 60 **Gallard MT**. Aneurysme miliaires de l'estomac, donnant lieu a des hematemeses mortelles. *Bull Soc Med Hop Paris* 1884; **1**: 84-91
  - 61 **Dieulafoy G**. Exulceratio simplex: Leçons 1-3. In: Dieulafoy G. Clinique medicale de l'Hotel Dieu de Paris. Paris: Masson et Cie, 1898: 1-38
  - 62 **Barlow TE**, Bentley FH, Walder DN. Arteries, veins, and arteriovenous anastomoses in the human stomach. *Surg Gynecol Obstet* 1951; **93**: 657-671 [PMID: 14893072]
  - 63 **Chaer RA**, Helton WS. Dieulafoy's disease. *J Am Coll Surg* 2003; **196**: 290-296 [PMID: 12595057 DOI: 10.1016/S1072-7515(02)01801-X]
  - 64 **Dy NM**, Gostout CJ, Balm RK. Bleeding from the endoscopically-identified Dieulafoy lesion of the proximal small intestine and colon. *Am J Gastroenterol* 1995; **90**: 108-111 [PMID: 7801908]
  - 65 **Chung YF**, Wong WK, Soo KC. Diagnostic failures in endoscopy for acute upper gastrointestinal haemorrhage. *Br J Surg* 2000; **87**: 614-617 [PMID: 10792319 DOI: 10.1046/j.1365-2168.2000.01386.x]
  - 66 **Fockens P**, Meenan J, van Dullemen HM, Bolwerk CJ, Tytgat GN. Dieulafoy's disease: endosonographic detection and endosonography-guided treatment. *Gastrointest Endosc* 1996; **44**: 437-442 [PMID: 8905365 DOI: 10.1016/S0016-5107(96)70096-2]
  - 67 **Durham JD**, Kumpe DA, Rothbarth LJ, Van Stiegmann G. Dieulafoy disease: arteriographic findings and treatment. *Radiology* 1990; **174**: 937-941 [PMID: 2305095 DOI: 10.1148/radiology.174.3.174-3-937]
  - 68 **Chen YY**, Su WW, Soon MS, Yen HH. Delayed fatal hemorrhage after endoscopic band ligation for gastric Dieulafoy's lesion. *Gastrointest Endosc* 2005; **62**: 630-632 [PMID: 16185987 DOI: 10.1016/S0016-5107(05)01583-x]
  - 69 **Skinner M**, Gutierrez JP, Neumann H, Wilcox CM, Burski C, Mönkemüller K. Over-the-scope clip placement is effective rescue therapy for severe acute upper gastrointestinal bleeding. *Endosc Int Open* 2014; **2**: E37-E40 [PMID: 26134611 DOI: 10.1055/s-0034-1365282]
  - 70 **Manno M**, Mangiafico S, Caruso A, Barbera C, Bertani H, Mirante VG, Pigò F, Amardeep K, Conigliaro R. First-line endoscopic treatment with OTSC in patients with high-risk non-variceal upper gastrointestinal bleeding: preliminary experience in 40 cases. *Surg Endosc* 2016; **30**: 2026-2029 [PMID: 26201415 DOI: 10.1007/s00464-015-4436-y]
  - 71 **Wong RC**. New diagnostic imaging technologies in nonvariceal upper gastrointestinal bleeding. *Gastrointest Endosc Clin N Am* 2011; **21**: 707-720 [PMID: 21944420 DOI: 10.1016/j.giec.2011.07.013]
  - 72 **Han C**, Ling X, Liu J, Lin R, Ding Z. Management of non-variceal upper gastrointestinal bleeding: role of endoscopic ultrasound-guided treatments. *Therap Adv Gastroenterol* 2022; **15**: 17562848211056148 [PMID: 35126666 DOI: 10.1177/17562848211056148]
  - 73 **Truesdale PE**. RECURRING HERNIA OF THE DIAPHRAGM. *Ann Surg* 1924; **79**: 751-757 [PMID: 17865033 DOI: 10.1097/00000658-192405000-00010]
  - 74 **Cameron AJ**. Incidence of iron deficiency anemia in patients with large diaphragmatic hernia. A controlled study. *Mayo Clin Proc* 1976; **51**: 767-769 [PMID: 1086935]
  - 75 **Kapadia S**, Jagroop S, Kumar A. Cameron ulcers: an atypical source for a massive upper gastrointestinal bleed. *World J Gastroenterol* 2012; **18**: 4959-4961 [PMID: 23002369 DOI: 10.3748/wjg.v18.i35.4959]
  - 76 **Gray DM**, Kushnir V, Kalra G, Rosenstock A, Alsakka MA, Patel A, Sayuk G, Gyawali CP. Cameron lesions in patients with hiatal hernias: prevalence, presentation, and treatment outcome. *Dis Esophagus* 2015; **28**: 448-452 [PMID: 24758713 DOI: 10.1111/dote.12223]
  - 77 **Weston AP**. Hiatal hernia with cameron ulcers and erosions. *Gastrointest Endosc Clin N Am* 1996; **6**: 671-679 [PMID: 8899401]
  - 78 **Nguyen N**, Tam W, Kimber R, Roberts-Thomson IC. Gastrointestinal: Cameron's erosions. *J Gastroenterol Hepatol* 2002; **17**: 343 [PMID: 11982707 DOI: 10.1046/j.1440-1746.2002.02760.x]
  - 79 **Camus M**, Jensen DM, Ohning GV, Kovacs TO, Ghassemi KA, Jutabha R, Machicado GA, Dulai GS, Hines OJ. Severe upper gastrointestinal hemorrhage from linear gastric ulcers in large hiatal hernias: a large prospective case series of Cameron ulcers. *Endoscopy* 2013; **45**: 397-400 [PMID: 23616128 DOI: 10.1055/s-0032-1326294]
  - 80 **Maganty K**, Smith RL. Cameron lesions: unusual cause of gastrointestinal bleeding and anemia. *Digestion* 2008; **77**: 214-217 [PMID: 18622137 DOI: 10.1159/000144281]



- 81 **Zaman A**, Katon RM. Push enteroscopy for obscure gastrointestinal bleeding yields a high incidence of proximal lesions within reach of a standard endoscope. *Gastrointest Endosc* 1998; **47**: 372-376 [PMID: 9609429 DOI: 10.1016/s0016-5107(98)70221-4]
- 82 **Appleyard MN**, Swain CP. Endoscopic difficulties in the diagnosis of upper gastrointestinal bleeding. *World J Gastroenterol* 2001; **7**: 308-312 [PMID: 11819781 DOI: 10.3748/wjg.v7.i3.308]
- 83 **Lin CC**, Chen TH, Ho WC, Chen TY. Endoscopic treatment of a Cameron lesion presenting as life-threatening gastrointestinal hemorrhage. *J Clin Gastroenterol* 2001; **33**: 423-424 [PMID: 11606864 DOI: 10.1097/00004836-200111000-00018]
- 84 **Lower WE**, Farrell JI. Aneurysm of the splenic artery: report of a case and review of the literature. *Arch Surg* 1931; **23**: 182-190 [DOI: 10.1001/archsurg.1931.01160080010002]
- 85 **Rammohan A**, Palaniappan R, Ramaswami S, Perumal SK, Lakshmanan A, Srinivasan UP, Ramasamy R, Sathyanesan J. Hemosuccus Pancreaticus: 15-Year Experience from a Tertiary Care GI Bleed Centre. *ISRN Radiol* 2013; **2013**: 191794 [PMID: 24959558 DOI: 10.5402/2013/191794]
- 86 **Sandblom P**. Gastrointestinal hemorrhage through the pancreatic duct. *Ann Surg* 1970; **171**: 61-66 [PMID: 5308032 DOI: 10.1097/0000658-197001000-00009]
- 87 **Ru N**, Zou WB, Qian YY, Tang XY, Zhu JH, Hu LH, Li ZS, Liao Z. A Systematic Review of the Etiology, Diagnosis, and Treatment of Hemosuccus Pancreaticus. *Pancreas* 2019; **48**: e47-e49 [PMID: 31090670 DOI: 10.1097/MPA.0000000000001278]
- 88 **Abdelgabar A**, d'Archambeau O, Maes J, Van den Brande F, Cools P, Rutsaert RR. Visceral artery pseudoaneurysms: two case reports and a review of the literature. *J Med Case Rep* 2017; **11**: 126 [PMID: 28472975 DOI: 10.1186/s13256-017-1291-6]
- 89 **Kitano M**, Gress TM, Garg PK, Itoi T, Irisawa A, Isayama H, Kanno A, Takase K, Levy M, Yasuda I, Lévy P, Isaji S, Fernandez-Del Castillo C, Drewes AM, Sheel ARG, Neoptolemos JP, Shimosegawa T, Boermeester M, Wilcox CM, Whitcomb DC. International consensus guidelines on interventional endoscopy in chronic pancreatitis. Recommendations from the working group for the international consensus guidelines for chronic pancreatitis in collaboration with the International Association of Pancreatology, the American Pancreatic Association, the Japan Pancreas Society, and European Pancreatic Club. *Pancreatology* 2020; **20**: 1045-1055 [PMID: 32792253 DOI: 10.1016/j.pan.2020.05.022]
- 90 **Pham KD**, Pedersen G, Halvorsen H, Jøssang D, Flesland RH, Gjorgji GD. Usefulness of endoscopic ultrasound for the diagnosis of hemosuccus pancreaticus. *Endoscopy* 2014; **46** Suppl 1: E528 [PMID: 25409053 DOI: 10.1055/s-0034-1377641]
- 91 **Tarantino I**, Rizzo GEM, Ligresti D, Jukna A, Maruzzelli L, Gruttadauria S, Traina M. Hemosuccus pancreaticus: an in-motion endoscopic ultrasound view. *Endoscopy* 2022; **54**: E1038-E1040 [PMID: 36007913 DOI: 10.1055/a-1904-7312]
- 92 **Gutkin E**, Kim SH. A novel endoscopic treatment of hemosuccus pancreaticus: a stent tree tamponade. *JOP* 2012; **13**: 312-313 [PMID: 22572140]
- 93 **Glisson F**. Anatomia Hepatis. London: O. Pullein, 1654
- 94 **Zhornitskiy A**, Berry R, Han JY, Tabibian JH. Hemobilia: Historical overview, clinical update, and current practices. *Liver Int* 2019; **39**: 1378-1388 [PMID: 30932305 DOI: 10.1111/liv.14111]
- 95 **Quincke H**. Ein fall von aneurysma der leberarterie [A Case of Hepatic Artery Aneurysm]. *Berl Klin Wochenschr* 1871; **30**: 349-352
- 96 **Berry R**, Han J, Girotra M, Tabibian JH. Hemobilia: Perspective and Role of the Advanced Endoscopist. *Gastroenterol Res Pract* 2018; **2018**: 3670739 [PMID: 30116262 DOI: 10.1155/2018/3670739]
- 97 **Murugesan SD**, Sathyanesan J, Lakshmanan A, Ramaswami S, Perumal S, Perumal SU, Ramasamy R, Palaniappan R. Massive hemobilia: a diagnostic and therapeutic challenge. *World J Surg* 2014; **38**: 1755-1762 [PMID: 24381048 DOI: 10.1007/s00268-013-2435-5]
- 98 **Ramchandani M**, Reddy DN, Lakhtakia S, Tandan M, Maydeo A, Chandrashekar TS, Kumar A, Sud R, Rerknimitr R, Makmun D, Khor C. Per oral cholangiopancreatography in pancreatic biliary diseases--expert consensus statements. *World J Gastroenterol* 2015; **21**: 4722-4734 [PMID: 25914484 DOI: 10.3748/wjg.v21.i15.4722]
- 99 **Konerman MA**, Zhang Z, Piraka C. Endoscopic Ultrasound as a Diagnostic Tool in a Case of Obscure Hemobilia. *ACG Case Rep J* 2016; **3**: e170 [PMID: 28008403 DOI: 10.14309/crj.2016.143]
- 100 **Trakarnsanga A**, Sriprayoon T, Akaraviputh T, Tongdee T. Massive hemobilia from a ruptured hepatic artery aneurysm detected by endoscopic ultrasound (EUS) and successfully treated. *Endoscopy* 2010; **42** Suppl 2: E340-E341 [PMID: 21170839 DOI: 10.1055/s-0030-1255940]
- 101 **Sharma M**, Rameshbabu CS. Portal cavernoma cholangiopathy: an endoscopic ultrasound based imaging approach. *J Clin Exp Hepatol* 2014; **4**: S53-S61 [PMID: 25755596 DOI: 10.1016/j.jceh.2013.08.015]
- 102 **Seicean A**. Endoscopic ultrasound in the diagnosis and treatment of upper digestive bleeding: a useful tool. *J Gastrointest Liver Dis* 2013; **22**: 465-469 [PMID: 24369332]
- 103 **Barresi L**, Tarantino I, Ligresti D, Curcio G, Granata A, Traina M. Fully covered self-expandable metal stent treatment of spurting bleeding into the biliary tract after endoscopic ultrasound-guided fine-needle aspiration of a solid lesion of the pancreatic head. *Endoscopy* 2015; **47** Suppl 1: E87-E88 [PMID: 25926229 DOI: 10.1055/s-0034-1391239]
- 104 **Song JY**, Moon JH, Choi HJ, Kim DC, Choi MH, Lee TH, Cha SW, Cho YD, Park SH. Massive hemobilia following transpapillary bile duct biopsy treated by using a covered self-expandable metal stent. *Endoscopy* 2014; **46** Suppl 1: E161-E162 [PMID: 24756274 DOI: 10.1055/s-0034-1365115]
- 105 **Goenka MK**, Harwani Y, Rai V, Goenka U. Fully covered self-expandable metal biliary stent for hemobilia caused by portal biliopathy. *Gastrointest Endosc* 2014; **80**: 1175 [PMID: 24818548 DOI: 10.1016/j.gie.2014.03.029]
- 106 **Cathcart S**, Birk JW, Tadros M, Schuster M. Hemobilia: An Uncommon But Notable Cause of Upper Gastrointestinal Bleeding. *J Clin Gastroenterol* 2017; **51**: 796-804 [PMID: 28644311 DOI: 10.1097/MCG.0000000000000876]
- 107 **Sharma M**, Somani P, Talele R, Kohli V, Sunkara T. EUS-guided thrombin injection of cystic artery pseudoaneurysm leading to Mirizzi's syndrome and hemobilia. *VideoGIE* 2019; **4**: 163-165 [PMID: 31032465 DOI: 10.1016/j.vgie.2018.12.004]



Published by **Baishideng Publishing Group Inc**  
7041 Koll Center Parkway, Suite 160, Pleasanton, CA 94566, USA

**Telephone:** +1-925-3991568

**E-mail:** [bpgoffice@wjgnet.com](mailto:bpgoffice@wjgnet.com)

**Help Desk:** <https://www.f6publishing.com/helpdesk>

<https://www.wjgnet.com>

