



## Retrospective Study

# Risk factors and a predictive nomogram for lymph node metastasis in superficial esophageal squamous cell carcinoma

Jin Wang, Xian Zhang, Tao Gan, Ni-Ni Rao, Kai Deng, Jin-Lin Yang

**Specialty type:** Gastroenterology and hepatology

**Provenance and peer review:**

Unsolicited article; Externally peer reviewed.

**Peer-review model:** Single blind

**Peer-review report's scientific quality classification**

Grade A (Excellent): 0  
Grade B (Very good): B, B  
Grade C (Good): 0  
Grade D (Fair): 0  
Grade E (Poor): 0

**P-Reviewer:** Bredt LC, Brazil; Guo D, China

**Received:** August 4, 2023

**Peer-review started:** August 4, 2023

**First decision:** October 25, 2023

**Revised:** November 7, 2023

**Accepted:** December 8, 2023

**Article in press:** December 8, 2023

**Published online:** December 21, 2023



**Jin Wang, Tao Gan, Kai Deng, Jin-Lin Yang,** Department of Gastroenterology and Hepatology, Sichuan University-University of Oxford Huaxi Joint Centre for Gastrointestinal Cancer, Frontiers Science Center for Disease-Related Molecular Network, West China Hospital, Sichuan University, Chengdu 610041, Sichuan Province, China

**Xian Zhang,** Department of Pathology, West China Hospital, Sichuan University, Chengdu 610041, Sichuan Province, China

**Ni-Ni Rao,** School of Life Science and Technology, University of Electronic Science and Technology of China, Chengdu 610064, Sichuan Province, China

**Corresponding author:** Jin-Lin Yang, MD, PhD, Chief Physician, Professor, Department of Gastroenterology and Hepatology, Sichuan University-University of Oxford Huaxi Joint Centre for Gastrointestinal Cancer, Frontiers Science Center for Disease-Related Molecular Network, West China Hospital, Sichuan University, No. 37 Guoxue Road, Wuhou District, Chengdu 610041, Sichuan Province, China. [yangjinlin@wchscu.cn](mailto:yangjinlin@wchscu.cn)

## Abstract

### BACKGROUND

Superficial esophageal squamous cell carcinoma (ESCC) is defined as cancer infiltrating the mucosa and submucosa, regardless of regional lymph node metastasis (LNM). Endoscopic resection of superficial ESCC is suitable for lesions that have no or low risk of LNM. Patients with a high risk of LNM always need further treatment after endoscopic resection. Therefore, accurately assessing the risk of LNM is critical for additional treatment options.

### AIM

To analyze risk factors for LNM and develop a nomogram to predict LNM risk in superficial ESCC patients.

### METHODS

Clinical and pathological data of superficial ESCC patients undergoing esophagectomy from January 1, 2009 to January 31, 2016 were collected. Logistic regression analysis was used to predict LNM risk factors, and a nomogram was developed based on risk factors derived from multivariate logistic regression analysis. The receiver operating characteristic (ROC) curve was used to obtain the accuracy of the nomogram model.

## RESULTS

A total of 4660 patients with esophageal cancer underwent esophagectomy. Of these, 474 superficial ESCC patients were enrolled in the final analysis, with 322 patients in the training set and 142 patients in the validation set. The prevalence of LNM was 3.29% (5/152) for intramucosal cancer and increased to 26.40% (85/322) for submucosal cancer. Multivariate logistic analysis showed that tumor size, invasive depth, tumor differentiation, infiltrative growth pattern, tumor budding, and lymphovascular invasion were significantly correlated with LNM. A nomogram using these six variables showed good discrimination with an area under the ROC curve of 0.789 (95%CI: 0.737-0.841) in the training set and 0.827 (95%CI: 0.755-0.899) in the validation set.

## CONCLUSION

We developed a useful nomogram model to predict LNM risk for superficial ESCC patients which will facilitate additional decision-making in treating patients who undergo endoscopic resection.

**Key Words:** Superficial esophageal squamous cell carcinoma; Lymph node metastasis; Risk factors; Nomogram; Predictive model

©The Author(s) 2023. Published by Baishideng Publishing Group Inc. All rights reserved.

**Core Tip:** This is a retrospective study to identify risk factors for lymph node metastasis (LNM) in superficial esophageal squamous cell carcinoma (ESCC) and to develop a nomogram model for predicting LNM. A total of 474 superficial ESCC patients who underwent esophagectomy were enrolled. Multivariate logistic analysis showed that tumor size, invasive depth, tumor differentiation, infiltrative growth pattern, tumor budding, and lymphovascular invasion were significantly correlated with LNM. A predictive nomogram using these six variables showed good performance and will facilitate the treatment choice for superficial ESCC patients.

**Citation:** Wang J, Zhang X, Gan T, Rao NN, Deng K, Yang JL. Risk factors and a predictive nomogram for lymph node metastasis in superficial esophageal squamous cell carcinoma. *World J Gastroenterol* 2023; 29(47): 6138-6147

**URL:** <https://www.wjgnet.com/1007-9327/full/v29/i47/6138.htm>

**DOI:** <https://dx.doi.org/10.3748/wjg.v29.i47.6138>

## INTRODUCTION

Superficial esophageal squamous cell carcinoma (ESCC) is defined as esophageal cancerous lesions infiltrating the mucosa and submucosa, regardless of lymph node metastasis (LNM)[1]. Endoscopic resection has been the first treatment choice for superficial ESCC patients with no or low risk of LNM and has an *en bloc* rate of more than 90%[2,3]. However, additional treatment is recommended for patients with high risk of LNM, especially for patients with positive lymphovascular invasion (LVI) and positive vertical margins[4]. Assessing pathological characteristics after endoscopic resection and predicting the risk of LNM is critical for additional treatment strategies.

Recent studies have established several predictive models to identify LNM risk for superficial ESCC patients[5-8]. However, some limitations existed in these models. For example, some studies did not incorporate critical factors, such as tumor budding and tumor infiltrative growth (INF) pattern, into LNM risk prediction. In some studies, the submucosa was considered as an entire layer[5,6] and the depth was not classified as submucosa 1 (SM1), SM2 or more[7,8]. Therefore, we aimed to establish a nomogram predictive model based on comprehensive pathological features obtained from esophagectomy to improve the predictive performance of such models.

## MATERIALS AND METHODS

### Patients

Patients who underwent esophagectomy at West China Hospital of Sichuan University from January 1, 2009, to January 31, 2016, were enrolled. The inclusion criteria were as follows: (1) Histopathological diagnosis of esophageal cancer; and (2) patients who received esophagectomy. The exclusion criteria were as follows: (1) Not pT1 stage tumor; (2) the histologic type was not squamous cell carcinoma; (3) number of dissected lymph nodes < 12; (4) history of previous malignancies; (5) incomplete clinical data; and (6) lesions with low-grade intraepithelial neoplasia or high-grade intraepithelial neoplasia. This retrospective study was approved by the Institutional Review Board of West China Hospital of Sichuan University (No. 2015-159). Informed consent was signed before the surgery.

## Data collection

General clinical and endoscopic features, such as age, sex, tumor location, and endoscopic type, were retrospectively collected. Tumor location was defined as: (1) Upper: 15 to 24 cm from the incisors; (2) middle: 24 to 32 cm from the incisors; and (3) lower: 32 cm from the incisors to the cardia. Endoscopic types were identified according to the Paris classification criteria for superficial tumors[9]. The pathologic diagnosis was independently confirmed by two experienced pathologists. If the diagnosis is inconsistent, a third expert pathologist will re-examine the specimen, and the final diagnosis will be made when two or more pathologists agree on the diagnosis.

Data regarding pathological characteristics of specimens, such as tumor size, invasion depth, differentiation grade, INF pattern, tumor budding, LVI, and number of dissected lymph nodes, were collected. The vertical invasion depth of submucosal invasion was measured from the muscularis mucosae according to the Japanese guidelines[10]. The invasion depth was classified into four layers: Muscularis mucosae (MM), upper third of submucosa (SM1), middle third of submucosa (SM2) and lower third of submucosa (SM3) according to the Japanese Classification of Esophageal Cancer [10]. The differentiation grade was grouped as well differentiated (G1), moderately differentiated (G2), and poorly differentiated (G3)[11]. The tumor INF pattern was carefully observed and classified into three groups according to previous reports[10,12]: INF-a (expansive type, expansive growth of tumor nests downward continuously from the epithelium as a whole), INF-b (intermediate type between INF-a and INF-c), and INF-c (infiltrative type, tumor infiltrates with a way of single cell or small tumor nests, or trabecular arrangement of tumor cells on the leading edge of the tumor). Tumor budding is defined as a single tumor cell or a small tumor nest consisting of up to 4 cells at the front of the tumor invasion [13]. In this study, tumor budding was assessed on hematoxylin and eosin-stained slides at the front of tumor invasion. Tumor budding was categorized into three types: No budding, low-grade tumor budding (1 to 4 budding foci at a 20 × objective lens) and high-grade tumor budding (≥ 5 budding foci at a 20 × objective lens) according to a previous study [14]. For LVI, two experienced pathologists observed the same specimen to improve diagnostic accuracy.

## Statistical analysis

Continuous variables are presented as mean ± SD and are compared with a *t* test in the case of a normal distribution. Categorical data are presented as percentages and are compared with the chi-square test or Fisher's exact test. All variables associated with LNM at a significant level were enrolled in the stepwise multivariate logistic analysis. All data were statistically analyzed by SPSS 22.0 software (IBM SPSS, Chicago, IL, United States). *P* values < 0.05 were considered statistically significant.

R software (version 4.1.3) with the rms package was used to formulate a predictive nomogram using variables derived from multivariate logistic analysis. The pROC package was used to formulate the receiver operating characteristic (ROC) curve, and the area under the curve (AUC) was used to evaluate the predictive performance of this nomogram as previously reported[15]. The nomogram can convert each regression variable to a scale of 0-100 points based on the regression coefficient. Finally, the predicted probabilities were derived from the total points obtained from each independent variable.

# RESULTS

## Clinicopathologic characteristics

In total, 4660 esophageal cancer patients underwent esophagectomy from January 1, 2009 to January 31, 2016 of which, 474 superficial ESCC patients were enrolled in the final analysis (Figure 1). The clinicopathologic characteristics of enrolled patients are presented in Table 1. Most of the superficial ESCC patients were male (77.4%), the average age was 60 (range, 38-84) years, and the average tumor size was 23 (range, 3-73) mm. Most tumors (63.9%) were located in the middle third of the esophagus. According to the endoscopic appearance, 309 (65.2%) tumors presented as flat lesions. Regarding invasion depth, 152 (32.1%) patients had intramucosal cancer, 80 (16.9%) patients had SM1 cancer, and 242 (51.0%) patients had tumors deeper than SM1. Regarding tumor differentiation, 103 (21.7%) patients, 279 (58.9%) patients, and 92 (19.4%) patients had well differentiated, moderately differentiated, and poorly differentiated tumors, respectively. INF-b was the most common INF pattern, with 232 (48.9%) cases reported as such. The total tumor budding rate was 13.5% (64/474), and the LVI rate was 5.7% (27/474). Overall, 90 of the 474 (16.48%) patients had lymph node metastasis (LNM), and the LNM rate was 3.29% (5/152) in T1a tumors and 26.40% (85/322) in T1b tumors. The average number of dissected lymph nodes was 18.0 (range, 12-53) (Table 1).

## Risk factors for LNM

The 474 enrolled patients were randomly grouped into a training set and a validation set at a ratio of 7:3. Comparisons of clinicopathological characteristics between the LNM+ and LNM- groups are presented in Table 2. Variables such as tumor size, invasion depth, tumor differentiation, INF pattern, tumor budding and LVI were significantly associated with LNM in both the training set and validation set according to the univariate analysis (Table 2). Furthermore, multivariate logistic regression analysis also showed that tumor size, invasion depth, tumor differentiation, INF pattern, tumor budding, and LVI were independent risk factors for LNM (Table 3).

## Development and validation of the nomogram

Subsequently, a nomogram was developed based on six independent risk factors derived from the multivariate analysis (Figure 2). The point of each factor was proportional to its own  $\beta$ -coefficient resulted from logistic regression. Finally, the

**Table 1 Patient clinicopathologic characteristics**

Characteristics	No. of patients, <i>n</i> (%)
Gender	
Male	367 (77.4)
Female	107 (22.6)
Age (yr), median (range)	60 (38-84)
Tumor size (mm), median (range)	23 (3-73)
Tumor location	
Upper third	28 (5.9)
Middle third	303 (63.9)
Lower third	143 (30.2)
Paris classification	
0-I	95 (20.0)
0-II	309 (65.2)
0-III	70 (14.8)
Depth of invasion	
MM	152 (32.1)
SM1	80 (16.9)
SM2	106 (22.3)
SM3	136 (28.7)
Differentiation	
Well	103 (21.7)
Moderate	279 (58.9)
Poor	92 (19.4)
INF pattern	
INF-a	196 (41.4)
INF-b	232 (48.9)
INF-c	46 (9.7)
Tumor budding	64 (13.5)
LVI	27 (5.7)
LNM	
Yes	90 (19.0)
No	384 (81.0)
Dissected LN, median (range)	18.0 (12-53)

MM: Muscularis mucosae; SM1: Upper third of submucosa; SM2: Middle third of submucosa; SM3: Lower third of submucosa; INF pattern: Infiltrative growth pattern; LVI: Lymphovascular invasion; LNM: Lymph node metastasis; LN: Lymph node.

total points of each factor were added and visually corresponded to a predictive value for LNM. The ROC curve showed that this nomogram had good predictive performance both in the training set and in the validation set, with AUCs of 0.789 (95%CI: 0.737-0.841) and 0.827 (95%CI: 0.755-0.899), respectively (Figure 3).

## DISCUSSION

Endoscopic resection has become one of the preferred treatment methods for superficial ESCC. Compared to surgery, it has fewer complications and a shorter recovery time[16]. Guidelines and studies have indicated that endoscopic

**Table 2 Comparisons of clinicopathological characteristics between lymph node metastasis positive and lymph node metastasis negative group**

Variable	Training set (n = 332)		P value	Validation set (n = 142)		P value
	LNM(-)	LNM(+)		LNM(-)	LNM(+)	
Gender			0.298			0.913
Male	201	51		84	20	
Female	68	12		31	7	
Age (yr), median (range)	60 (42-80)	60 (45-84)	0.204	60 (38-78)	58 (47-76)	0.522
Tumor size, (cm), mean $\pm$ SD	2.23 $\pm$ 1.21	2.65 $\pm$ 0.99	0.008	2.07 $\pm$ 0.97	2.61 $\pm$ 0.86	0.008
Tumor location, n (%)			0.095			0.702
Upper third	14	6		7	1	
Middle third	181	47		62	13	
Lower third	74	10		46	13	
Paris classification, n (%)			0.282			0.158
0-I	46	14		26	9	
0-II	186	37		74	12	
0-III	37	12		15	6	
Depth of invasion, n (%)			< 0.001			< 0.001
MM	100	3		47	2	
SM1	53	6		19	2	
> SM1	116	54		49	23	
Differentiation, n (%)			0.015			0.029
Well	77	8		15	3	
Moderate	148	38		80	13	
Poor	44	17		20	11	
INF pattern, n (%)			0.001			0.014
INF-a	125	13		53	5	
INF-b	123	41		52	16	
INF-c	21	9		10	6	
Tumor budding, n (%)			0.009			0.009
No	241	48		103	18	
Low	19	8		8	5	
High	9	7		4	4	
LVI, n (%)			0.005			0.004
Yes	10	8		4	5	
No	259	55		111	22	

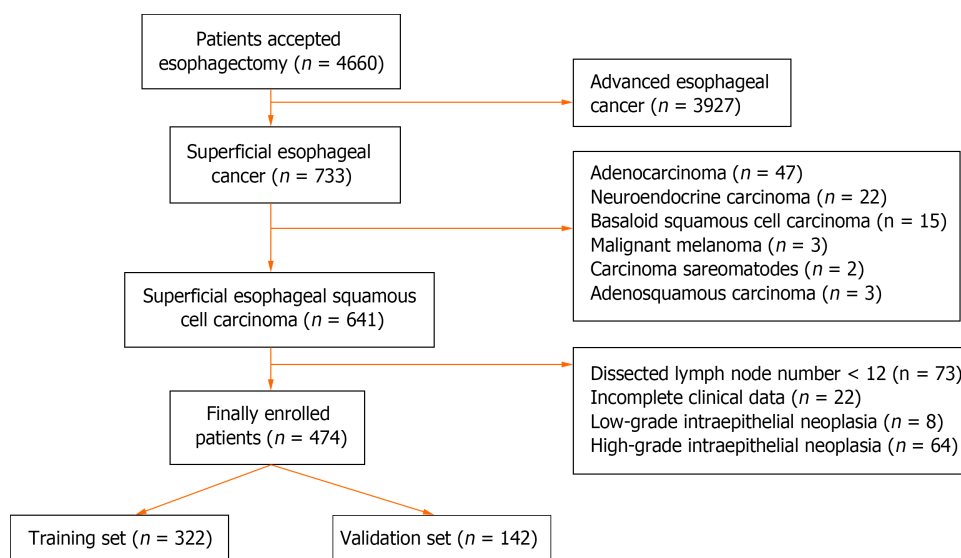
LNM: Lymph node metastasis; MM: Muscularis mucosae; SM1: Upper third of submucosa; INF pattern: Infiltrative growth pattern; LVI: Lymphovascular invasion.

submucosal dissection (ESD) and endoscopic submucosal tunnel dissection (ESTD) can be used to treat lesions limited to the muscularis mucosa and submucosal lesions with invasion depths  $\leq 200$   $\mu\text{m}$ , which have no or an extremely low risk of lymph node metastasis[2,17-19]. The *en bloc* resection rate of ESD for superficial ESCC is 98.2%-100%, and the curative resection rate is 78.2%-96.1%[17-19]. However, patients with a high risk of LNM or noncurative endoscopic resection always need further treatment[4]. Therefore, summarizing post-ESD pathological characteristics and identifying risk factors for predicting LNM are critical to guide post-ESD treatment. In this study, we enrolled superficial ESCC patients who underwent esophagectomy and lymph node dissection and collected detailed pathological information, such as

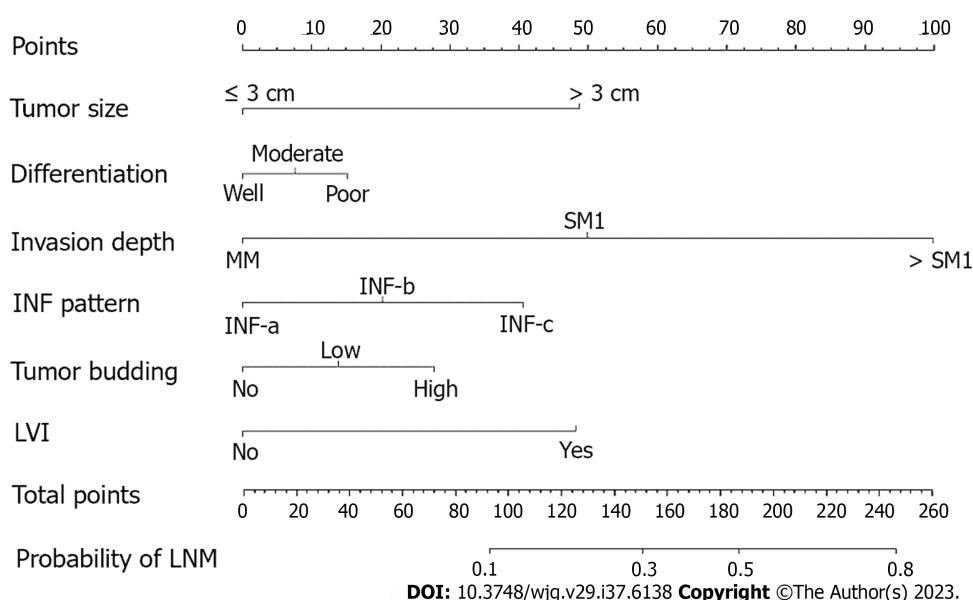
**Table 3** Multivariate logistic analysis of risk factors for lymph node metastasis in superficial esophageal squamous cell carcinoma

Factors	Training set			Validation set		
	OR	95%CI	P value	OR	95%CI	P value
Tumor size (cm)	1.365	1.081-1.723	0.009	1.750	1.139-2.688	0.011
Invasive depth						
MM	Reference			Reference		
SM1	3.774	0.907-15.696	0.068	2.474	0.325-18.856	0.382
> SM1	15.517	4.707-51.158	0.001	11.031	2.463-49.401	0.002
Tumor differentiation						
Well or cis	Reference			Reference		
Moderate	2.423	0.807-9.451	0.072	0.715	0.179-2.856	0.635
Poor	3.670	1.465-9.198	0.006	4.078	0.977-17.026	0.054
INF pattern						
INF-a	Reference			Reference		
INF-b	3.205	1.637-6.274	0.001	3.262	1.114-9.552	0.031
INF-c	4.121	1.566-10.843	0.004	6.360	1.623-24.922	0.008
Tumor budding						
Low	2.114	0.875-5.108	0.096	3.815	0.978-14.813	0.054
High	3.905	1.387-10.995	0.010	4.769	1.315-17.290	0.017
No	Reference			Reference		
LVI						
No	Reference			Reference		
Yes	3.767	1.422-9.979	0.008	4.408	1.346-14.438	0.014

MM: Muscularis mucosae; SM1: Upper third of submucosa; INF pattern: Infiltrative growth pattern; LVI: Lymphovascular invasion.

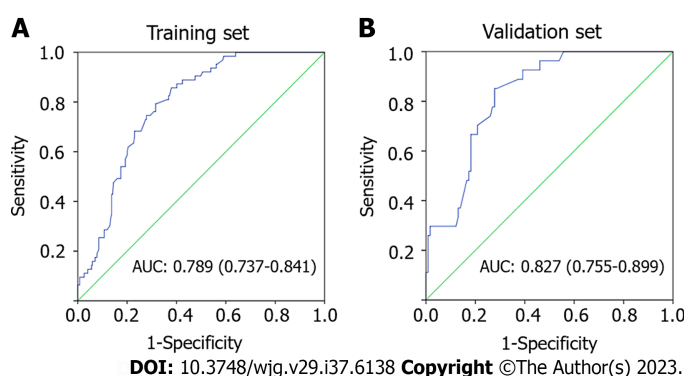
**Figure 1** Flowchart of enrollment process.





**Figure 2** Nomogram for predicting the probability of lymph node metastasis in superficial esophageal squamous cell carcinoma patients.

Calculate the total points of different characteristics, and drop a vertical line from the total points row to obtain the probability of lymph node metastasis. MM: Muscularis mucosae; SM1: Upper third of submucosa; SM2: Middle third of submucosa; SM3: Lower third of submucosa; INF pattern: Infiltrative growth pattern; LVI: Lymphovascular invasion; LNM: Lymph node metastasis.



**Figure 3** Receiver operating characteristics curve of the nomogram for predicting lymph node metastasis. A: Receiver operating characteristics (ROC) curve in the training set; B: ROC curve in the validation set. AUC: Area under the curve.

tumor budding and tumor infiltrative growth pattern, to comprehensively analyze and identify the risk factors for LNM, providing favorable evidence for post-ESD treatment decisions.

Our findings in this study indicated that superficial ESCC patients with positive LNM were more likely to have larger tumors, deeper invasion, poorer differentiation, more INF-c infiltrative patterns, more high-grade tumor budding, and more positive LVI both in both the training and validation sets. Some previous studies have likewise indicated that tumor size is positively correlated with LNM risk[5-8]. Ruan *et al*[8] found that tumor size > 2 cm was an independent risk factor for LNM in superficial ESCC. Our results showed that patients with tumor size > 3 cm had a higher risk of LNM (Figure 2). In another study, it was reported that a 1-cm increase in esophageal tumor length increased the LNM risk by 3.55 times[20]. Therefore, it is necessary to measure the area of cancer cells after the ESD procedure. If possible, pathological recovery should be performed to determine tumor size after the ESD procedure since it is crucial for predicting LNM risk.

In addition, we found that tumor invasion depth is associated with LNM risk. It was reported that the LNM rates of T1a and T1b superficial ESCC were 6.2%-8.0% and 20.0%-29.3%, respectively[21-23]. Similarly, in our study, the LNM rate in T1a tumor was 3.29% (5/152) and increased to 26.40% (85/322) in T1b tumor. Further multivariate analysis showed that an invasion depth deeper than SM1 (OR: 15.517, 95%CI: 4.707-51.158) is an independent risk factor for LNM, which has been confirmed by other studies[5,6]. The esophageal submucosa is an area rich in lymphovascular network, and once intruded into the submucosa, tumor cells are more likely to infiltrate vasculature[24,25]. In our study, LVI positivity (OR: 3.767, 95%CI: 1.422-9.979) was also an independent risk factor for LNM. Therefore, additional treatment, such as surgery or chemoradiotherapy, should be recommended for post-ESD patients with submucosal invasion deeper than 200  $\mu$ m and positive LVI.

It has been well established that the grade of tumor budding is positively correlated with the rate of LNM in solid cancers, including gastrointestinal cancers[26-28]. We found that high-grade tumor budding (OR: 3.905, 95%CI: 1.387-10.995) was positively correlated with LNM risk in superficial ESCC. Similarly, Li *et al*[29] checked tumor budding in pT1b ESCC by using Pan-CK immunohistochemical (IHC) staining and found that the tumor budding level is an excellent predictor of LNM and patient survival time. However, there is no gold standard for differentiating the threshold value of tumor budding in superficial ESCC specimens, and a clear and standardized method for distinguishing and reporting tumor budding in superficial ESCC is urgently needed. In addition, tumor budding status in post-ESD specimens should be carefully assessed and reported.

The Japanese guidelines recommend that tumor infiltrative growth patterns should be reported in esophageal cancer [10]. Some studies have identified infiltrative type c (INF-c) as associated with deep tumor invasion, poor tumor differentiation, and a high risk of LNM[12,30,31]. In our study, multivariate logistic regression identified INF-b (OR: 3.205; 95%CI: 1.637-6.274), INF-c (OR: 4.121, 95%CI: 1.566-10.843) and poor differentiation (OR: 3.670, 95%CI: 1.465-9.198) as independent risk factors for LNM. Invasion of surrounding tissue by cancer cells is a key step in tumor progression and metastasis[32]. As the tumor grows, the morphology and behaviour of cancer cells at the tumor front undergo epithelial mesenchymal transition, detaching from the tumor body and infiltrating deep into the submucosa or even deeper[30]. Poorly differentiated tumors are more likely to have LVI and LNM in superficial ESCC, as previously reported[6,8]. Therefore, a detailed assessment of tumor differentiation, INF pattern, tumor budding, and LVI is critical for predicting LNM risk in post-ESD patients.

Overall, we analyzed the risk factors for LNM in superficial ESCC patients by evaluating detailed pathological characteristics and developed a nomogram by incorporating six variables, including tumor size, invasion depth, tumor differentiation, tumor budding, tumor infiltrative growth pattern and LVI. This nomogram showed good predictive performance, with an AUC of 0.789 (95%CI: 0.737-0.841) in the training set and 0.827 (95%CI: 0.755-0.899) in the validation set. Although the data for this nomogram come from surgical specimens, we believe it is also applicable to post-ESD patients, as all six enrolled predictors can be easily obtained from post-ESD specimens. The use of this predictive nomogram will facilitate the assessment of LNM, thus providing references for guiding post-ESD treatment. However, this is a single-center retrospective study. More multicenter studies are needed to further confirm the reliability of the nomogram.

In addition, this study has some limitations. First, this is a retrospective study, and bias in case selection cannot be avoided. Second, differences in surgical procedures and chronological differences in pathological diagnostic criteria may affect the consistency of the results. D2-40 and CD34 IHC staining were not used in LVI diagnoses in this study, which would lead to underestimating the positivity of LVI. Finally, the LNM rate of superficial ESCC in this study cannot accurately represent the overall LNM rate because patients who underwent ESD were excluded because their postoperative LNM rate could not be calculated.

## CONCLUSION

In conclusion, we identified the risk factors for LNM in superficial ESCC patients and developed a useful nomogram for predicting LNM risk by integrating all significant risk factors. This nomogram model will facilitate decision-making regarding additional treatment options in post-ESD patients.

## ARTICLE HIGHLIGHTS

### Research background

Endoscopic resection of superficial esophageal squamous cell carcinoma (ESCC) is limited to lesions that have no or low risk of lymph node metastasis (LNM). Patients with a high risk of LNM always need further treatment after endoscopic resection.

### Research motivation

Accurately assessing the LNM risk is critical for additional treatment choices for superficial ESCC patients who underwent endoscopic resection.

### Research objectives

This study aimed to analyze the risk factors for LNM and develop a LNM predictive nomogram for superficial ESCC patients.

### Research methods

Clinical and pathological data from superficial ESCC patients underwent esophagectomy from January 1, 2009, to January 31, 2016, were collected and analyzed. A nomogram was performed using R software (version 4.1.3) based on six risk factors of LNM.

### Research results

A total of 474 superficial ESCC patients were enrolled. The prevalence of LNM was 3.29% for intramucosal cancer and



increased to 26.40% for submucosal cancer. A nomogram incorporating six variables, including tumor size, invasion depth, tumor differentiation, tumor budding, tumor infiltrative growth pattern, and lymphovascular invasion, was successfully developed.

### Research conclusions

We developed a useful nomogram model to predict LNM risk for superficial ESCC patients, which will facilitate additional treatment decisions for patients who underwent endoscopic resection.

### Research perspectives

The nomogram model is a simple and useful tool to facilitate the prediction of LNM risk for superficial ESCC patients.

## FOOTNOTES

**Author contributions:** Wang J and Deng K designed and performed the research; Wang J, Zhang X and Gan T collected and analyzed the data; Wang J and Zhang X wrote the manuscript; Deng K, Rao NN and Yang JL supervised the report and revised the manuscript.

**Supported by** the National Natural Science Foundation of China, No. 82173253; the Sichuan Province Science and Technology Support Program, No. 2022YFH0003 and No. 2023NSFSC1900; the Postdoctoral Research Foundation of West China Hospital, No. 2021HXBH020; and the Medico- Engineering Cooperation Funds from the University of Electronic Science and Technology of China and West China Hospital of Sichuan University, No. HXDZ22005.

**Institutional review board statement:** This study was reviewed and approved by the Ethics Committee of West China Hospital of Sichuan University, approval No. 2015(159).

**Informed consent statement:** All study participants who underwent esophagectomy were provided informed written consent prior to surgery.

**Conflict-of-interest statement:** The authors declare no conflicts of interest for this article.

**Data sharing statement:** No additional data are available.

**Open-Access:** This article is an open-access article that was selected by an in-house editor and fully peer-reviewed by external reviewers. It is distributed in accordance with the Creative Commons Attribution NonCommercial (CC BY-NC 4.0) license, which permits others to distribute, remix, adapt, build upon this work non-commercially, and license their derivative works on different terms, provided the original work is properly cited and the use is non-commercial. See: <https://creativecommons.org/licenses/by-nc/4.0/>

**Country/Territory of origin:** China

**ORCID number:** Jin Wang 0009-0007-7281-108X; Xian Zhang 0000-0003-4847-1808; Tao Gan 0000-0002-7331-062X; Ni-Ni Rao 0000-0001-7979-2917; Kai Deng 0000-0002-0096-5211; Jin-Lin Yang 0000-0001-8726-7258.

**S-Editor:** Yan JP

**L-Editor:** A

**P-Editor:** Cai YX

## REFERENCES

- 1 Nishizawa T, Suzuki H. Long-Term Outcomes of Endoscopic Submucosal Dissection for Superficial Esophageal Squamous Cell Carcinoma. *Cancers (Basel)* 2020; **12** [PMID: 33023117 DOI: 10.3390/cancers12102849]
- 2 Pimentel-Nunes P, Libânio D, Bastiaansen BAJ, Bhandari P, Bisschops R, Bourke MJ, Esposito G, Lemmers A, Maselli R, Messmann H, Pech O, Pioche M, Vieth M, Weusten BLAM, van Hooft JE, Deprez PH, Dinis-Ribeiro M. Endoscopic submucosal dissection for superficial gastrointestinal lesions: European Society of Gastrointestinal Endoscopy (ESGE) Guideline - Update 2022. *Endoscopy* 2022; **54**: 591-622 [PMID: 35523224 DOI: 10.1055/a-1811-7025]
- 3 Wang J, Zhu XN, Zhu LL, Chen W, Ma YH, Gan T, Yang JL. Efficacy and safety of endoscopic submucosal tunnel dissection for superficial esophageal squamous cell carcinoma and precancerous lesions. *World J Gastroenterol* 2018; **24**: 2878-2885 [PMID: 30018482 DOI: 10.3748/wjg.v24.i26.2878]
- 4 Hatta W, Koike T, Uno K, Asano N, Masamune A. Management of Superficial Esophageal Squamous Cell Carcinoma and Early Gastric Cancer following Non-Curative Endoscopic Resection. *Cancers (Basel)* 2022; **14** [PMID: 35954421 DOI: 10.3390/cancers14153757]
- 5 Zhang W, Chen H, Zhang G, Jin G. A nomogram for predicting lymph node metastasis in superficial esophageal squamous cell carcinoma. *J Biomed Res* 2021; **35**: 361-370 [PMID: 34628403 DOI: 10.7555/JBR.35.20210034]
- 6 Min BH, Yang JW, Min YW, Baek SY, Kim S, Kim HK, Choi YS, Shim YM, Choi YL, Zo JI. Nomogram for prediction of lymph node metastasis in patients with superficial esophageal squamous cell carcinoma. *J Gastroenterol Hepatol* 2020; **35**: 1009-1015 [PMID: 31674067 DOI: 10.1111/jgh.14915]
- 7 Ma DW, Jung DH, Kim JH, Park JJ, Youn YH, Park H. Predicting lymph node metastasis for endoscopic resection of superficial esophageal

- squamous cell carcinoma. *J Thorac Cardiovasc Surg* 2019; **157**: 397-402.e1 [PMID: 30143376 DOI: 10.1016/j.jtcvs.2018.07.034]
- 8 **Ruan R**, Chen S, Tao Y, Yu J, Zhou D, Cui Z, Shen Q, Wang S. Retrospective analysis of predictive factors for lymph node metastasis in superficial esophageal squamous cell carcinoma. *Sci Rep* 2021; **11**: 16544 [PMID: 34400710 DOI: 10.1038/s41598-021-96088-y]
- 9 The Paris endoscopic classification of superficial neoplastic lesions: esophagus, stomach, and colon: November 30 to December 1, 2002. *Gastrointest Endosc* 2003; **58**: S3-43 [PMID: 14652541 DOI: 10.1016/s0016-5107(03)02159-x]
- 10 **Japan Esophageal Society**. Japanese Classification of Esophageal Cancer, 11th Edition: part I. *Esophagus* 2017; **14**: 1-36 [PMID: 28111535 DOI: 10.1007/s10388-016-0551-7]
- 11 **Rice TW**, Patil DT, Blackstone EH. 8th edition AJCC/UICC staging of cancers of the esophagus and esophagogastric junction: application to clinical practice. *Ann Cardiothorac Surg* 2017; **6**: 119-130 [PMID: 28447000 DOI: 10.21037/acs.2017.03.14]
- 12 **Zhao Y**, Xu E, Yang X, Zhang Y, Chen H, Wang Y, Jin M. Tumor infiltrative growth pattern correlates with the immune microenvironment and is an independent factor for lymph node metastasis and prognosis in stage T1 esophageal squamous cell carcinoma. *Virchows Arch* 2020; **477**: 401-408 [PMID: 32232560 DOI: 10.1007/s00428-020-02801-z]
- 13 **Jesinghaus M**, Brühl F, Steiger K, Klare P, Reiser M, Scheiter A, Konukiewicz B, Kuhn P, Münch S, Quante M, Schmid RM, Wilhelm D, Feith M, Friess H, Combs SE, Saur D, Boxberg M, Weichert W. Cellular Dissociation Grading Based on the Parameters Tumor Budding and Cell Nest Size in Pretherapeutic Biopsy Specimens Allows for Prognostic Patient Stratification in Esophageal Squamous Cell Carcinoma Independent From Clinical Staging. *Am J Surg Pathol* 2019; **43**: 618-627 [PMID: 30807302 DOI: 10.1097/PAS.0000000000001230]
- 14 **Beer A**, Reber A, Paireder M, Schoppmann SF, Heber S, Schiefer AI. Tumor cell budding in preoperative biopsies of esophageal and gastroesophageal junction carcinoma independently predicts survival in a grade-dependent manner. *Surgery* 2022; **172**: 567-574 [PMID: 35422326 DOI: 10.1016/j.surg.2022.02.020]
- 15 **Balachandran VP**, Gonen M, Smith JJ, DeMatteo RP. Nomograms in oncology: more than meets the eye. *Lancet Oncol* 2015; **16**: e173-e180 [PMID: 25846097 DOI: 10.1016/S1470-2045(14)71116-7]
- 16 **Min YW**, Lee H, Song BG, Min BH, Kim HK, Choi YS, Lee JH, Hwang NY, Carriere KC, Rhee PL, Kim JJ, Zo JI, Shim YM. Comparison of endoscopic submucosal dissection and surgery for superficial esophageal squamous cell carcinoma: a propensity score-matched analysis. *Gastrointest Endosc* 2018; **88**: 624-633 [PMID: 29750981 DOI: 10.1016/j.gie.2018.04.2360]
- 17 **Li P**, Ma B, Gong S, Zhang X, Li W. Endoscopic submucosal tunnel dissection for superficial esophageal neoplastic lesions: a meta-analysis. *Surg Endosc* 2020; **34**: 1214-1223 [PMID: 31161293 DOI: 10.1007/s00464-019-06875-y]
- 18 **Gong J**, Zhou BY, Liang CB, Zhou HJ, Wang HY, Tan YY, Liu DL. Comparison between tunneling and standard endoscopic submucosal dissection for treatment of large esophageal superficial neoplasm. *Acta Gastroenterol Belg* 2019; **82**: 469-474 [PMID: 31950800]
- 19 **Huang R**, Cai H, Zhao X, Lu X, Liu M, Lv W, Liu Z, Wu K, Han Y. Efficacy and safety of endoscopic submucosal tunnel dissection for superficial esophageal squamous cell carcinoma: a propensity score matching analysis. *Gastrointest Endosc* 2017; **86**: 831-838 [PMID: 28286094 DOI: 10.1016/j.gie.2017.03.001]
- 20 **Haisley KR**, Hart KD, Fischer LE, Kunio NR, Bakis G, Tieu BH, Schipper PH, Sheppard BC, Hunter JG, Dolan JP. Increasing tumor length is associated with regional lymph node metastases and decreased survival in esophageal cancer. *Am J Surg* 2016; **211**: 860-866 [PMID: 26993752 DOI: 10.1016/j.amjsurg.2016.01.007]
- 21 **Dubecz A**, Kern M, Solymosi N, Schweigert M, Stein HJ. Predictors of Lymph Node Metastasis in Surgically Resected T1 Esophageal Cancer. *Ann Thorac Surg* 2015; **99**: 1879-85; discussion 1886 [PMID: 25929888 DOI: 10.1016/j.athoracsur.2015.02.112]
- 22 **Duan XF**, Tang P, Shang XB, Jiang HJ, Yu ZT. The prevalence of lymph node metastasis for pathological T1 esophageal cancer: a retrospective study of 143 cases. *Surg Oncol* 2018; **27**: 1-6 [PMID: 29549895 DOI: 10.1016/j.suronc.2017.11.002]
- 23 **Xu W**, Liu XB, Li SB, Yang ZH, Tong Q. Prediction of lymph node metastasis in superficial esophageal squamous cell carcinoma in Asia: a systematic review and meta-analysis. *Dis Esophagus* 2020; **33** [PMID: 32399558 DOI: 10.1093/dote/daaa032]
- 24 **Ruan R**, Chen S, Tao Y, Yu J, Zhou D, Cui Z, Shen Q, Wang S. A Nomogram for Predicting Lymphovascular Invasion in Superficial Esophageal Squamous Cell Carcinoma. *Front Oncol* 2021; **11**: 663802 [PMID: 34041028 DOI: 10.3389/fonc.2021.663802]
- 25 **Yang J**, Lu Z, Li L, Li Y, Tan Y, Zhang D, Wang A. Relationship of lymphovascular invasion with lymph node metastasis and prognosis in superficial esophageal carcinoma: systematic review and meta-analysis. *BMC Cancer* 2020; **20**: 176 [PMID: 32131772 DOI: 10.1186/s12885-020-6656-3]
- 26 **Lugli A**, Zlobec I, Berger MD, Kirsch R, Nagtegaal ID. Tumour budding in solid cancers. *Nat Rev Clin Oncol* 2021; **18**: 101-115 [PMID: 32901132 DOI: 10.1038/s41571-020-0422-y]
- 27 **Yao G**, Fang Y, Fu Y, Xu J, Song H, Zhu H, Gu M, Ding X. Tumor budding as an indicator for lymph node metastasis and prognosis of early gastric cancer. *J Cancer Res Clin Oncol* 2023; **149**: 5603-5616 [PMID: 36512103 DOI: 10.1007/s00432-022-04522-z]
- 28 **Archilla I**, Díaz-Mercedes S, Aguirre JJ, Tarragona J, Machado I, Rodrigo MT, Lopez-Prades S, Gorostiaga I, Landolfi S, Alén BO, Balaguer F, Castells A, Camps J, Cuatrecasas M. Lymph Node Tumor Burden Correlates With Tumor Budding and Poorly Differentiated Clusters: A New Prognostic Factor in Colorectal Carcinoma? *Clin Transl Gastroenterol* 2021; **12**: e00303 [PMID: 33939382 DOI: 10.14309/ctg.0000000000000303]
- 29 **Li Z**, Liu L, Wang B, Ying J, He J, Xue L. Tumor budding and tumor-infiltrating lymphocytes can predict prognosis in pT1b esophageal squamous cell carcinoma. *Thorac Cancer* 2023; **14**: 2608-2617 [PMID: 37466146 DOI: 10.1111/1759-7714.15043]
- 30 **Anciaux M**, Demetter P, De Wind R, Gomez Galdon M, Vande Velde S, Lens G, Craciun L, Deleruelle A, Larsimont D, Lenaerts T, Sclafani F, Deleporte A, Donckier V, Hendlisz A, Vandeputte C. Infiltrative tumour growth pattern correlates with poor outcome in oesophageal cancer. *BMJ Open Gastroenterol* 2020; **7** [PMID: 32675198 DOI: 10.1136/bmjgast-2020-000431]
- 31 **Ebisumoto K**, Okami K, Ogura G, Sakai A, Sugimoto R, Saito K, Kaneda S, Hanakita T, Nakamura N, Iida M. The predictive role of infiltrative growth pattern in early pharyngeal cancers. *Acta Otolaryngol* 2015; **135**: 1172-1177 [PMID: 26223893]
- 32 **de Visser KE**, Joyce JA. The evolving tumor microenvironment: From cancer initiation to metastatic outgrowth. *Cancer Cell* 2023; **41**: 374-403 [PMID: 36917948 DOI: 10.1016/j.ccell.2023.02.016]



Published by **Baishideng Publishing Group Inc**  
7041 Koll Center Parkway, Suite 160, Pleasanton, CA 94566, USA

**Telephone:** +1-925-3991568

**E-mail:** [bpgoffice@wjgnet.com](mailto:bpgoffice@wjgnet.com)

**Help Desk:** <https://www.f6publishing.com/helpdesk>

<https://www.wjgnet.com>

