



## Advancements in medical treatment for pancreatic neuroendocrine tumors: A beacon of hope

Somdatta Giri, Jayaprakash Sahoo

**Specialty type:** Gastroenterology and hepatology

**Provenance and peer review:** Invited article; Externally peer reviewed.

**Peer-review model:** Single blind

**Peer-review report's scientific quality classification**

Grade A (Excellent): 0  
Grade B (Very good): 0  
Grade C (Good): 0  
Grade D (Fair): 0  
Grade E (Poor): 0

**P-Reviewer:** Yin CH, China

**Received:** December 28, 2023

**Peer-review started:** December 28, 2023

**First decision:** January 19, 2024

**Revised:** January 29, 2024

**Accepted:** March 7, 2024

**Article in press:** March 7, 2024

**Published online:** March 28, 2024



**Somdatta Giri, Jayaprakash Sahoo**, Department of Endocrinology and Metabolism, Jawaharlal Institute of Postgraduate Medical Education and Research, Puducherry, 605006, India

**Corresponding author:** Jayaprakash Sahoo, MBBS, MD, DM, Full Professor, Department of Endocrinology and Metabolism, Jawaharlal Institute of Postgraduate Medical Education and Research, D. Nagar, Gorimedu, JIPMER Campus, Puducherry 605006, India.  
[jppgi@yahoo.com](mailto:jppgi@yahoo.com)

### Abstract

This editorial highlights the remarkable advancements in medical treatment strategies for pancreatic neuroendocrine tumors (pan-NETs), emphasizing tailored approaches for specific subtypes. Cytoreductive surgery and somatostatin analogs (SSAs) play pivotal roles in managing tumors, while palliative options such as molecular targeted therapy, peptide receptor radionuclide therapy, and chemotherapy are reserved for SSA-refractory patients. Gastrinomas, insulinomas, glucagonomas, carcinoid tumors and VIPomas necessitate distinct therapeutic strategies. Understanding the genetic basis of pan-NETs and exploring immunotherapies could lead to promising avenues for future research. This review underscores the evolving landscape of pan-NET treatment, offering renewed hope and improved outcomes for patients facing this complex disease.

**Key Words:** Pancreatic neuroendocrine tumor; Medical management; Somatostatin analog; Immunotherapy; Everolimus

©The Author(s) 2024. Published by Baishideng Publishing Group Inc. All rights reserved.

**Core Tip:** The evolving landscape of pancreatic neuroendocrine tumor treatment showcases tailored approaches based on tumor subtype. Cytoreductive surgery and somatostatin analogs are pivotal, whereas peptide receptor radionuclide therapy and molecular targeted agents are offering hope for refractory cases. Understanding genetic markers and exploring immunotherapies open promising avenues for future research.

**Citation:** Giri S, Sahoo J. Advancements in medical treatment for pancreatic neuroendocrine tumors: A beacon of hope. *World J Gastroenterol* 2024; 30(12): 1670-1675

**URL:** <https://www.wjgnet.com/1007-9327/full/v30/i12/1670.htm>

**DOI:** <https://dx.doi.org/10.3748/wjg.v30.i12.1670>

## INTRODUCTION

Pancreatic neuroendocrine tumors (pan-NETs) present unique challenges in the field of oncology. These tumors account for 1%-2% of all pancreatic cancers and are mostly sporadic. Sometimes, pan-NETs are associated with various syndromes, such as multiple endocrine neoplasia 1 (MEN1), von Hippel-Lindau disease, tuberous sclerosis or neurofibromatosis. Often, these tumors are diagnosed at an advanced stage in the course of disease with metastasis to multiple organs, making curative surgery less successful. The role of medical therapy is as follows.

### Pan-NETs

Most patients with advanced pan-NETs (50%-75%) have nonfunctioning tumors and do not have any associated hormonal syndrome. Somatostatin analogs (SSAs) provide a valuable palliative option by reducing hormonal secretion as well as the tumor burden. The European Neuroendocrine Tumor Society, North American Neuroendocrine Society, and National Comprehensive Cancer Network suggest the initiation of SSA in patients with unresectable, asymptomatic, well-differentiated pan-NETs and a high tumor burden, as SSAs have been shown to improve survival in the PROMID[1] and CLARINET trials[2]. Treatment of highly symptomatic patients may be initiated with short-acting octreotide with rapid transition to a long-acting formulation (LAR) and subsequent titration of the dose to optimize symptom control while the LAR formulation is starting to take effect (approximately 10-14 d). The depot preparation, *e.g.*, octreotide LAR, has largely eliminated the need for daily octreotide injections. Patients may use additional short-acting octreotide for breakthrough symptoms while doses are being titrated. Lanreotide can be administered once monthly *via* deep subcutaneous injection and appears to have efficacy similar to that of octreotide.

Notably, molecular targeted therapies, peptide receptor radionuclide therapy (PRRT), and chemotherapy are typically reserved for patients refractory to SSAs[3]. According to recent European Society of Medical Oncology guidelines, the mammalian target of rapamycin (mTOR) inhibitor everolimus is recommended for the treatment of G1/G2 pan-NETs[4]. A good treatment effect of everolimus was also recorded irrespective of the volume of liver metastasis in the RADIANT-4 trial[5]. Everolimus in combination with SSAs in advanced and metastatic pan-NETs demonstrated greater benefit than everolimus monotherapy in the RADIANT-1 and RADIANT-3 trials. In contrast to these data, the combination of everolimus with pasireotide did not prove to exert any further benefit. Everolimus should be carefully co-administered with glucocorticoids since, in the RADIANT-3 cohort, their combination resulted in a fatal episode of acute respiratory distress, as everolimus can cause immunosuppression. The progression-free survival (PFS) associated with the combination of everolimus and metformin was better than that associated with everolimus alone[6]. The mechanisms affected by metformin include a reduction in blood glucose, insulin, and insulin like growth factor-1 levels; inhibition of mitochondrial oxidation; activation of AMP-activated protein kinase; and antibacterial cell autonomy *via* mTOR inhibition as well as oncogenic effects.

PRRT has emerged as a beacon of hope for patients with metastatic but low-grade pan-NETs where curative surgery is not possible. This targeted therapy utilizes radionuclides to deliver systemic treatment. In the NETTER-1 trial, patients who received <sup>177</sup>Lu-DOTATATE with SSA experienced a 54.4% increase in estimated PFS at 20 months *vs* SSA alone[7].

On the other hand, neuroendocrine carcinoma (NEC) is genetically more similar to pancreatic cancer than to G1/G2 neuroendocrine tumors (NETs). Here comes the role of chemotherapy. Capecitabine plays synergistic role with temozolomide, perhaps by downregulating the DNA repair enzyme methylguanine methyltransferase. Although combined therapy is more effective for treating pan-NET, overall survival in patients with NEC is not rewarding (22 *vs* 4.6 months) [8]. In NEC patients, cisplatin-based therapy with etoposide or irinotecan remains the standard first-line chemotherapy option[9]. Distinguished clinical trials related to the management of pan-NETs are summarized in Table 1.

### Gastrinomas

In gastrinomas, where surgical intervention might pose significant risks, medical therapy with high-dose proton pump inhibitor therapy (PPI) with or without SSAs can effectively control symptoms and tumor growth. Patients without imageable pancreatic tumors in MEN1 exhibit promising survival rates, *i.e.*, 5-year survival rates of approximately 90% and a 10-year survival rate of 54% in patients with disseminated distant metastasis, underscoring the importance of tailored approaches[10]. Long-acting PPIs such as omeprazole 60 mg a day or an equivalent dose of other PPIs once or twice a day are durable and effective in patients with sporadic gastrinoma without evidence of tachyphylaxis. The goal of PPI therapy is to restrict basal acid output to < 10 mEq/h during the hour before the next dose. Patients with MEN1-related gastrinoma may require a daily dose of 80-120 mg of omeprazole. Effective treatment of hypercalcemia in MEN1 patients is of paramount importance because it reduces gastric acid hypersecretion. It is advised to continue PPI therapy for at least 3-6 months after resection of the tumor due to the continued risk of gastroesophageal reflux disease complications caused by the increased parietal cell mass. Vigilance is required for potential side effects of long-term PPI therapy, such as vitamin B12 deficiency, hypomagnesemia and the risk of bone fracture. The role of SSA in PPI refractory patients was well documented in a retrospective study of 12 patients with gastrinoma[11]. In this study, all but one patient achieved complete clinical control with octreotide or lanreotide.

**Table 1 Clinical trials related to medical therapy in pancreatic neuroendocrine tumours**

Trial	Population	Study design	Drug	NET	Outcome
PROMID	85	RCT	Octreotide LAR	Metastatic Midgut NET	PFS 14.3 <i>vs</i> 6 m
CLARINET	204	RCT	Lanreotide	G1, G2 non-functioning NET	32% increase in PFS at 24 m
RADIANT 4	302	RCT	Everolimus	Non-functioning NET	PFS 11 <i>vs</i> 4 m; 52% reduction of death
Kurita <i>et al</i> [6]	100	Retrospective	Everolimus	Pan-NET	PFS is longer with G1, G2 than G3, NEC; Metformin increases PFS
NETTER 1	229	RCT	Lu DOTATATE with Octreotide LAR	Metastatic Midgut NET	54.4% increase in PFS at 20 m
Rogowski <i>et al</i> [8]	32	retrospective	capecitabine and temozolomide	G3 NET	PFS 15.3 m in G3 NET, 3.3 m in NEC
Morizane <i>et al</i> [9]	170	RCT	etoposide and cisplatin <i>vs</i> irinotecan and cisplatin	NEC	PFS 5.6 months in EP <i>vs</i> 5.1 months in IP
Bernard <i>et al</i> [13]	12	Retrospective	Everolimus	Malignant insulinoma	Hypoglycemia resolve in 11/12. Median recurrence at 6.5 m
TELECAST	76	RCT	Telotristat ethyl	Carcinoid syndrome	Sustained reductions in u5-HIAA and diarrhea

NET: Neuroendocrine tumor; RCT: Randomized control trial; PFS: Progression-free survival; NEC: Neuroendocrine carcinoma; LAR: Long-acting release.

### Insulinomas

Insulinomas present a unique challenge, as patients develop hypoglycemia. Diazoxide (50-600 mg daily) is the primary medical therapy, and in refractory cases, glucocorticoids, verapamil, and diphenylhydantoin may be considered. SSAs can reduce insulin levels and are pivotal for the antiproliferative control of well-differentiated tumors. Since there is usually low expression of somatostatin receptor type (SSTR) 2 in benign insulinomas, SSA therapy may result in paradoxical worsening of hypoglycemia, as it also decreases glucagon secretion. In contrast, advanced insulinomas usually express SSTR2 and SSTR5. The pan-somatostatin receptor agonist pasireotide is a promising option for patients with refractory hypoglycemia, especially for those with metastatic insulinoma[12]. Akt/mTOR pathway is abnormally activated in NETs. Everolimus has both antineoplastic and antisecretory effects as shown in Figure 1 and has been successfully tested for refractory insulinoma[13]. However, exhaustion of its antineoplastic effect is observed after 2 years due to downregulation of mediators involved in the mTOR pathway instead of a true resistance[14]. Therefore, rechallenge with everolimus can be considered since this phenomenon appears to be transient.

### Glucagonomas

For glucagonomas, SSAs are considered first-line treatments, as they have shown remarkable efficacy in controlling hormonal symptoms. In advanced cases, management must include SSAs to improve patient performance status, enabling surgical options to be considered[14]. Amino acid infusion and zinc therapy have shown promise in improving skin lesions associated with necrolytic migratory erythema.

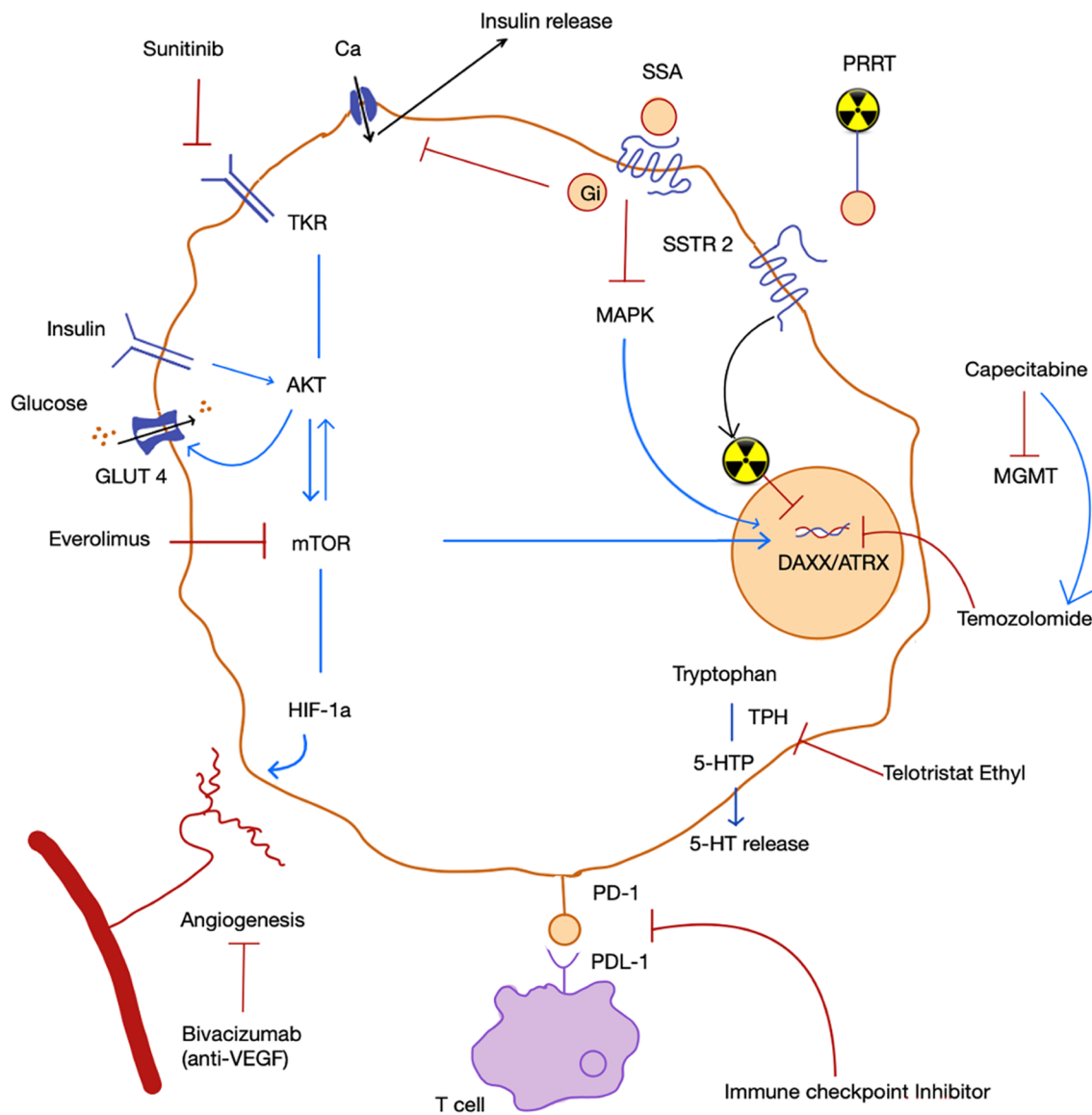
### VIPoma

VIPoma can cause severe and life-threatening diarrhea. Supportive care with intravenous fluids and electrolytes is crucial. SSAs have shown substantial promise in improving VIPoma-associated symptoms. Chemotherapy and sunitinib improved diarrhea in 10 out of 12 patients in a French study. Hypercalcemia associated with VIPoma is caused by the secretion of parathyroid hormone-related peptide and responds well to both zoledronate and denosumab[15].

### Carcinoid syndrome

Management of crisis due to carcinoid syndrome is a medical emergency that requires the infusion of octreotide along with serotonin antagonists such as ondansetron, cyproheptadine, and ranitidine. A bolus of octreotide 100-500 µg should be immediately administered, followed by a maintenance dose of 50-100 µg/h (maximum 500 µg/h). Sympathomimetics can precipitate hormonal release by the tumor, paradoxically leading to distributive shock, and should be used cautiously. However, if a patient needs to be on sympathomimetics, the selective alpha1-agonist phenylephrine and vasopressin are the preferred vasopressors in this context.

For the prophylaxis for carcinoid crisis, SSAs can be started before surgery or before PRRT. It is advised to keep SSA-free period before the start of PRRT as short as possible (8-24 h), with safe reintroduction of SSA 1 h after the infusion of <sup>177</sup>Lu-DOTATATE in order to prevent functioning symptoms deterioration due to release of hormone following PRRT. Antidiarrheal agents such as loperamide are also useful. However, refractory diarrhea responds well to telotristat ethyl, a tryptophan hydroxylase inhibitor[16]. Patients with niacin deficiency or pellagra should be started on nicotinamide. A



**Figure 1 Mechanism of action various medical therapeutics.** Everolimus by inhibiting mammalian target of rapamycin pathway can decrease cell proliferation as well as insulin action by suppressing AKT. Somatostatin analog can suppress hormone release by inhibiting Calcium channel and decrease proliferation by suppressing Mitogen activated protein kinase. Temozolomide being an alkylating agent cause DNA damage. Capecitabine augment its activity by reducing methylguanine-DNA methyltransferase which is a DNA repair enzyme. Red lines are used to show inhibition and blue lines are used to show stimulation. GLUT 4: Glucose transporter 4, HIF-1 $\alpha$ : Hypoxia inducible factor 1 alpha; 5-HTP: 5 hydroxytryptophan; 5-HT: 5 hydroxy tryptamines; MAPK: Mitogen activated protein kinase; MGMT: Methylguanine-DNA methyltransferase; mTOR: Mammalian target of rapamycin; PD-1: Programmed cell death-1; TKR: Tyrosine kinase receptor; TPH: Tryptophan hydroxylase; VEGF: Vascular endothelial growth factor; SSA: Somatostatin analog.

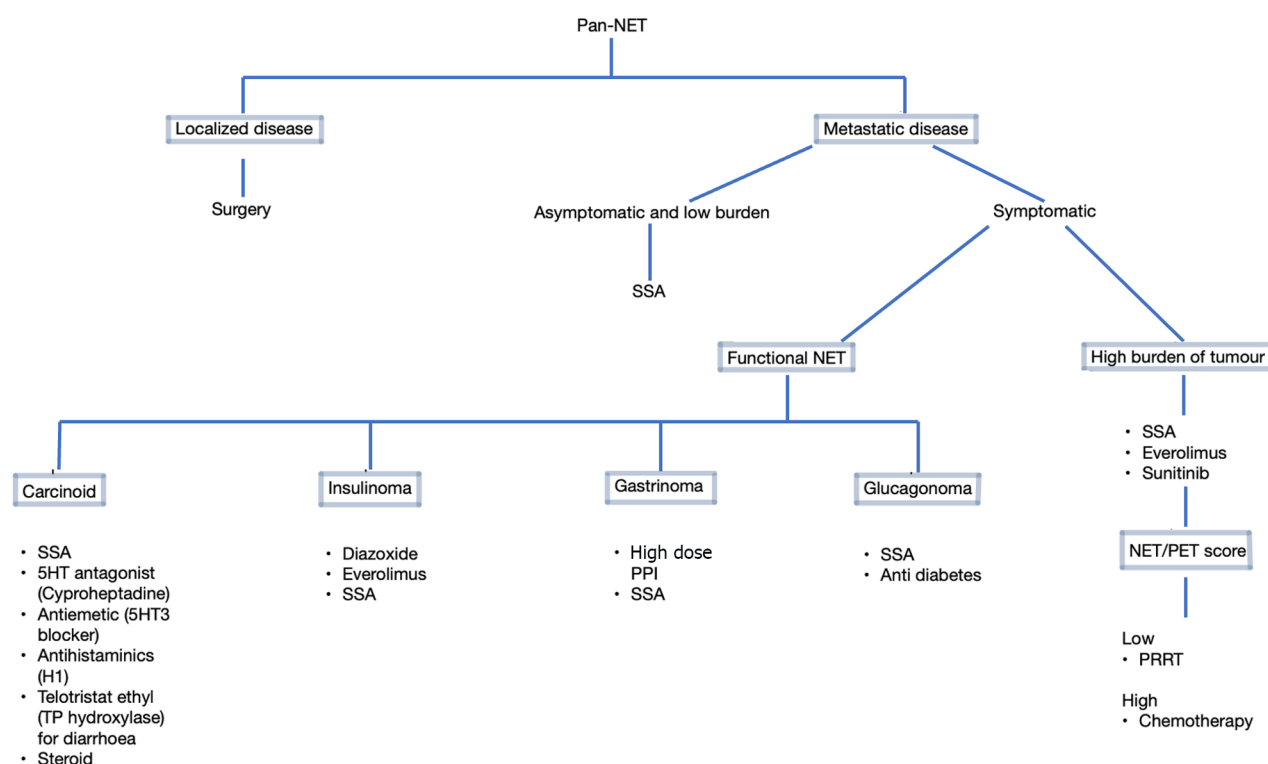
simplified flow diagram showing approach to medical therapy in pan-NETs is depicted in **Figure 2**.

### Future medical therapy in pan-NETs

Elucidating the genetic underpinnings of different pan-NET subtypes opens new avenues for tailored therapies. Mutations in genes such as *DAXX/ATR*, *EPHB4*, *ROS1*, and *KMT2A* provide potential targets for future research[17]. Compared to NETs of extra-pancreatic origin, pan-NETs have higher expression levels of programmed cell death protein 1 (PD-1) and more tumor-infiltrating lymphocytes[18]. Immunotherapies, particularly PD-1 inhibitors, in combination with anti-vascular endothelial growth factor (bevacizumab) have shown potential in controlling pan-NETs.

## CONCLUSION

The landscape of pan-NET treatment has evolved significantly, offering patients a more tailored and effective approach. From surgical interventions to targeted therapies and immunomodulatory agents, advancements in medical treatment for pan-NETs represent a beacon of hope for those facing this challenging disease. As research continues to uncover the intricacies of this condition, we can look forward to even more promising developments in the future.



**Figure 2 Approach to medical therapy in pancreatic neuroendocrine tumors.** SSA: Somatostatin analog; PPI: Proton pump inhibitor; Pan-NET: Pancreatic neuroendocrine tumor; PRRT: Peptide receptor radionuclide therapy.

## FOOTNOTES

**Author contributions:** Giri S did the literature search, wrote the first draft and gave intellectual input; Sahoo J conceptualized the work, supervised the writing, gave intellectual inputs, and critically revised the manuscript.

**Conflict-of-interest statement:** All authors have no conflict of interest to report.

**Open-Access:** This article is an open-access article that was selected by an in-house editor and fully peer-reviewed by external reviewers. It is distributed in accordance with the Creative Commons Attribution NonCommercial (CC BY-NC 4.0) license, which permits others to distribute, remix, adapt, build upon this work non-commercially, and license their derivative works on different terms, provided the original work is properly cited and the use is non-commercial. See: <https://creativecommons.org/licenses/by-nc/4.0/>

**Country/Territory of origin:** India

**ORCID number:** Somdatta Giri 0000-0002-3464-7860; Jayaprakash Sahoo 0000-0002-8805-143X.

**S-Editor:** Qu XL

**L-Editor:** A

**P-Editor:** Cai YX

## REFERENCES

- Rinke A, Wittenberg M, Schade-Brittinger C, Aminossadati B, Ronicke E, Gress TM, Müller HH, Arnold R; PROMID Study Group. Placebo-Controlled, Double-Blind, Prospective, Randomized Study on the Effect of Octreotide LAR in the Control of Tumor Growth in Patients with Metastatic Neuroendocrine Midgut Tumors (PROMID): Results of Long-Term Survival. *Neuroendocrinology* 2017; **104**: 26-32 [PMID: 26731483 DOI: 10.1159/000443612]
- Caplin ME, Pavel M, Ruzsniwski P. Lanreotide in metastatic enteropancreatic neuroendocrine tumors. *N Engl J Med* 2014; **371**: 1556-1557 [PMID: 25317881 DOI: 10.1056/NEJMc1409757]
- Hofland J, Falconi M, Christ E, Castaño JP, Faggiano A, Lamarca A, Perren A, Petrucci S, Prasad V, Ruzsniwski P, Thirlwell C, Vullierme MP, Welin S, Bartsch DK. European Neuroendocrine Tumor Society 2023 guidance paper for functioning pancreatic neuroendocrine tumour syndromes. *J Neuroendocrinol* 2023; **35**: e13318 [PMID: 37578384 DOI: 10.1111/jne.13318]
- Pavel M, Öberg K, Falconi M, Krenning EP, Sundin A, Perren A, Berruti A; ESMO Guidelines Committee. Gastroenteropancreatic neuroendocrine neoplasms: ESMO Clinical Practice Guidelines for diagnosis, treatment and follow-up. *Ann Oncol* 2020; **31**: 844-860 [PMID: 32272208 DOI: 10.1016/j.annonc.2020.03.304]



- 5 **Yao JC**, Fazio N, Singh S, Buzzoni R, Carnaghi C, Wolin E, Tomasek J, Raderer M, Lahner H, Voi M, Pacaud LB, Rouyrre N, Sachs C, Valle JW, Fave GD, Van Cutsem E, Tesselar M, Shimada Y, Oh DY, Strosberg J, Kulke MH, Pavel ME; RAD001 in Advanced Neuroendocrine Tumours, Fourth Trial (RADIANT-4) Study Group. Everolimus for the treatment of advanced, non-functional neuroendocrine tumours of the lung or gastrointestinal tract (RADIANT-4): a randomised, placebo-controlled, phase 3 study. *Lancet* 2016; **387**: 968-977 [PMID: [26703889](#) DOI: [10.1016/S0140-6736\(15\)00817-X](#)]
- 6 **Kurita Y**, Kobayashi N, Hara K, Mizuno N, Kuwahara T, Okuno N, Haba S, Tokuhisa M, Hasegawa S, Sato T, Hosono K, Kato S, Kessoku T, Endo I, Shimizu Y, Kubota K, Nakajima A, Ichikawa Y, Niwa Y. Effectiveness and Prognostic Factors of Everolimus in Patients with Pancreatic Neuroendocrine Neoplasms. *Intern Med* 2023; **62**: 159-167 [PMID: [35705270](#) DOI: [10.2169/internalmedicine.9416-22](#)]
- 7 **Strosberg J**, El-Haddad G, Wolin E, Hendifar A, Yao J, Chasen B, Mittra E, Kunz PL, Kulke MH, Jacene H, Bushnell D, O'Dorisio TM, Baum RP, Kulkarni HR, Caplin M, Lebtahi R, Hobday T, Delpassand E, Van Cutsem E, Benson A, Srirajaskanthan R, Pavel M, Mora J, Berlin J, Grande E, Reed N, Seregni E, Öberg K, Lopera Sierra M, Santoro P, Thevenet T, Erion JL, Ruzsniwski P, Kwekkeboom D, Krenning E; NETTER-1 Trial Investigators. Phase 3 Trial of (177)Lu-Dotatate for Midgut Neuroendocrine Tumors. *N Engl J Med* 2017; **376**: 125-135 [PMID: [28076709](#) DOI: [10.1056/NEJMoa1607427](#)]
- 8 **Rogowski W**, Wachuła E, Gorzelak A, Lebedzińska A, Sulżyc-Bielicka V, Iżycka-Świeszewska E, Żołnierkiewicz J, Kos-Kudła B. Capecitabine and temozolomide combination for treatment of high-grade, well-differentiated neuroendocrine tumour and poorly-differentiated neuroendocrine carcinoma - retrospective analysis. *Endokrynol Pol* 2019; **70**: 313-317 [PMID: [30843182](#) DOI: [10.5603/EP.a2019.0010](#)]
- 9 **Morizane C**, Machida N, Honma Y, Okusaka T, Boku N, Kato K, Nomura S, Hiraoka N, Sekine S, Taniguchi H, Okano N, Yamaguchi K, Sato T, Ikeda M, Mizuno N, Ozaka M, Kataoka T, Ueno M, Kitagawa Y, Terashima M, Furuse J; Japan Clinical Oncology Group (JCOG). Effectiveness of Etoposide and Cisplatin vs Irinotecan and Cisplatin Therapy for Patients With Advanced Neuroendocrine Carcinoma of the Digestive System: The TOPIC-NEC Phase 3 Randomized Clinical Trial. *JAMA Oncol* 2022; **8**: 1447-1455 [PMID: [35980649](#) DOI: [10.1001/jamaoncol.2022.3395](#)]
- 10 **Norton JA**, Alexander HR, Fraker DL, Venzon DJ, Gibril F, Jensen RT. Comparison of surgical results in patients with advanced and limited disease with multiple endocrine neoplasia type 1 and Zollinger-Ellison syndrome. *Ann Surg* 2001; **234**: 495-505; discussion 505 [PMID: [11573043](#) DOI: [10.1097/0000658-200110000-00009](#)]
- 11 **Massironi S**, Cavalcoli F, Elvevi A, Quatrini M, Invernizzi P. Somatostatin analogs in patients with Zollinger Ellison syndrome (ZES): an observational study. *Endocrine* 2022; **75**: 942-948 [PMID: [34716542](#) DOI: [10.1007/s12020-021-02915-7](#)]
- 12 **Siddiqui M**, Vora A, Ali S, Abramowitz J, Mirfakhraee S. Pasireotide: A Novel Treatment for Tumor-Induced Hypoglycemia Due to Insulinoma and Non-Islet Cell Tumor Hypoglycemia. *J Endocr Soc* 2021; **5**: bvaa171 [PMID: [33294765](#) DOI: [10.1210/endo/bvaa171](#)]
- 13 **Bernard V**, Lombard-Bohas C, Taquet MC, Caroli-Bosc FX, Ruzsniwski P, Niccoli P, Guimbaud R, Chougnet CN, Goichot B, Rohmer V, Borson-Chazot F, Baudin E; French Group of Endocrine Tumors. Efficacy of everolimus in patients with metastatic insulinoma and refractory hypoglycemia. *Eur J Endocrinol* 2013; **168**: 665-674 [PMID: [23392213](#) DOI: [10.1530/EJE-12-1101](#)]
- 14 **Alexandraki KI**, Kaltsas GA, Grozinsky-Glasberg S. Emerging therapies for advanced insulinomas and glucagonomas. *Endocr Relat Cancer* 2023; **30** [PMID: [37343152](#) DOI: [10.1530/ERC-23-0020](#)]
- 15 **Giannetta E**, Sesti F, Modica R, Grossrubatscher EM, Guarnotta V, Ragni A, Zanata I, Colao A, Faggiano A. Case Report: Unmasking Hypercalcemia in Patients With Neuroendocrine Neoplasms. Experience From Six Italian Referral Centers. *Front Endocrinol (Lausanne)* 2021; **12**: 665698 [PMID: [34093441](#) DOI: [10.3389/fendo.2021.665698](#)]
- 16 **Pavel M**, Gross DJ, Benavent M, Perros P, Srirajaskanthan R, Warner RRP, Kulke MH, Anthony LB, Kunz PL, Hörsch D, Weickert MO, Lapuerta P, Jiang W, Kassler-Taub K, Wason S, Fleming R, Fleming D, Garcia-Carbonero R. Telotristat ethyl in carcinoid syndrome: safety and efficacy in the TELECAST phase 3 trial. *Endocr Relat Cancer* 2018; **25**: 309-322 [PMID: [29330194](#) DOI: [10.1530/ERC-17-0455](#)]
- 17 **Burns L**, Naimi B, Ronan M, Xu H, Weber HC. Report of a Novel Molecular Profile in Malignant Insulinoma. *J Clin Med* 2023; **12** [PMID: [36835815](#) DOI: [10.3390/jcm12041280](#)]
- 18 **Bösch F**, Bräuer K, Altendorf-Hofmann A, Auernhammer CJ, Spitzweg C, Westphalen CB, Boeck S, Schubert-Fritschle G, Werner J, Heinemann V, Kirchner T, Angele M, Knösel T. Immune checkpoint markers in gastroenteropancreatic neuroendocrine neoplasia. *Endocr Relat Cancer* 2019; **26**: 293-301 [PMID: [30608901](#) DOI: [10.1530/ERC-18-0494](#)]



Published by **Baishideng Publishing Group Inc**  
7041 Koll Center Parkway, Suite 160, Pleasanton, CA 94566, USA

**Telephone:** +1-925-3991568

**E-mail:** [office@baishideng.com](mailto:office@baishideng.com)

**Help Desk:** <https://www.f6publishing.com/helpdesk>

<https://www.wjgnet.com>

