



Retrospective Study

# Evaluation of the efficacy and safety of endoscopic band ligation in the treatment of bleeding from mild to moderate gastric varices type 1

Yue Deng, Ya Jiang, Tong Jiang, Ling Chen, Hai-Jun Mou, Bi-Guang Tuo, Guo-Qing Shi

**Specialty type:** Gastroenterology and hepatology

**Provenance and peer review:**

Unsolicited article; Externally peer reviewed.

**Peer-review model:** Single blind

**Peer-review report's scientific quality classification**

Grade A (Excellent): 0  
Grade B (Very good): B, B  
Grade C (Good): 0  
Grade D (Fair): 0  
Grade E (Poor): 0

**P-Reviewer:** Christodoulidis G, Greece; Popovic DD, Serbia

**Received:** October 3, 2023

**Peer-review started:** October 3, 2023

**First decision:** December 4, 2023

**Revised:** December 15, 2023

**Accepted:** January 11, 2024

**Article in press:** January 11, 2024

**Published online:** February 7, 2024



**Yue Deng, Tong Jiang, Ling Chen, Hai-Jun Mou, Bi-Guang Tuo, Guo-Qing Shi**, Department of Gastroenterology, Digestive Disease Hospital, The Affiliated Hospital of Zunyi Medical University, Zunyi 563000, Guizhou Province, China

**Yue Deng**, Department of Gastroenterology, Guizhou Hospital of the First Affiliated Hospital, Sun Yat-sen University, Guiyang 550000, Guizhou Province, China

**Ya Jiang**, Department of Gastroenterology, Yinjiang Autonomous County People's Hospital, Tongren 554300, Guizhou Province, China

**Corresponding author:** Guo-Qing Shi, MM, Chief Doctor, Department of Gastroenterology, Digestive Disease Hospital, The Affiliated Hospital of Zunyi Medical University, No. 149 Dalian Road, Zunyi 563000, Guizhou Province, China. [sgqing973@sina.com](mailto:sgqing973@sina.com)

## Abstract

### BACKGROUND

According to practice guidelines, endoscopic band ligation (EBL) and endoscopic tissue adhesive injection (TAI) are recommended for treating bleeding from esophagogastric varices. However, EBL and TAI are known to cause serious complications, such as hemorrhage from dislodged ligature rings caused by EBL and hemorrhage from operation-related ulcers resulting from TAI. However, the optimal therapy for mild to moderate type 1 gastric variceal hemorrhage (GOV1) has not been determined. Therefore, the aim of this study was to discover an individualized treatment for mild to moderate GOV1.

### AIM

To compare the efficacy, safety and costs of EBL and TAI for the treatment of mild and moderate GOV1.

### METHODS

A clinical analysis of the data retrieved from patients with mild or moderate GOV1 gastric varices who were treated under endoscopy was also conducted. Patients were allocated to an EBL group or an endoscopic TAI group. The differences in the incidence of varicose relief, operative time, operation success rate, mortality rate within 6 wk, rebleeding rate, 6-wk operation-related ulcer healing rate, complication rate and average operation cost were compared

between the two groups of patients.

## RESULTS

The total effective rate of the two treatments was similar, but the efficacy of EBL (66.7%) was markedly better than that of TAI (39.2%) ( $P < 0.05$ ). The operation success rate in both groups was 100%, and the 6-wk mortality rate in both groups was 0%. The average operative time (26 min) in the EBL group was significantly shorter than that in the TAI group (46 min) ( $P < 0.01$ ). The rate of delayed postoperative rebleeding in the EBL group was significantly lower than that in the TAI group (11.8% *vs* 45.1%) ( $P < 0.01$ ). At 6 wk after the operation, the healing rate of operation-related ulcers in the EBL group was 80.4%, which was significantly greater than that in the TAI group (35.3%) ( $P < 0.01$ ). The incidence of postoperative complications in the two groups was similar. The average cost and other related economic factors were greater for the EBL than for the TAI ( $P < 0.01$ ).

## CONCLUSION

For mild to moderate GOV1, patients with EBL had a greater one-time varix eradication rate, a greater 6-wk operation-related ulcer healing rate, a lower delayed rebleeding rate and a lower cost than patients with TAI.

**Key Words:** Gastric varices; Type 1 gastric variceal hemorrhage; Endoscopic band ligation; Tissue adhesive injection

©The Author(s) 2024. Published by Baishideng Publishing Group Inc. All rights reserved.

**Core Tip:** Endoscopic band ligation (EBL) and endoscopic tissue adhesive injection for the treatment of type 1 gastric variceal hemorrhage (GOV1) are often associated with various complications, which we believe are due to the lack of individualized treatment. Different treatment methods should be used for different degrees of varicose veins. Therefore, this study was based on mild to moderate GOV1 and explored individualized treatment. Ultimately, the use of EBL for mild to moderate GOV1 can achieve better outcomes and reduce both rebleeding rates and treatment costs.

**Citation:** Deng Y, Jiang Y, Jiang T, Chen L, Mou HJ, Tuo BG, Shi GQ. Evaluation of the efficacy and safety of endoscopic band ligation in the treatment of bleeding from mild to moderate gastric varices type 1. *World J Gastroenterol* 2024; 30(5): 440-449

**URL:** <https://www.wjgnet.com/1007-9327/full/v30/i5/440.htm>

**DOI:** <https://dx.doi.org/10.3748/wjg.v30.i5.440>

## INTRODUCTION

Esophageal and gastric variceal bleeding (EGVB) is a common cause of death worldwide in patients with cirrhosis, a liver-related disease, with an incidence of approximately 5%-15%. The 6-wk mortality rate can reach 20%, and rebleeding rates can reach 60%, placing an enormous burden on the global economy[1,2]. The main endoscopic treatments for EGVB include endoscopic band ligation (EBL), endoscopic tissue adhesive injection (TAI) and endoscopic injection sclerotherapy (EIS)[3]. However, during the treatment of type 1 gastric variceal hemorrhage (GOV1), EBL, EIS and TAI can cause serious complications, such as hemorrhage from dislodged ligature rings caused by EBL and hemorrhage from operation-related ulcers resulting from TAI, which are major problems for patients and endoscopists. It is important to choose the appropriate treatment modality according to the type, morphology and severity of varicose veins to further improve the treatment efficacy and minimize the incidence of associated complications. However, there are no detailed recommendations in the guidelines or published literature, especially for GOV1. Currently, there is no consensus on the recommended endoscopic treatment for GOV1. Currently, most endoscopists use a "modified sandwich method" (lauromacrogol-tissue adhesive-lauromacrogol)[4], which is highly effective but has a high incidence of rebleeding in patients with mild-to-moderate GOV1[5,6]. Therefore, we stratified the risk factors for mild-to-moderate GOV1 and observed the efficacy, safety, and costs of EBL and TAI to provide more precise and individualized treatment.

## MATERIALS AND METHODS

### Materials

Patients with mild-to-moderate GOV1 disease who visited Zunyi Medical University and Yinjiang Autonomous County People's Hospital between January 2017 and December 2022 were selected. The inclusion criteria were as follows: (1) Patients diagnosed with cirrhotic decompensation with GOV1 based on their past medical history, clinical presentation and ancillary investigations[7]; (2) Patients who underwent primary or secondary prevention measures; (3) Patients who completed the 6-wk follow-up after endoscopic gastroscopy treatment; (4) Patients with mild-to-moderate GOV1 with gastric varices in the shape of a stripe and a diameter  $\leq 10$  mm; (5) Patients with no contraindications to endoscopy; (6) Those who had not undergone surgery or transjugular intrahepatic portosystemic shunt for portal hypertension; and (7)

Patients and their families who were willing to cooperate with the treatment and signed a treatment consent form. The exclusion criteria were as follows: (1) Previous endoscopic treatment for gastric varices; (2) Lost to follow-up; (3) Severe comorbidities involving other organ systems; (4) Combined malignant tumors; and (5) Combined hepatic encephalopathies, disorders of consciousness, or other psychiatric-psychological disorders. The study protocol conformed to the ethical guidelines of the 1975 Helsinki Declaration and was approved by the Institutional Review Board.

### Data collection

Patient data, including age, sex, and disease etiology (chronic hepatitis B, chronic hepatitis C, alcoholic liver disease, autoimmune hepatitis, hepatitis B combined with alcohol consumption and others), were collected during hospitalization. The results of the radiographic examinations [diameter of gastric varices (mm) and diameter of portal vein (mm)] and Child-Pugh classification were collected at enrollment.

### Definitions

The classification of the gastric variceal size was similar to that of esophageal varices. Esophageal varices[8] were classified as mild gastric varices (G1): Rectilinear or slightly tortuous varices < 3 mm in diameter; moderate gastric varices (G2): Serpentine tortuous bulging varices 3-10 mm in diameter; and severe gastric varices (G3): Beaded, nodular or verrucous varices > 10 mm in diameter.

### Instruments

The following instruments were used: An electronic gastroscope (Olympus GIF-260), a disposable endoscopic injection needle (Poco, 25G), a multiband variceal ligator (Poco 7-ring ligature), N-butyl-2-cyanoacrylate (0.5 mL/pc; Beijing Fuaile Technology Development Co., Ltd., China), and lauromacrogol (10 mL/pc; Shaanxi Tianyu Pharmaceutical Co., Ltd., China).

### Methods of operation

Tests, including routine blood, coagulation, and biochemistry tests, as well as electrocardiogram and portal vein imaging, were completed on admission. The patient's general condition was assessed, drugs were administered to suppress gastric acid and lower the portal pressure, and painless endoscopic treatment was administered once the patient's vital signs had stabilized. All the procedures were performed by our team of doctors experienced in EGVB treatment.

In the EBL group, the lateral vein of the lesser curvature was ligated from the cardia toward the fundus of the stomach *via* a ligature *via* reverse endoscopy. TAI group: TAI treatment was performed using a "modified sandwich method" (lauromacrogol-tissue adhesive-lauromacrogol).

Both groups were treated for esophageal varices after the completion of GV treatment. The patients in both groups received proton pump inhibitors and vasoconstrictors. The TAI group received prophylactic antibiotics. The patients in both groups were followed up for at 6 wk after gastroscopy to judge the effectiveness of the varices eradication and to assess whether continuation of treatment was necessary. Patients in both groups were followed up at 3 months, 6 months and 1 year postoperatively at regular intervals. Depending on the effect of varices, the choice was made whether to repeat endoscopic treatment.

### Efficacy evaluation

GOV1 efficacy is divided into three levels[9,10]: (1) Ineffective: No improvement in the varicose veins; (2) Effective: The condition of the varicose veins improved, indicated by less than 50% shrinkage; and (3) Markedly effective: The massed or nodular veins had changed to cords, had shrunk by more than 50% or had disappeared completely. Total effective rate = (number of effective cases + number of effective cases)/total number of cases × 100%.

### Safety evaluation

Operation success was defined as the completion of EBL or TAI without uncontrollable bleeding intraoperatively or resulting in patient death. Operative time: The time from the start of the operation to the end of the operation, including the common time for treatment of gastric varices and esophageal varices. Six-week mortality[11]: Death within 6 wk after surgery.

Rebleeding: The reappearance of signs of upper gastrointestinal bleeding, such as vomiting blood, black stools, decreasing hemoglobin levels and shock, that recurs after the first bleeding has been controlled, with early rebleeding characterized as active bleeding within 6 wk after the bleeding had been controlled and late rebleeding characterized as active bleeding 6 wk after the bleeding had been controlled.

Six-week operation-related ulcer healing rate: Follow-up gastroscopy was performed 6 wk after surgery to observe the healing of the ulcer after EBL or TAI. The ulcer was considered healed if a fibrous scar was formed; otherwise, it was not healed. Adverse events included abdominal pain, infection, ectopic embolism, and perforation.

### Economic evaluation

The following were summarized: The average number of hospitalizations, average length of hospitalizations, average total cost of hospitalization, average number of operations and average operation cost.

### Statistics

Microsoft Excel 2016 and SPSS 26.0 were used for statistical analysis in this study. Normally distributed data are

expressed as the mean  $\pm$  SD, quantitative data with a skewed distribution are described by the median, and count data are expressed as the rate. A *t*-test was used to compare differences between the groups; nonnormally distributed measures and rank data were compared using the Mann-Whitney *U* test or Wilcoxon rank sum test, and count data were compared using the  $\chi^2$  test and Fisher's test. The test level was  $P < 0.05$ .

## RESULTS

### Propensity score matching

According to the inclusion and exclusion criteria, a total of 151 patients were included, including 57 patients in the EBL group and 94 patients in the TAI group. The control variables used were sex, age, etiology, Child-Pugh classification, gastric variceal diameter, and portal vein diameter, and propensity score matching was performed using SPSS software. Then, 51 pairs of 102 patients were matched to the EBL group and the TAI group. The sex, age, etiology, Child-Pugh classification, gastric variceal diameter, and portal vein diameter of the two groups of patients were compared after matching. The differences between the two groups were not statistically significant ( $P > 0.05$ ) (Table 1).

### Efficacy

Gastroscopy was performed again 6 wk after the operation to observe if there was relief of the gastric varices after endoscopic treatment in the two groups. The difference in the total effective rate between the EBL group (96.1%) and the TAI group (94.1%) was not statistically significant ( $P > 0.05$ ). However, the percentage of patients in the EBL group (66.7%) was significantly greater than that in the TAI group (39.2%) ( $\chi^2 = 7.713$ ,  $P < 0.05$ ) (Table 2).

### Safety

**Comparison of the operative time, operation success rate and 6-wk mortality:** Both groups of patients successfully completed endoscopic treatment, and there was no intraoperative bleeding that was difficult to control or that led to patient death. The operation success rate of the two groups was 100%. Additionally, there were no deaths for any reason in the two groups of patients 6 wk after the operation. The average operative time in the EBL group (26 min) was significantly shorter than that in the TAI group (46 min) ( $P < 0.01$ ) (Table 3).

**Comparison of the 6-wk operation-related ulcer healing rate:** After surgery, gastroscopy revealed that the healing rate of the ulcers that developed after dislodgement of the ligature ring in the EBL group reached 80.4%, which was significantly greater than the healing rate of the glue-draining ulcers in the TAI group (35.3%). The difference between the two groups was statistically significant ( $P < 0.01$ ) (Table 4). Many TAI patients presented with glue-draining ulcers and bleeding (Figure 1); however, most EBL patients had healed ulcers (Figure 2).

**Comparison of the postoperative rebleeding rates:** Patients in both groups were followed up for 1 year after successful endoscopic treatment to focus on rebleeding. The rate of early postoperative rebleeding (within 6 wk after surgery) was slightly lower in the EBL group (7.8%) than in the TAI group (13.7%), but the difference was not statistically significant ( $P > 0.05$ ). The rate of late postoperative rebleeding (from 6 wk postoperatively to 1 year) was significantly lower in the EBL group (11.8%) than in the TAI group (45.1%) ( $P < 0.01$ ) (Table 5).

**Comparison of adverse events:** The rates of postoperative abdominal pain and infection were similar between the two groups, but the difference was not statistically significant ( $P > 0.05$ ). No heterotopic embolism or perforation occurred in either group (Table 6).

### Economic analysis

Follow-up economic indices such as the number of hospitalizations, the total number of days of hospitalization, the total cost of hospitalization, the number of surgeries, the cost of surgical materials and other economic indicators were significantly lower in the two groups one year after the operation in the EBL group than in the TAI group ( $P < 0.01$ ) (Table 7).

## DISCUSSION

In liver cirrhosis, increased intrahepatic vascular resistance to portal flow increases the portal pressure and leads to portal hypertension. Once portal hypertension develops, it influences extrahepatic vascular beds in the splanchnic and systemic circulations, causing collateral vessel formation and arterial vasodilation. This process helps to increase blood flow into the portal vein, which exacerbates portal hypertension and eventually aids in the development of hyperdynamic circulatory syndrome. As a result, esophageal varices or ascites develop. Gastric varices are present in 5%-33% of patients with portal hypertension. Gastric varices usually bleed more severely than ruptured esophageal varices, and the mortality rate can reach 45%[1].

Based on Sarin's classification, gastric varices can be classified as GOV1, GOV2, isolated gastric varices type 1 (IGV1) or IGV2. GOV1 is the most common type of gastric varices, accounting for 75%[12] of all gastric varices. GOV2 and IGV1 tend to have varices that have thicker diameters and are continuously exposed to gastric acid and pepsin; thus, TAI is recognized as the treatment of choice, as it has high success rates in hemostasis and one-time varicose vein eradication

**Table 1 Comparison of the baseline data between the two groups of patients**

	EBL group (n = 50)	TAI group (n = 50)	$\chi^2/t/U$	P value
Sex, n (%)				
Male	45 (88.2)	43 (84.3)	/	0.487 <sup>1</sup>
Female	6 (11.8)	8 (15.7)		
Age (yr, mean $\pm$ SD)	52.78 $\pm$ 8.50	52.92 $\pm$ 9.65	0.076	0.939 <sup>2</sup>
Causes of disease, n (%)			3.744	0.630 <sup>1</sup>
Hepatitis B liver cirrhosis	28 (54.9)	26 (51.0)		
alcoholic cirrhosis	11 (21.6)	13 (25.5)		
Hepatitis C cirrhosis	6 (11.7)	2 (3.9)		
Autoimmune liver cirrhosis	1 (2.0)	3 (5.9)		
Hepatitis B liver cirrhosis with alcoholic cirrhosis	4 (7.8)	6 (11.7)		
Other cause	1 (2.0)	1 (2.0)		
Child-Pugh classification, n (%)			-0.377	0.706 <sup>3</sup>
A	11 (21.6)	10 (19.6)		
B	37 (72.6)	37 (72.6)		
C	3 (5.8)	4 (7.8)		
Diameter of gastric varices (mm)	15.0	14.0	-1.459	0.135 <sup>3</sup>
Diameter of the portal vein (mm)	8.0	9.0	-1.280	0.200 <sup>3</sup>

<sup>1</sup>Fisher's test.<sup>2</sup>t test.<sup>3</sup>Mann-Whitney U test.The values are expressed as the mean  $\pm$  SD or median. EBL: Endoscopic band ligation; TAI: Tissue adhesive injection.**Table 2 Comparison of treatment efficacy between the two groups of patients, n (%)**

	Markedly effective	Effective	Ineffective	Total effective rate
EBL group	34 (66.7)	15 (29.4)	2 (3.9)	49 (96.1)
TAI group	20 (39.2)	28 (54.9)	3 (5.9)	48 (94.1)
$\chi^2$	-2.669			
P value	0.008 <sup>1</sup>			> 0.999 <sup>2</sup>

<sup>1</sup>Wilcoxon rank sum test.<sup>2</sup>Fisher's test.

EBL: Endoscopic band ligation; TAI: Tissue adhesive injection.

[13]. GOV1 is characterized by the presence of gastric varices that appear with esophageal varices and extend 2-5 cm below the gastroesophageal junction. The shape of these lesions is similar to that of esophageal varices, and they may appear tortuous, nodular or tumorous in shape. There is no uniform standard for the endoscopic treatment of GOV1. Currently, most endoscopists choose endoscopic TAI, while a few endoscopists use EBL. Recently, a few studies had analyzed and compared the clinical application of EBL and TAI for removing GOV1, but the conclusions have not been consistent. Several studies have shown that there is no statistically significant difference between EBL and TAI in the treatment of GOV1 in terms of acute hemostasis, variceal elimination or risk of rebleeding, but the complication rate of EBL is lower[14]. Several studies have shown that EBL is superior to TAI in terms of reducing the incidence of late rebleeding in patients with acute GOV1[15]. It has also been suggested that TAI is more favorable than EBL because of its significantly reduced rebleeding rate, significantly increased survival time, high hemostasis and survival rate[16-19]. We believe that the inconsistency of the results of the current study compared to other studies may be related to the fact that none of the other studies stratified the risks of the procedures for the study population, and none of them analyzed indicators such as diameter, morphology, or severity of gastric varices. Moreover, all of their studies involved emergency bleeding rather than primary or secondary bleeding prevention. Therefore, these studies failed to individualize the choice

**Table 3 Comparison of operative time, operative success rate and 6-wk mortality**

	Operative time (min)	Operative success rate, <i>n</i> (%)	Week mortality, <i>n</i> (%)
EBL group	26	51 (100)	0 (0)
TAI group	46	51 (100)	0 (0)
<i>Z</i>	-8.721	/	/
<i>P</i> value	< 0.001 <sup>1</sup>	/	/

<sup>1</sup>Mann-Whitney *U* test.

The operative times are expressed as medians. EBL: Endoscopic band ligation; TAI: Tissue adhesive injection.

**Table 4 Comparison of the 6-wk operation-related ulcer healing rate, *n* (%)**

	Healed	Non-healed
EBL group	41 (80.4)	10 (19.6)
TAI group	18 (35.3)	33 (64.7)
$\chi^2$	21.268	
<i>P</i> value	< 0.001	

EBL: Endoscopic band ligation; TAI: Tissue adhesive injection.

**Table 5 Comparison of rebleeding rates, *n* (%)**

	Early rebleeding rate	Delayed rebleeding rate
EBL group	4 (7.8)	6 (11.8)
TAI group	7 (13.7)	23 (45.1)
$\chi^2$	0.917	13.924
<i>P</i> value	0.338	< 0.001

EBL: Endoscopic band ligation; TAI: Tissue adhesive injection.

**Table 6 Comparison of adverse events, *n* (%)**

	Abdominal pain	Infection	Ectopic embolism	Perforation
EBL group	11 (21.6)	2 (3.9)	0 (0)	0 (0)
TAI group	10 (19.6)	3 (5.9)	0 (0)	0 (0)
$\chi^2$	0.060	/	/	/
<i>P</i> value	0.807 <sup>1</sup>	> 0.999 <sup>2</sup>	/	/

<sup>1</sup> $\chi^2$  test.<sup>2</sup>Fisher's test.

EBL: Endoscopic band ligation; TAI: Tissue adhesive injection.

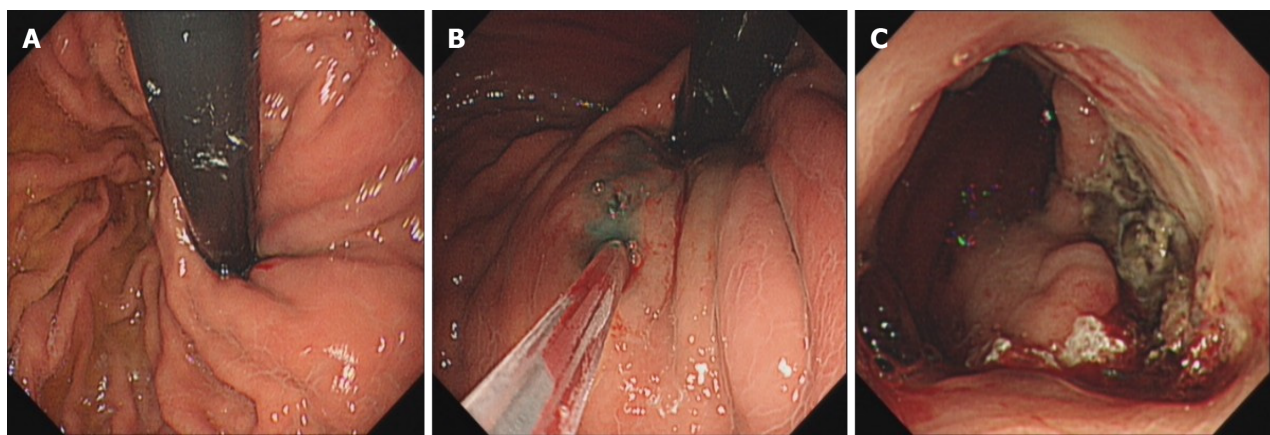
of regimen, which led to different results.

Therefore, we stratified the risk of GOV1 and developed different treatment programs. For high-tension, nodular or tumorous varicose veins with a diameter greater than 1 cm (severe), precise puncture and precise endoscopic injection are feasible; therefore, TAI can achieve very good outcomes. For this kind of varicose vein, if EBL is chosen, incomplete ligation and insufficient vessel occlusion are likely to occur. In contrast, the risk of rebleeding is high[20]. Therefore, it is appropriate to choose the TAI for GOV1. However, for striated varicose veins (mild to moderate) with a diameter less than 1 cm, precise puncture and precise endoscopic injection are difficult because of the low vascular tone. Therefore, rebleeding is characterized by bleeding from a draining ulcer that can develop as a result of TAI[21,22]. On the basis of



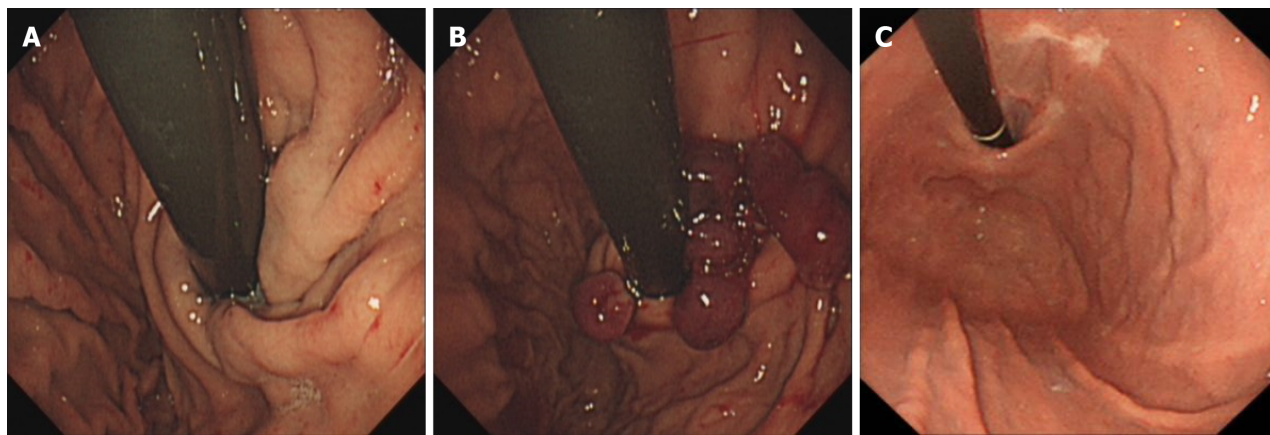
Table 7 Comparison of the economic evaluation (median) results					
	Average number of hospitalizations (No.)	Average length of hospitalizations (d)	Average total cost of hospitalization (Yuan)	Average number of operations (No.)	Average operation cost (Yuan)
EBL group	2.00	13.00	32128.60	2.00	1680.00
TAI group	3.00	19.00	69380.75	3.00	6548.80
Z	3.596	3.894	6.134	3.631	8.855
P value	< 0.001	< 0.001	< 0.001	< 0.001	< 0.001

EBL: Endoscopic band ligation; TAI: Tissue adhesive injection.



DOI: 10.3748/wjg.v30.i5.440 Copyright ©The Author(s) 2024.

**Figure 1** Endoscopic images of endoscopic tissue adhesive injection for mild to moderate gastric varices type 1. A: Pre-treatment. It showed type 1 gastric variceal hemorrhage; B: In treatment. It was performed using a “modified sandwich method” (lauromacrogol - tissue adhesive - lauromacrogol); C: After 6 wk of treatment. It showed giant glue-draining ulcer after endoscopy.



DOI: 10.3748/wjg.v30.i5.440 Copyright ©The Author(s) 2024.

**Figure 2** Endoscopic images of endoscopic band ligation for mild to moderate gastric varices type 1. A: Pre-treatment. It showed type 1 gastric variceal hemorrhage; B: In treatment. The lateral vein of the lesser curvature was ligated from the cardia toward the fundus of the stomach with a ligature through a reverse endoscope; C: After 6 wk of treatment. The ulcer was healed and a fibrous scar was formed.

our clinical findings, EBLs prevent bleeding from glue-draining ulcers. Therefore, our retrospective study compared endoscopic reverse body ligation and TAI for the treatment of mild to moderate GOV1. Our study included patients who were subjected to secondary or primary prophylaxis and did not include only emergency patients.

EBL is a procedure in which the gastroscope enters the fundus of the stomach and then reverses the body to fully expose the fundus, and a ligature ring is used to ligate the varicose vein inside the clear cap at the front of the inhalation

endoscope so that tissue necrosis occurs at the site of the ligature and a thrombus forms to block the varicose vein within 24 to 48 h. The ligature ring eventually detaches and leaves an ulcer, which heals and leaves a fibrous scar, creating a lasting interruption of the blood flow in the vein[23].

Therefore, this study compared the efficacy, safety and cost of endoscopic reverse body ligation and TAI for the treatment of mild and moderate GOV1 gastric varices: (1) Efficacy: The total effective rates of EBL and TAI were similar, but the effective rate of EBL was better than that of TAI. These findings suggest that both EBL and TAI have similar overall efficacy rates, but EBL has a greater rate of effective one-time varicose vein eradication than does TAI. Because of the small diameter of the gastric varices selected for this study and the choice of intensive multiple ring ligation during treatment, the varices could be fully occluded at one time, and the risk of recurrence of residual varices could be reduced; (2) Safety: The data of this study showed that the patients in both the EBL group and the TAI group successfully completed the endoscopic surgery, and none of them had uncontrollable intraoperative bleeding or died. Both EBL and TAI are feasible, safe and effective for the treatment of mild to moderate GOV1. However, the average operative time of EBL was significantly shorter than that of TAI. This finding indicates that performing EBL is easier for endoscopists. EBL can fully expose the gastric fundus to expand the surgical window more openly and clearly locate the varicose vein, which is favorable for surgical operation. Complete ligation under direct vision can be achieved due to the clear visibility of the surgical field, ensuring a safe operation. The early postoperative rebleeding rate in the EBL group was slightly lower than that in the TAI group. The rate of late rebleeding in the postoperative period after surgery for EBL was significantly lower than that in the postoperative period after TAI. A 6-wk postoperative review of patients treated with gastroscopy showed that the healing rate of ulcers after dislodged ligature rings in the EBL group was significantly greater than the glue-draining ulcers in the TAI group. This is because shallow ulcers tend to form after detachment of the ligature ring, and most of the ulcers heal into a fibrous scar within 6 wk. However, after injection of the tissue adhesive, due to poor precision, the tissue glue tends to leak into the submucosa, which results in the formation of a long-lasting and deep glue-discharging ulcer that tends to remain unhealed and bleeds repeatedly even after 6 wk. This is the reason why the rate of delayed rebleeding after surgery was significantly lower in the EBL group than in the TAI group. The rate of postoperative complications was similar between the two groups, which shows that there is no increased risk of treatment with EBL; and (3) Cost: The number of hospitalizations, total number of days of hospitalization, total cost of hospitalization, number of surgeries, and cost of surgical materials in the EBL group were lower than those in the TAI group. The cost of consumables used in the EBL group was lower than that used in the TAI group because the EBL group had higher rates of effective one-time varicose vein eradication and procedure-related ulcer healing at 6 wk postoperatively but a lower rebleeding rate. Therefore, this approach has a significantly lower health care cost and a considerably lighter financial burden on the patient's family and the country.

## CONCLUSION

In conclusion, for mild to moderate GOV1, endoscopic reverse body ligation is safer, more effective, more economical and easier to perform than TAI, thus confirming that this approach is beneficial for patients and is worthy of clinical application. EBL is a better treatment for gastric varices in patients with mild or moderate GOV1.

## ARTICLE HIGHLIGHTS

### Research background

During the treatment of type 1 gastric variceal hemorrhage (GOV1), endoscopic band ligation (EBL), endoscopic tissue adhesive injection (TAI) and endoscopic injection sclerotherapy can cause serious complications. Therefore, individualized treatment is urgently needed.

### Research motivation

The optimal individualized therapy for patients with mild or moderate GOV1 has yet to be identified. It is important to choose the appropriate treatment modality according to the type, morphology and severity of varicose veins to further improve the treatment efficacy and minimize the incidence of associated complications. Thus, this new treatment will greatly reduce patient suffering.

### Research objectives

We focused on comparing the differences between the EBL and TAI treatments. This study provides new ideas for the treatment of mild and moderate GOV1.

### Research methods

This retrospective study compared the efficacy, safety and costs of EBL and TAI. A detailed comparison of the varicose-relief rate, operative time, operation success rate, mortality rate within 6 wk, rebleeding rate, 6-wk operation-related ulcer healing rate, complication rate and average operation cost was performed.



### Research results

EBL has a higher one-time varix eradication rate, a higher 6-wk operation-related ulcer healing rate, a lower delayed rebleeding rate and a lower cost than TAI for mild to moderate GOV1.

### Research conclusions

This study provides a new method for the treatment of mild to moderate GOV1:EBL.

### Research perspectives

EBL has a higher one-time varix eradication rate, higher 6-wk operation-related ulcer healing rate, lower delayed rebleeding rate and lower cost than TAI for mild to moderate GOV1.

---

## ACKNOWLEDGEMENTS

Our research team will expand the sample size and study the treatment of different levels of gastric varices in the future.

---

## FOOTNOTES

**Co-first authors:** Yue Deng and Ya Jiang.

**Author contributions:** Deng Y and Jiang Y designed the research study and wrote the paper; Jiang Y, Mou HJ, and Shi GQ contributed to the surgical operations and provided clinical advice; Tuo BG supervised the study; Jiang T and Chen L contributed to the analysis and interpretation of the data; Shi GQ approved the final version of the article to be published.

**Supported by** the Guizhou Provincial Science and Technology Program, No. [2020]4Y004.

**Institutional review board statement:** This study was reviewed and approved by the Ethics Committee of the Affiliated Hospital of Zunyi Medical University.

**Informed consent statement:** Patients were not required to give informed consent to participate in the study because the analysis used anonymous clinical data that were obtained after each patient agreed to the treatment by written consent.

**Conflict-of-interest statement:** All the authors report no relevant conflicts of interest for this article.

**Data sharing statement:** No additional data are available.

**Open-Access:** This article is an open-access article that was selected by an in-house editor and fully peer-reviewed by external reviewers. It is distributed in accordance with the Creative Commons Attribution NonCommercial (CC BY-NC 4.0) license, which permits others to distribute, remix, adapt, build upon this work non-commercially, and license their derivative works on different terms, provided the original work is properly cited and the use is non-commercial. See: <https://creativecommons.org/licenses/by-nc/4.0/>

**Country/Territory of origin:** China

**ORCID number:** Yue Deng 0000-0003-3896-1491; Bi-Guang Tuo 0000-0003-3147-3487; Guo-Qing Shi 0000-0003-3597-8255.

**S-Editor:** Wang JJ

**L-Editor:** A

**P-Editor:** Zhao S

---

## REFERENCES

- 1 Kim DH, Cho E, Jun CH, Son DJ, Lee MJ, Park CH, Cho SB, Park SY, Kim HS, Choi SK, Rew JS. Risk Factors and On-site Rescue Treatments for Endoscopic Variceal Ligation Failure. *Korean J Gastroenterol* 2018; **72**: 188-196 [PMID: 30419643 DOI: 10.4166/kjg.2018.72.4.188]
- 2 Ginès P, Krag A, Abraldes JG, Solà E, Fabrellas N, Kamath PS. Liver cirrhosis. *Lancet* 2021; **398**: 1359-1376 [PMID: 34543610 DOI: 10.1016/S0140-6736(21)01374-X]
- 3 Gralnek IM, Camus Duboc M, Garcia-Pagan JC, Fuccio L, Karstensen JG, Hucl T, Jovanovic I, Awadie H, Hernandez-Gea V, Tantau M, Ebigbo A, Ibrahim M, Vlachogiannakos J, Burgmans MC, Rosasco R, Triantafyllou K. Endoscopic diagnosis and management of esophagogastric variceal hemorrhage: European Society of Gastrointestinal Endoscopy (ESGE) Guideline. *Endoscopy* 2022; **54**: 1094-1120 [PMID: 36174643 DOI: 10.1055/a-1939-4887]
- 4 Zeng XQ, Ma LL, Tseng YJ, Chen J, Cui CX, Luo TC, Wang J, Chen SY. Endoscopic cyanoacrylate injection with or without lauromacrogol for gastric varices: A randomized pilot study. *J Gastroenterol Hepatol* 2017; **32**: 631-638 [PMID: 27439114 DOI: 10.1111/jgh.13496]
- 5 Nakayama S, Murashima N. Extrusion of Glue Cast after Sclerotherapy. *Intern Med* 2015; **54**: 2781 [PMID: 26521912 DOI: 10.2169/internalmedicine.54.5599]

- 6 **Cheng LF**, Wang ZQ, Li CZ, Lin W, Yeo AE, Jin B. Low incidence of complications from endoscopic gastric variceal obturation with butyl cyanoacrylate. *Clin Gastroenterol Hepatol* 2010; **8**: 760-766 [PMID: [20621678](#) DOI: [10.1016/j.cgh.2010.05.019](#)]
- 7 **Smith A**, Baumgartner K, Bositis C. Cirrhosis: Diagnosis and Management. *Am Fam Physician* 2019; **100**: 759-770 [PMID: [31845776](#)]
- 8 **Beppu K**, Inokuchi K, Koyanagi N, Nakayama S, Sakata H, Kitano S, Kobayashi M. Prediction of variceal hemorrhage by esophageal endoscopy. *Gastrointest Endosc* 1981; **27**: 213-218 [PMID: [6975734](#) DOI: [10.1016/s0016-5107\(81\)73224-3](#)]
- 9 **Tripathi D**, Stanley AJ, Hayes PC, Patch D, Millson C, Mehrzad H, Austin A, Ferguson JW, Olliff SP, Hudson M, Christie JM; Clinical Services and Standards Committee of the British Society of Gastroenterology. U.K. guidelines on the management of variceal haemorrhage in cirrhotic patients. *Gut* 2015; **64**: 1680-1704 [PMID: [25887380](#) DOI: [10.1136/gutjnl-2015-309262](#)]
- 10 **Wani ZA**, Bhat RA, Bhadoria AS, Maiwall R, Choudhury A. Gastric varices: Classification, endoscopic and ultrasonographic management. *J Res Med Sci* 2015; **20**: 1200-1207 [PMID: [26958057](#) DOI: [10.4103/1735-1995.172990](#)]
- 11 **Garcia-Tsao G**, Abraldes JG, Berzigotti A, Bosch J. Portal hypertensive bleeding in cirrhosis: Risk stratification, diagnosis, and management: 2016 practice guidance by the American Association for the study of liver diseases. *Hepatology* 2017; **65**: 310-335 [PMID: [27786365](#) DOI: [10.1002/hep.28906](#)]
- 12 **Sarin SK**, Kumar A. Gastric varices: profile, classification, and management. *Am J Gastroenterol* 1989; **84**: 1244-1249 [PMID: [2679046](#)]
- 13 **Jakab SS**, Garcia-Tsao G. Screening and Surveillance of Varices in Patients With Cirrhosis. *Clin Gastroenterol Hepatol* 2019; **17**: 26-29 [PMID: [29551741](#) DOI: [10.1016/j.cgh.2018.03.012](#)]
- 14 **Chang DF**, Mei ZC, He S, Guo JJ, Deng L. [Clinical efficacy of endoscopic gastric variceal ligation vs. gastric variceal obliteration in treating type 1 gastroesophageal varices bleeding]. *J Chongqing Medical University* 2021; **46**: 252-256 [DOI: [10.13406/j.cnki.cyx.002716](#)]
- 15 **Hong HJ**, Jun CH, Lee du H, Cho EA, Park SY, Cho SB, Park CH, Joo YE, Kim H, Choi SK, Rew JS. Comparison of Endoscopic Variceal Ligation and Endoscopic Variceal Obliteration in Patients with GOV1 Bleeding. *Chonnam Med J* 2013; **49**: 14-19 [PMID: [23678472](#) DOI: [10.4068/cmj.2013.49.1.14](#)]
- 16 **Park SJ**, Kim YK, Seo YS, Park SW, Lee HA, Kim TH, Suh SJ, Jung YK, Kim JH, An H, Yim HJ, Jang JY, Yeon JE, Byun KS. Cyanoacrylate injection versus band ligation for bleeding from cardiac varices along the lesser curvature of the stomach. *Clin Mol Hepatol* 2016; **22**: 487-494 [PMID: [28081588](#) DOI: [10.3350/cmh.2016.0050](#)]
- 17 **Tan PC**, Hou MC, Lin HC, Liu TT, Lee FY, Chang FY, Lee SD. A randomized trial of endoscopic treatment of acute gastric variceal hemorrhage: N-butyl-2-cyanoacrylate injection versus band ligation. *Hepatology* 2006; **43**: 690-697 [PMID: [16557539](#) DOI: [10.1002/hep.21145](#)]
- 18 **Lo GH**, Lin CW, Perng DS, Chang CY, Lee CT, Hsu CY, Wang HM, Lin HC. A retrospective comparative study of histoacryl injection and banding ligation in the treatment of acute type 1 gastric variceal hemorrhage. *Scand J Gastroenterol* 2013; **48**: 1198-1204 [PMID: [24047398](#) DOI: [10.3109/00365521.2013.832792](#)]
- 19 **Qiao W**, Ren Y, Bai Y, Liu S, Zhang Q, Zhi F. Cyanoacrylate Injection Versus Band Ligation in the Endoscopic Management of Acute Gastric Variceal Bleeding: Meta-Analysis of Randomized, Controlled Studies Based on the PRISMA Statement. *Medicine (Baltimore)* 2015; **94**: e1725 [PMID: [26469912](#) DOI: [10.1097/MD.0000000000001725](#)]
- 20 **Garcia-Pagán JC**, Barrufet M, Cardenas A, Escorsell A. Management of gastric varices. *Clin Gastroenterol Hepatol* 2014; **12**: 919-28.e1; quiz e51 [PMID: [23899955](#) DOI: [10.1016/j.cgh.2013.07.015](#)]
- 21 **Hu Z**, Zhang D, Swai J, Liu T, Liu S. Risk of rebleeding from gastroesophageal varices after initial treatment with cyanoacrylate: a systematic review and pooled analysis. *BMC Gastroenterol* 2020; **20**: 181 [PMID: [32517718](#) DOI: [10.1186/s12876-020-01333-9](#)]
- 22 **Nakazawa M**, Imai Y, Sugawara K, Uchida Y, Saitoh Y, Fujii Y, Uchiya H, Ando S, Nakayama N, Tomiya T, Mochida S. Long-term outcomes of patients with cirrhosis presenting with bleeding gastric varices. *PLoS One* 2022; **17**: e0264359 [PMID: [35290384](#) DOI: [10.1371/journal.pone.0264359](#)]
- 23 **Nelms DW**, Pelaez CA. The Acute Upper Gastrointestinal Bleed. *Surg Clin North Am* 2018; **98**: 1047-1057 [PMID: [30243446](#) DOI: [10.1016/j.suc.2018.05.004](#)]



Published by **Baishideng Publishing Group Inc**  
7041 Koll Center Parkway, Suite 160, Pleasanton, CA 94566, USA

**Telephone:** +1-925-3991568

**E-mail:** [office@baishideng.com](mailto:office@baishideng.com)

**Help Desk:** <https://www.f6publishing.com/helpdesk>

<https://www.wjgnet.com>

