



Exploring non-curative endoscopic submucosal dissection: Current treatment optimization and future indication expansion

Yi-Nong Zhu, Xiang-Lei Yuan, Wei Liu, Yu-Hang Zhang, Yi Mou, Bing Hu, Lian-Song Ye

Specialty type: Gastroenterology and hepatology

Provenance and peer review:

Unsolicited article; Externally peer reviewed.

Peer-review model: Single blind

Peer-review report's scientific quality classification

Grade A (Excellent): 0
Grade B (Very good): B
Grade C (Good): 0
Grade D (Fair): 0
Grade E (Poor): 0

P-Reviewer: Rodrigo L, Spain

Received: December 18, 2023

Peer-review started: December 18, 2023

First decision: January 15, 2024

Revised: January 17, 2024

Accepted: February 18, 2024

Article in press: February 18, 2024

Published online: March 7, 2024



Yi-Nong Zhu, Xiang-Lei Yuan, Wei Liu, Yu-Hang Zhang, Yi Mou, Bing Hu, Lian-Song Ye, Department of Gastroenterology and Hepatology, West China Hospital, Sichuan University, Chengdu 610041, Sichuan Province, China

Corresponding author: Lian-Song Ye, MD, Doctor, Department of Gastroenterology and Hepatology, West China Hospital, Sichuan University, No. 37 of Guoxue Alley, Chengdu 610041, Sichuan Province, China. yeliangsongnj@wchscu.edu.cn

Abstract

The increasing popularity of endoscopic submucosal dissection (ESD) as a treatment for early gastric cancer has highlighted the importance of quality assessment in achieving curative resections. This article emphasizes the significance of evaluating ESD quality, not only for curative cases but also for non-curative ones. Postoperative assessment relies on the endoscopic curability (eCura) classification, but management strategies for eCuraC-1 tumour with a positive horizontal margin are unclear. Current research primarily focuses on comparing additional surgical procedures in high-risk patients, while studies specifically targeting eCuraC-1 patients are limited. Exploring management strategies and follow-up outcomes for such cases could provide valuable insights. Furthermore, the application of molecular imaging using near-infrared fluorescent tracers holds promise for precise tumour diagnosis and navigation, potentially impacting the management of early-stage gastric cancer patients. Advancing research in these areas is essential for improving the overall efficacy of endoscopic techniques and refining treatment indications.

Key Words: Early gastric cancer; Endoscopic submucosal dissection; Quality control; Non-curative endoscopic submucosal dissection; Near-infrared fluorescent tracer

©The Author(s) 2024. Published by Baishideng Publishing Group Inc. All rights reserved.

Core Tip: The quality control of endoscopic submucosal dissection (ESD) has gained increasing attention, and concurrently, the management of patients with non-curative ESD outcomes is equally crucial. Existing guidelines offer unclear recommendations for the management of patients classified as endoscopic curability C-1 after the procedure, warranting the need for further clinical research to refine treatment strategies for this patient population.

Citation: Zhu YN, Yuan XL, Liu W, Zhang YH, Mou Y, Hu B, Ye LS. Exploring non-curative endoscopic submucosal dissection: Current treatment optimization and future indication expansion. *World J Gastroenterol* 2024; 30(9): 1257-1260

URL: <https://www.wjgnet.com/1007-9327/full/v30/i9/1257.htm>

DOI: <https://dx.doi.org/10.3748/wjg.v30.i9.1257>

TO THE EDITOR

A recent publication by Kim *et al*[1] highlighted the importance of quality assessment in endoscopic submucosal dissection (ESD) for the treatment of early gastric cancer (EGC). With the widespread utilization of endoscopy, endoscopic treatment, specifically ESD, has become increasingly favoured for the management of EGC, especially when the risk of lymph node metastasis is deemed negligible. Acknowledging this prevailing trend, the authors emphasize that with the increasing popularity of endoscopic therapies, the number of physicians performing ESD has been on the rise each year. Consequently, there has been a corresponding increase in the rate of non-curative resections.

Compared to patients undergoing open surgery, patients undergoing ESD undoubtedly experience less surgical trauma and improved quality of life[2]. Considering the epidemiology of gastric cancer, conducting research to enhance the quality of ESD is imperative, and an increasing number of clinical studies are currently focusing on assessing ESD quality. However, it is essential to note that curative ESD is not the sole focal point; the discourse on non-curative ESD is equally significant.

Many studies have focused on the preoperative evaluation of patients. When assessing the risk of non-curative ESD, the size of the tumour and the depth of infiltration are the two most crucial indicators[3] since pathology can be acquired directly through biopsy. However, due to the challenges in evaluating the extent of gastric cancer, especially in assessing infiltration depth, even though endoscopic ultrasound techniques are advanced and several studies have explored predictive models for risk resection[4], difficulties still persist. In regard to postoperative assessment, the commonly utilized classification in Asia for determining the completeness of ESD is the endoscopic curability (eCura) from the Japan Gastroenterological Endoscopy Society, which involves depth of invasion, ulceration, and pathology[5]. In accordance with guidelines[6], the management strategies for eCuraA, eCuraB, and eCuraC-2 are clear and well defined. However, regarding eCuraC-1 tumours, where segmental resection or a positive horizontal margin (HM) serve as the sole noncurative factor, the appropriate approach remains ambiguous. Surgical intervention is not the exclusive choice, and alternative options include repeat ESD, surgery, close observation, and endoscopic coagulation (Figure 1).

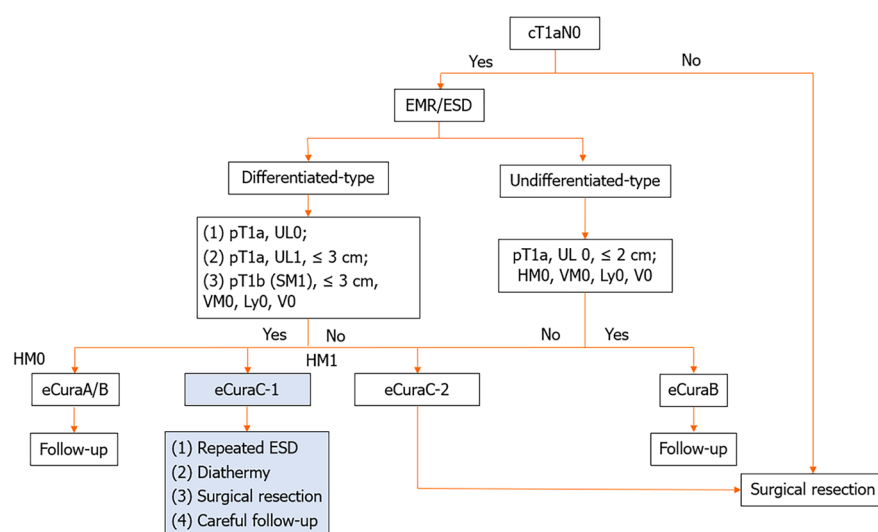


Figure 1 Diagram of the treatment procedure for early gastric cancer. pT1a (M): Intramucosal cancer (histopathological diagnosis); pT1b (SM): Submucosally invasive cancer (histopathological diagnosis). UL: Finding of ulceration (or ulcer scar); UL0: Absence of ulceration or ulcer scar; UL1: Presence of ulceration or ulcer scar. HM: Horizontal margin; HM0: Negative horizontal margin; HM1: Positive horizontal margin. VM: Vertical margin; VM0: Negative vertical margin; VM1: Positive vertical margin. EMR: Endoscopic mucosal resection; ESD: Endoscopic submucosal dissection; eCura: Endoscopic curability.

Current clinical research on noncurative patients predominantly focuses on directly comparing the efficacy of additional surgical procedures in high-risk patients[7]. Several studies have explored the effectiveness of conservative treatments in elderly patients[8], however, none of these studies categorized outcomes based on postoperative pathology of HM. Globally, large-scale clinical studies specifically targeting eCuraC-1 patients are scarce. The management strategies and corresponding follow-up outcomes for eCuraC-1 patients may represent valuable avenues for future research. We believe that the progressive conduct of such studies plays a crucial role in delineating both the absolute and relative indications for endoscopic treatment and contributes significantly to the overall advancement of endoscopic techniques.

In addition, with the advancement of molecular diagnostic technologies, “molecular imaging” has emerged as a new frontier in tumour diagnosis. Near-infrared fluorescent tracers have been employed for tumour navigation in breast cancer, offering real-time and precise information about the tumour for medical professionals[9]. This technology has been successfully deployed in the field of gastrointestinal cancer, specifically in colorectal tumours, through the utilization of fluorescein-conjugated carcinoembryonic antigen targeted imaging[10]. If such precision medicine approaches can be designed to identify gastric cancer, effectively label primary and metastatic lesions, and be applied in the management of early-stage cancer patients, their potential impact is also promising.

FOOTNOTES

Author contributions: Zhu YN and Yuan XL designed the article; Liu W write the manuscript; Zhang YH and Mou Y searched the literature; Hu B and Ye LS revised the manuscript.

Supported by the China Postdoctoral Science Foundation, No. 2022M712265.

Conflict-of-interest statement: All authors disclosed no conflicts of interest.

Open-Access: This article is an open-access article that was selected by an in-house editor and fully peer-reviewed by external reviewers. It is distributed in accordance with the Creative Commons Attribution NonCommercial (CC BY-NC 4.0) license, which permits others to distribute, remix, adapt, build upon this work non-commercially, and license their derivative works on different terms, provided the original work is properly cited and the use is non-commercial. See: <https://creativecommons.org/licenses/by-nc/4.0/>

Country/Territory of origin: China

ORCID number: Wei Liu 0000-0002-6904-9342; Yu-Hang Zhang 0000-0003-2268-6149; Yi Mou 0000-0002-7020-6894; Lian-Song Ye 0000-0001-5542-2508.

S-Editor: Chen YL

L-Editor: A

P-Editor: Yu HG

REFERENCES

- Kim GH. Endoscopic submucosal dissection for early gastric cancer: It is time to consider the quality of its outcomes. *World J Gastroenterol* 2023; **29**: 5800-5803 [PMID: 38074917 DOI: 10.3748/wjg.v29.i43.5800]
- Abe S, Oda I, Suzuki H, Nonaka S, Yoshinaga S, Nakajima T, Sekiguchi M, Mori G, Taniguchi H, Sekine S, Katai H, Saito Y. Long-term surveillance and treatment outcomes of metachronous gastric cancer occurring after curative endoscopic submucosal dissection. *Endoscopy* 2015; **47**: 1113-1118 [PMID: 26165734 DOI: 10.1055/s-0034-1392484]
- Pimingsstorfer P, Biehl M, Gregus M, Kurz F, Schoefl R, Shamiyeh A, Spaun GO, Ziachehabi A, Fuegger R. Endoscopic Submucosal Dissection in the Upper Gastrointestinal Tract and the Need for Rescue Surgery-A Multicenter Analysis. *J Clin Med* 2023; **12** [PMID: 37959405 DOI: 10.3390/jcm12216940]
- Kim EH, Park JC, Song IJ, Kim YJ, Joh DH, Hahn KY, Lee YK, Kim HY, Chung H, Shin SK, Lee SK, Lee YC. Prediction model for non-curative resection of endoscopic submucosal dissection in patients with early gastric cancer. *Gastrointest Endosc* 2017; **85**: 976-983 [PMID: 27756614 DOI: 10.1016/j.gie.2016.10.018]
- Ono H, Yao K, Fujishiro M, Oda I, Uedo N, Nimura S, Yahagi N, Iishi H, Oka M, Ajioka Y, Fujimoto K. Guidelines for endoscopic submucosal dissection and endoscopic mucosal resection for early gastric cancer (second edition). *Dig Endosc* 2021; **33**: 4-20 [PMID: 33107115 DOI: 10.1111/den.13883]
- Chinese Society of Clinical Oncology (CSCO) Guideline Working Committee. Chinese Society of Clinical Oncology (CSCO) Guidelines for the Diagnosis and Treatment of Gastric Cancer. *Zhonghua Yixue Zazhi* 2023; **103**: 27 [DOI: 10.3760/ema.j.cn112137-20230510-00767]
- Li S, Tian X, Wei J, Shi Y, Zhang H, Huang Y. Long-term outcomes of additional surgery versus non-gastrectomy treatment for early gastric cancer after non-curative endoscopic submucosal dissection: a meta-analysis. *Chin Med J (Engl)* 2023; **136**: 528-535 [PMID: 36914940 DOI: 10.1097/CM9.0000000000002605]
- Kishida Y, Takizawa K, Kakushima N, Kawata N, Yoshida M, Yabuuchi Y, Yamamoto Y, Ito S, Imai K, Hotta K, Ishiwatari H, Matsubayashi H, Bando E, Terashima M, Ono H. Endoscopic submucosal dissection versus surgery in elderly patients with early gastric cancer of relative indication for endoscopic resection. *Dig Endosc* 2022; **34**: 497-507 [PMID: 34379850 DOI: 10.1111/den.14105]
- Lamberts LE, Koch M, de Jong JS, Adams ALL, Glatz J, Kranendonk MEG, Terwisscha van Scheltinga AGT, Jansen L, de Vries J, Lub-de

Hooge MN, Schröder CP, Jorritsma-Smit A, Linssen MD, de Boer E, van der Vegt B, Nagengast WB, Elias SG, Oliveira S, Witkamp AJ, Mali WPTM, Van der Wall E, van Diest PJ, de Vries EGE, Ntziachristos V, van Dam GM. Tumor-Specific Uptake of Fluorescent Bevacizumab-IRDye800CW Microdosing in Patients with Primary Breast Cancer: A Phase I Feasibility Study. *Clin Cancer Res* 2017; **23**: 2730-2741 [PMID: 28119364 DOI: 10.1158/1078-0432.CCR-16-0437]

- 10 **Boekstijn I**, van Oosterom MN, Dell'Oglio P, van Velden FHP, Pool M, Maurer T, Rietbergen DDD, Buckle T, van Leeuwen FWB. The current status and future prospects for molecular imaging-guided precision surgery. *Cancer Imaging* 2022; **22**: 48 [PMID: 36068619 DOI: 10.1186/s40644-022-00482-2]



Published by **Baishideng Publishing Group Inc**
7041 Koll Center Parkway, Suite 160, Pleasanton, CA 94566, USA

Telephone: +1-925-3991568

E-mail: office@baishideng.com

Help Desk: <https://www.f6publishing.com/helpdesk>

<https://www.wjgnet.com>

