



Retrospective Study

Computer-assisted three-dimensional individualized extreme liver resection for hepatoblastoma in proximity to the major liver vasculature

Wen-Li Xiu, Jie Liu, Jing-Li Zhang, Jing-Miao Wang, Xue-Feng Wang, Fei-Fei Wang, Jie Mi, Xi-Wei Hao, Nan Xia, Qian Dong

Specialty type: Surgery

Provenance and peer review:

Unsolicited article; Externally peer reviewed.

Peer-review model: Single blind

Peer-review report's scientific quality classification

Grade A (Excellent): 0
Grade B (Very good): 0
Grade C (Good): C
Grade D (Fair): 0
Grade E (Poor): 0

P-Reviewer: Rasa HK, Turkey

Received: November 21, 2023

Peer-review started: November 21, 2023

First decision: January 19, 2024

Revised: January 29, 2024

Accepted: March 15, 2024

Article in press: March 15, 2024

Published online: April 27, 2024



Wen-Li Xiu, Jing-Li Zhang, Jing-Miao Wang, Xue-Feng Wang, Jie Mi, Xi-Wei Hao, Qian Dong, Department of Pediatric Surgery, The Affiliated Hospital of Qingdao University, Qingdao 266000, Shandong Province, China

Jie Liu, Department of Pediatric Surgery, Yijishan Hospital of Wannan Medical College, Wuhu 241000, Anhui Province, China

Fei-Fei Wang, Nan Xia, Qian Dong, Shandong Provincial Key Laboratory of Digital Medicine and Computer-assisted Surgery, Shandong College Collaborative Innovation Center of Digital Medicine Clinical Treatment and Nutrition Health, Qingdao University, Qingdao 266003, Shandong Province, China

Corresponding author: Qian Dong, MD, Professor, Surgeon, Teacher, Department of Pediatric Surgery, The Affiliated Hospital of Qingdao University, No. 16 Jiangsu Road, Shinan District, Qingdao 266000, Shandong Province, China. 18661801885@163.com

Abstract

BACKGROUND

The management of hepatoblastoma (HB) becomes challenging when the tumor remains in close proximity to the major liver vasculature (PMV) even after a full course of neoadjuvant chemotherapy (NAC). In such cases, extreme liver resection can be considered a potential option.

AIM

To explore whether computer-assisted three-dimensional individualized extreme liver resection is safe and feasible for children with HB who still have PMV after a full course of NAC.

METHODS

We retrospectively collected data from children with HB who underwent surgical resection at our center from June 2013 to June 2023. We then analyzed the detailed clinical and three-dimensional characteristics of children with HB who still had PMV after a full course of NAC.

RESULTS

Sixty-seven children diagnosed with HB underwent surgical resection. The age at diagnosis was 21.4 ± 18.8 months, and 40 boys and 27 girls were included. Fifty-nine (88.1%) patients had a single tumor, 39 (58.2%) of which was located in the right lobe of the liver. A total of 47 patients (70.1%) had PRE-TEXT III or IV. Thirty-nine patients (58.2%) underwent delayed resection. After a full course of NAC, 16 patients still had close PMV (within 1 cm in two patients, touching in 11 patients, compressing in four patients, and showing tumor thrombus in three patients). There were 6 patients of tumors in the middle lobe of the liver, and four of those patients exhibited liver anatomy variations. These 16 children underwent extreme liver resection after comprehensive preoperative evaluation. Intraoperative procedures were performed according to the preoperative plan, and the operations were successfully performed. Currently, the 3-year event-free survival of 67 children with HB is 88%. Among the 16 children who underwent extreme liver resection, three experienced recurrence, and one died due to multiple metastases.

CONCLUSION

Extreme liver resection for HB that is still in close PMV after a full course of NAC is both safe and feasible. This approach not only reduces the necessity for liver transplantation but also results in a favorable prognosis. Individualized three-dimensional surgical planning is beneficial for accurate and complete resection of HB, particularly for assessing vascular involvement, remnant liver volume and anatomical variations.

Key Words: Children; Hepatoblastoma; Surgery; Three-dimensional; Computer-assisted

©The Author(s) 2024. Published by Baishideng Publishing Group Inc. All rights reserved.

Core Tip: Children with difficult hepatoblastoma (HB), characterized by a large size and complex location, pose a clinical challenge, particularly when the tumor remains in close proximity to the major liver vasculature (PMV) even after a full course of neoadjuvant chemotherapy (NAC). We retrospectively collected data from 67 children with HB who underwent surgical resection at our center from June 2013 to June 2023. Sixteen patients still had close PMV after a full course NAC and underwent extreme liver resection. In this process, the use of individualized three-dimensional surgical planning is beneficial for achieving safe and complete resection.

Citation: Xiu WL, Liu J, Zhang JL, Wang JM, Wang XF, Wang FF, Mi J, Hao XW, Xia N, Dong Q. Computer-assisted three-dimensional individualized extreme liver resection for hepatoblastoma in proximity to the major liver vasculature. *World J Gastrointest Surg* 2024; 16(4): 1066-1077

URL: <https://www.wjgnet.com/1948-9366/full/v16/i4/1066.htm>

DOI: <https://dx.doi.org/10.4240/wjgs.v16.i4.1066>

INTRODUCTION

Hepatoblastoma (HB) is the most common primary malignant liver tumor in children, and its incidence is increasing[1,2]. The combination of surgery and chemotherapy, particularly neoadjuvant chemotherapy (NAC), has allowed for the delayed resection of many children initially considered unresectable at diagnosis, resulting in a significant improvement in the survival rate of HB patients from approximately 30%[3,4]. Surgery remains a crucial treatment for HB, as it involves completely removing the tumor and preserving sufficient liver volume[5]. However, there is still no consensus on the optimal diagnosis and treatment plan for difficult cases of HB, which are large in size and complex in location.

Clinically, HB is commonly a large tumor when discovered. Over 50% of HB patients cannot be surgically removed at initial diagnosis according to the PRE-TEXT staging system[6]. These patients require preoperative NAC. After 2 to 4 cycles of NAC, the response to treatment was evaluated using the POST-TEXT staging system. The tumor size of large HB significantly decreases due to its high chemotherapeutic sensitivity, allowing for sufficient future liver remnant volume (FLV) for surgery[7]. At this point, the evaluation of vascular involvement becomes crucial in determining the feasibility of tumor resection.

In fact, approximately 25% of HB patients remain in close proximity to the major liver vasculature (PMV), such as the inferior vena cava (IVC), the main portal vein (MPV), the bifurcation of the portal vein (BPV), and the hepatic veins (HVs), even after undergoing a full course of NAC. This poses a clinical challenge when planning further treatment. While liver transplantation can achieve complete tumor resection, there is increased risk due to the use of living donor livers and the need for lifelong immunosuppressive treatment[8,9]. In recent years, aggressive extreme liver resection has emerged as another viable option, as tumor involvement in blood vessels is no longer considered a contraindication for surgical resection.

The computer-assisted surgery system (Hisense CAS) is capable of performing individualized three-dimensional (3D) reconstruction using traditional two-dimensional (2D) computed tomography (CT) images. This system can provide objective and comparable 3D information about the liver, tumors and blood vessels, overcoming the limitations of 2D

images. Additionally, it can be used to efficiently analyze the complex features and anatomical variations of the liver[10, 11]. In this study, we present a case series of HB from a single center and aim to explore the safety of computer-assisted 3D individualized extreme liver resection in HB patients where major liver vasculature is still in close proximity after a full course of NAC.

MATERIALS AND METHODS

Patients and clinical parameters

We retrospectively collected data from children with HB who underwent surgical resection at The Affiliated Hospital of Qingdao University from June 2013 to June 2023. We subsequently analyzed the detailed clinical characteristics and treatment process of HB patients who still had major blood vessels close to the tumor after a full course of NAC. The alpha-fetoprotein (AFP) level and imaging features were monitored during follow-up in all the children. This study was approved by the Ethics Committee of the Affiliated Hospital of Qingdao University (QYFY-WZLL-25776).

Definition and classification of PMV

The PMV is defined according to COG (AHEP0731). In this study, the major liver vasculature of “V” refers to the IVC, all HVs, or both. “P” refers to the MPV, the BPV, or both. The proximity classification was based on the tumor's distance to these vessels: (1) Within 1 cm (V0 or P0); (2) touching (V1 or P1); (3) compressing, or encasing (V2 or P2); and (4) presence of a tumor thrombus or cavernous transformation of the MPV (V3 or P3)[2,3].

The procedure for preoperative NAC

Patients who could not undergo upfront resection during the initial diagnosis underwent needle biopsy to obtain a clear pathological diagnosis of HB. Subsequently, they were administered a standardized chemotherapy regimen, which was extensively described in our previous study[11]. After 2 cycles of chemotherapy, contrast-enhanced CT (CECT) and 3D reconstruction were performed to evaluate the resectability of the tumor. If the tumor remains unresectable, further cycles of chemotherapy and imaging evaluation are continued. The completion of four or more cycles of NAC or tumor enlargement was considered the a full course of NAC.

3D individualized assessment and preoperative planning

Computer-assisted surgery system (Hisense CAS, Qingdao, China) was utilized to conduct 3D reconstruction of the CECT DICOM file. This process allowed for the acquisition of individualized 3D information, including the relationship between the tumor and major blood vessels, as well as the volume of the liver and tumor. The specific steps for this reconstruction have been thoroughly explained in previous reports by our team[9,10]. The PRE-TEXT staging system designed by SIOPEL was used in combination with the individualized 3D model for staging and assessing tumor resectability.

Simulating tumor resection on the 3D model has three modes: (1) Anatomical liver resection, which involves resecting the liver segment invaded by the tumor based on the intrahepatic blood vessel arrangement and vascular domain analysis; (2) tumor dissection, which refers to nonanatomical liver resection. In this mode, a safe resection distance (*e.g.*, 0 mm, 10 mm, *etc.*) is chosen based on the proximity of the tumor to blood vessels, and liver resection is performed along the tumor boundary; and (3) autonomous resection is performed when the tumor is autonomously cut in three dimensions for liver resection based on specific conditions. These three surgical simulation procedures were performed separately to select the best surgical plan.

Surgical resection methods

The incision was made in the upper abdomen, below the costal margin, to access the ligaments around the liver, and the size, location, and relationship of the tumor with nearby organs were examined. The first porta hepatis was dissected, and the intermittent Pringle method was subsequently used to temporarily block hepatic blood flow. Typically, the flow was blocked for 15 to 20 min and then opened for 5 min. The cutting line was determined using electrosurgery based on preoperative planning. During the blocking period, the liver was dissected and separated using cavitation ultrasonic surgical aspiration and vascular forceps to prioritize liver parenchyma resection. Compression and electrocoagulation were used during the opening period to minimize bleeding. The tumor-involved major blood vessels were carefully separated, ligated, and sutured if necessary.

Statistical analysis

The SPSS 26.0 software package was used to organize and analyze the data. Normally distributed data are expressed as the mean \pm SD, and nonnormally distributed data are expressed as the median and quartile. The paired-sample *t* test was used for comparisons before and after treatment. A *P* value < 0.05 was considered to indicate statistical significance.

RESULTS

Characteristics of children with HB

Over a 10-year period, a total of 67 children diagnosed with HB underwent surgical resection. The age at diagnosis was 21.4 ± 18.8 months, and 40 boys and 27 girls were included in the study. Of the 67 patients, 52 (77.6%) presented with upper abdominal masses, and the AFP level was 231109.5 [interquartile range (IQR), 39904.8-434407.8] ng/mL. Fifty-nine (88.1%) patients had a single tumor, 39 (58.2%) had a single tumor located in the right lobe of the liver, and 8 (11.9%) had multiple tumors. The majority of patients (47/67, 70.1%) were classified as PRE-TEXT III or IV. The maximum diameter of the tumor was 10.8 (IQR, 8.3-13.1) cm. Following evaluation and planning using Hisense CAS, 28 children with HB underwent upfront resection. On the other hand, 39 patients (58.2%) who were not eligible for upfront surgery underwent 3 (IQR, 2-4) cycles of NAC followed by delayed resection.

Characteristics of children with HB who remain in PMV after a full course of NAC

Children who received a full course of NAC were evaluated preoperatively. Among the 67 patients, 16 (23.9%) still had tumors in the PMV. The detailed clinical characteristics before and after NAC are presented in Table 1. An equal number of boys and girls were included, with a median age at diagnosis of 30.5 (IQR, 17.0-48.5) months. The median AFP level was 414968.5 (IQR, 271680.5-842240.0) ng/mL. There were 10 and 6 patients in PRE-TEXT III and IV, respectively. The maximum diameter of the tumor was 10.9 (IQR, 9.3-14.3) cm, with a tumor volume of 650.1 (IQR, 326.8-1014.9) cm³. The percentage of tumor-free livers was 40.5% (IQR, 31.0%-45.0%).

After chemotherapy, the AFP level decreased to 2437.0 (IQR, 211.3-26512.5) ng/mL. Eight patients with PRETEXT III were downgraded to POST-TEXT II, two patients with PRETEXT IV were downgraded to POST-TEXT II, and three patients with PRETEXT IV were downgraded to POST-TEXT III. However, one patient was upgraded from PRETEXT III to POST-TEXT IV after three courses of treatment. The maximum diameter of the tumor decreased to 6.8 (IQR, 5.7-7.3) cm, with a corresponding tumor volume of 83.1 (IQR, 47.2-99.7) cm³. The percentage of tumor-free livers increased to 86.5% (IQR, 84.0%-89.0%). Except for one case of tumor progression, the tumor volume decreased in the remaining 15 patients, with a median reduction of 90%. Statistical analysis revealed significant differences in the changes in AFP level, tumor diameter and tumor volume before and after NAC ($P < 0.05$). However, there was no significant difference in the change in the tumor-free liver volume ($P = 0.12$).

Preoperative evaluation and simulated liver resection in children with HB in PMV after a full course of NAC

The details of the preoperative evaluation and simulated liver resection in the 16 children who still had tumors close to the major liver vasculature after a full course of NAC are presented in Table 2. Among the patients, two had tumors within 1 cm, 11 had touching, four had compression, and three had tumor thrombus. Thirteen patients had PMV with the IVC, 9 patients with MPV or BPV, and 3 patients with all HVs. Furthermore, there were 9 cases of tumors involving two lobes of the liver, including three cases of multiple tumors and 6 cases of tumors in the middle lobe of the liver. Additionally, 4 patients (25%) exhibited liver anatomy variations—three with common origins of the middle and left HVs and one with four HVs. Preoperative simulated resection using the Hisense CAS aided in designing individualized surgical plans, with 14 children undergoing simulated anatomical hepatectomy. Ten patients opted for hemihepatectomy (62.5%), 3 chose extended hemihepatectomy, and 1 underwent mesohepatectomy. The simulated FLV was 288.1 (IQR, 177.3-352.0) cm³, and the FLV-to-TLTV ratio was 51.0% (IQR, 41.0%-57.0%) (Figures 1 and 2).

Intraoperative and postoperative results of children with HB who still had PMV after a full course of NAC

Extreme liver resections were performed following thorough preoperative evaluation and simulated tumor resection. During the operation, the precut lines were drawn based on the preoperative plan, and special attention was given to carefully process the blood vessels around the tumor, particularly those compressed by the tumor and any anatomical variations (Figure 3). The tumors were successfully and completely removed, and the operations were successfully completed (Table 3). The operation time was 247.5 (IQR, 205-282.5) minutes. Hepatic flow occlusion lasted for 22.5 (IQR, 15-27.5) minutes and occurred 2 (ranging from 1 to 4) times. In three patients, reconstruction of the IVC was performed, while reconstruction of the middle HV was conducted in one patient. The amount of blood loss was 50 (IQR, 20-100) mL. One child experienced postoperative intestinal obstruction, which was resolved after loosening of the intestinal adhesions. No other complications, such as postoperative bleeding, biliary damage, or liver failure, were observed in the remaining children. The patient was discharged from the hospital after a median of 13 (IQR, 10-15) days postsurgery. Postoperative pathology revealed 9 cases of the epithelial type (including 6 cases of the fetal and embryonal subtype and three cases of the pure fetal subtype) and 7 cases of the mixed epithelial and mesenchymal type. Following chemotherapy after surgery, the lowest AFP level was 5.48 (IQR, 1.7-265.9) ng/mL, and the AFP levels of 8 children returned to the normal range. The AFP levels of four children were slightly greater than the normal range but remained stable during long-term follow-up, including the only child with a positive resection margin (R1).

The study included 67 children with HB, and the median follow-up time was 62 months. The 3-year event-free survival (EFS) rate was 88%. Among the 47 children with PRE-TEXT III and IV, the median follow-up time was 58 months, and the 3-year EFS was 85%. Of the 16 children who underwent extreme liver resection, the median follow-up time was 36 months, three patients experienced recurrence, and one patient died due to multiple metastases during the follow-up period.

Table 1 Characteristics of children with hepatoblastoma who remain in proximity to the major liver vasculature after a full course neoadjuvant chemotherapy

No.	Sex	Age (m)	Before NAC						NAC regimen (cycle)	After NAC						TGR
			AFP (ng/mL)	PRE-TEXT	MTD (cm)	TV (cm ³)	LV (cm ³)	LV/TLTV		AFP (ng/mL)	POST-TEXT	MT (cm)	TV (cm ³)	LV (cm ³)	LV/TLTV	
1	M	73	782230	III	10.8	1109.9	360.1	24%	4	35428	III	7	88.4	597.2	87%	-92%
2	F	16	420190	III	8.5	288.3	248.8	46%	4	47	II	3.9	40.3	328.7	89%	-86%
3	F	2	330590	III	9	365.3	137.8	27%	4	27901	II	5.2	27.3	212.3	89%	-93%
4	M	18	238592	III	6.5	149.4	412.2	73%	4	27	II	4	11.4	380.3	97%	-92%
5	M	29	439147	IV	14.1	732.1	536.2	42%	4	46981	III	7.4	126.5	513.4	80%	-83%
6	M	5	326550	III	9.5	287.3	292	50%	4	276	II	4.7	58.9	351.6	86%	-79%
7	F	22	902250	IV	15.1	1203.8	527.3	30%	4	177	II	7	87.9	533.4	86%	-93%
8	M	26	> 484000	III	8	67.1	347.2	84%	3	> 484000	IV	9.3	235.1	250.3	52%	250%
9	F	3	409747	III	10	459.1	94.4	17%	6	260	II	4.2	25.9	208.9	89%	-94%
10	F	32	> 484000	IV	12.8	658.5	469.3	42%	5	15470	IV	8.6	60	541.2	90%	-91%
11	M	42	> 484000	III	11	641.7	508.5	44%	4	3144	II	5.6	79.7	444.4	85%	-88%
12	M	53	269341	IV	13.5	926	633.8	41%	4	89	II	7.3	91.2	736.6	89%	-90%
13	M	57	87696	III	14.8	949.2	599.6	39%	4	245	II	7.2	113.9	541.7	83%	-88%
14	F	44	274020	IV	16.5	1080.6	594.9	36%	5	1730	III	6.6	108.2	503.9	82%	-90%
15	F	67	541614	IV	14.5	1230.1	571.1	32%	5	25124	III	5.8	86.4	727.7	89%	-93%
16	F	33	80075	III	10.3	392.5	260.1	40%	4	13033	II	4.5	54	336.8	86%	-86%

The volume are automatically calculated and displayed based on 3D reconstruction by Hisense CAS. The normal range of AFP is 0-7.02 ng/mL. NAC: Neoadjuvant chemotherapy; AFP: Alpha-fetoprotein; MTD: Maximum tumor diameter; TV: Tumor volume; LV: Tumor-free liver volume; TLTV: Total volume of liver and tumor; FLV: Future liver remnant volume; TGR: Tumor growth rate (the percentage change in tumor volume).

DISCUSSION

HB is a common malignant solid abdominal tumor in children that accounts for approximately 80% of liver tumors in childhood. The highest incidence is observed in infants and children under 5 years old, and the most common clinical manifestation is an asymptomatic abdominal mass. It has been observed that more than 50% of large HB necessitate NAC followed by delayed surgery due to the inadequate volume of the remnant liver or the involvement of major blood vessels[1,6,10]. Our retrospective analysis revealed that 58.2% of the HB patients underwent delayed resection. However, 23.9% of the HB patients received a full course of NAC; their tumor volume decreased by almost 90%, and the tumor-free liver volume accounted for approximately 85% of the total volume, still remaining close to major blood vessels. Furthermore, simulated surgical resection demonstrated that the remnant liver volume was sufficient (> 30%). This finding

Table 2 The proximity to the major liver vasculature and preoperative evaluation of these 16 hepatoblastoma patients

No.	PMV			Tumor number	Tumor location	Preoperative evaluation and simulated LR			
	Classification	Blood vessel	Group			Simulated mode	Surgical planning	FLV (cm ³)	FLV/TLTV
1	Within 1 cm	IVC	V0	2	Both lobes	Anatomical LR	Right hepatectomy	373.5	54%
	TT	Right HV	V3						
2	Touching	BPV	P1	1	Right lobe	Anatomical LR	Right hepatectomy	177.1	48%
3	Compressing	IVC	V2	1	Middle lobe	Anatomical LR	Extended right hepatectomy	109.7	46%
4	Touching	MPV	P1	1	Middle lobe	Autonomous LR	Extended right hepatectomy; Extended left hepatectomy; Right hepatectomy	288.2	74%
5	Compressing	All intrahepatic veins	V2+P2	1	Middle lobe	Autonomous LR	Right hepatectomy	343	54%
6	Within 1 cm	IVC	V0	1	Right lobe	Anatomical LR		189.3	46%
	Touching								
7	TT	IVC	V1	1	Right lobe	Anatomical LR	Mesohepatectomy	368	59%
	Compressing	Right PV	P3				Right hepatectomy		
8	Touching	All intrahepatic veins	V2+P2	1	Middle lobe	Anatomical LR		177.5	37%
9	Touching	IVC	V1	1	Middle lobe	Anatomical LR	Left hepatectomy + VII	90.6	39%
	Touching	BPV	P1				Right hepatectomy		
10	Touching	BPV	P1	3	Both lobes	Anatomical LR and		348.8	58%
11	Touching	IVC	V1	1	Right lobe	Tumor dissection	Right hepatectomy	287.9	55%
	Touching	BPV	P1			Anatomical LR	Right hepatectomy		
12	Touching	IVC	V1	1	Right lobe			355.1	43%
13	Touching	IVC	V1	1	Right lobe	Anatomical LR	Right hepatectomy + II	224.6	34%
	Touching	All HVs	V1			Anatomical LR	Right hepatectomy		
14	Touching	IVC	V1	2	Both lobes			341.5	56%
15	TT	IVC	V1	1	Right lobe	Anatomical LR	Right hepatectomy	480.5	59%
16	Touching	PV	P3			Anatomical LR			
	Compressing	IVC	V1	1	Middle lobe			146.9	38%
		BPV	P2			Anatomical LR			

PMV: Proximity to the major liver vasculature; LR: Liver resection; FLV: Future liver remnant volume; TLTV: Total volume of liver and tumor; TT: Tumor thrombus; IVC: Inferior vena cava; HV: Hepatic vein; BPV: The bifurcation of the portal vein; MPV: The main of the portal vein; PV: Portal vein.

indicates that proximity to major blood vessels plays a crucial role in determining surgical resectability and presents a challenge for subsequent management strategies in these children.

Currently, all cooperative trial group institutions recommend complex segmental resection or liver transplantation for HB evaluated for major vascular involvement after chemotherapy. Liver transplantation has traditionally been considered the preferred treatment option for advanced HB, especially for patients with POST-TEXT III and IV tumors involving the liver hilus[12]. However, recent advancements in imaging evaluation and surgical techniques have led to more studies recommending aggressive surgical resection for advanced HB. This approach can achieve a similar survival rate to liver transplantation while avoiding transplantation-related risks[13,14]. In this study, precise preoperative assessments and surgical simulations were conducted using a computer-assisted surgery system with 3D reconstruction. This approach helps determine the proximity of the tumor to blood vessels and identify the optimal surgical path. Subsequently, intermittent hepatic inflow occlusion was performed using the Pringle maneuver method and the liver paren-

Table 3 Intraoperative, postoperative and follow-up results of these 16 hepatoblastoma patients

No.	Operation time (min)	Hepatic flow occlusion number and duration	Vascular reconstruction	Blood loss (mL)	Blood transfusion during the operation			Post-operative AFP (ng/mL)	Margin	Pathology	Discharge time (d)	Follow-up	
					RBC (U)	Plasma (mL)	CRYO (U)					Time (m)	Result
1	220	1, 15 min	-	20	1	0	0	1075	R0	FE	6	68	Recurrence
2	165	1, 15 min	-	5	0	0	0	1.33	R0	MEN	9	64	
3	190	1, 20 min	-	20	0	50	40	505.9	R0	MEM	14	61	Recurrence
4	185	1, 15 min	-	5	0.5	0	0	1.37	R0	MEM	9	52	
5	285	2, 20 + 10 min	IVC	100	2	300	2	25.86	R1	MEM	20	46	
6	245	2, 13 + 12 min	-	50	1	100	2	0.87	R0	F	21	42	
7	230	2, 15 + 10 min	-	100	1	120	0	2.55	R0	FE	13	40	
8	250	3, 13 + 12 + 8 min	IVC	200	2	100	0	2517	R0	FE	13	39	Metastasis, death
9	190	1, 15 min	-	10	0.5	0	0	9.15	R0	FE	10	33	
10	295	2, 15 + 10 min	-	100	1	0	2	1.55	R0	MEM	9	16	
11	280	2, 15 + 10 min	-	100	2	0	0	3.29	R0	MEM	15	16	
12	310	1, 15 min	-	50	2	120	2	3.53	R0	F	14	16	
13	255	1, 15 min	-	50	1	0	0	1.84	R0	MEM	11	15	
14	355	4	IVC, MHV	500	6	770	12	7.43	R0	FE	20	9	
15	265	20 + 15 + 18 + 12 min	-	100	1.5	0	0	1642	R0	FE	11	9	
16	245	1, 20, 3, 15 + 15 + 9 min	-	30	1	0	0	8.2	R0	F	14	7	Recurrence

RBC: Red blood cell; CRYO: Cryoprecipitate; AFP: Alpha-fetoprotein; IVC: Inferior vena cava; MHC: Middle hepatic vein; F: Pure fetal subtype; FE: Fetal and embryonal subtype; MEM: Mixed epithelial and mesenchymal type.

chyma-first approach were employed based on preoperative planning. These techniques successfully enabled aggressive extreme liver resection in 16 children with HB who still had tumors close to major blood vessels after completing a full course of NAC. Notably, there were no significant complications, such as hemorrhagic shock or bile leakage.

Due to the complex course and anatomical variation of blood vessels in the liver, as well as the limitations of two-dimensional imaging, assessing the surgical resectability of HB can be challenging. Surgeons often rely on their own anatomical knowledge and surgical experience to perform slice selection on cross-sectional CT or MRI images for evaluating staging and vascular involvement[9,15]. However, studies have shown that its accuracy is only 51%, and it tends to overstage[16]. Therefore, as a radiological staging system based on 2D images, the usefulness of this strategy for

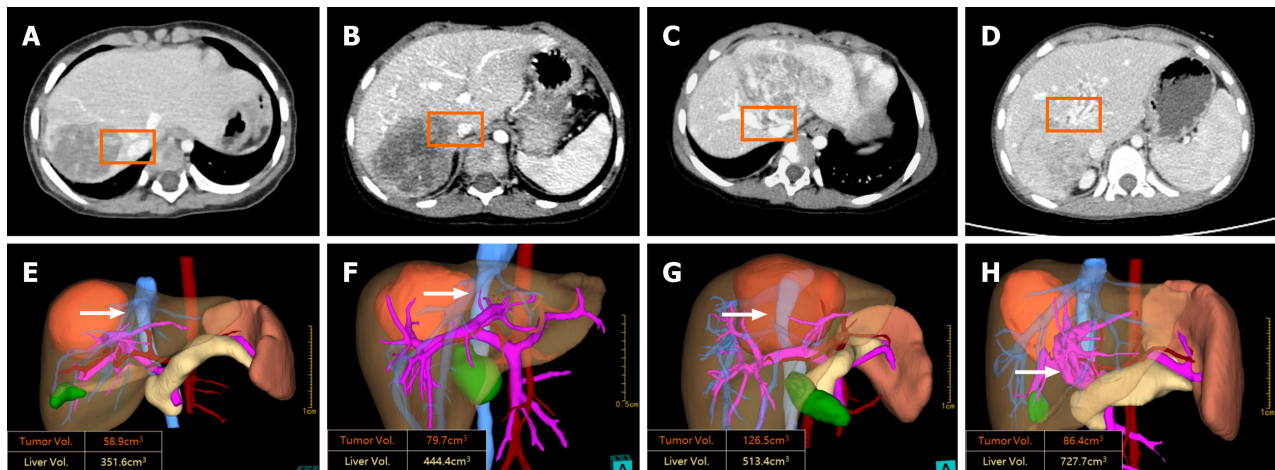


Figure 1 The proximity of the tumor to the major liver vasculature in children with hepatoblastoma who received a full course of neoadjuvant chemotherapy. A and E: The distance from the tumor to the inferior vena cava was within 1 cm (V0); B and F: The tumor was touching the inferior vena cava (V1); C and G: The tumor was compressing all intrahepatic veins (V2+P2); D and H: Presence of a tumor thrombus and cavernous transformation of the portal vein (P3).

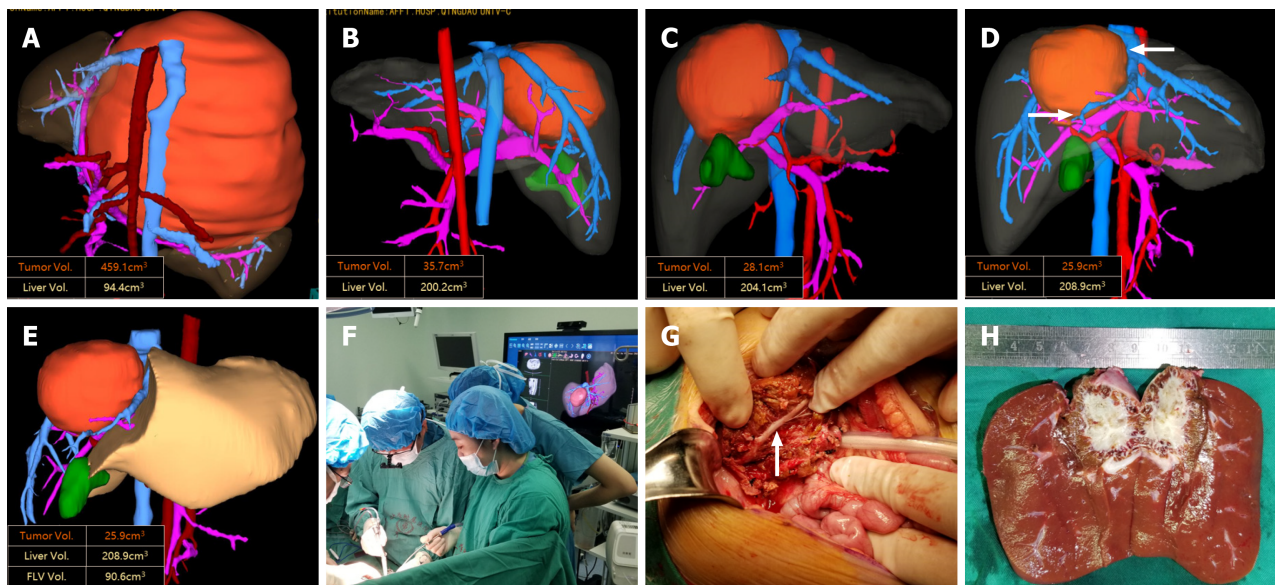


Figure 2 A case of giant hepatoblastoma in the middle lobe of the liver. A: The tumor was initially discovered to be giant, causing distortion and displacement of all the intrahepatic blood vessels. A needle biopsy confirmed the presence of a hepatoblastoma, and neoadjuvant chemotherapy was recommended as the only viable option, in addition to liver transplantation; B: After 4 cycles of chemotherapy, the tumor volume was significantly reduced, but all intrahepatic blood vessels were compressed, making the tumor unresectable; C: Upon re-evaluation after 5 cycles, there was a slight reduction in tumor volume, but the tumor still remained in close proximity to major blood vessels of the liver, preventing surgical resection; D: After 6 cycles, there was no significant change in tumor volume. The tumor was touching the inferior vena cava and portal vein bifurcation, and surgical resection was considered; E: Preoperative simulation of right hemihepatectomy was conducted; F: Intraoperative three-dimensional images were used to assist real-time guidance during the right hemihepatectomy procedure; G and H: The operation proceeded successfully as the preoperative planning, resulting in complete tumor resection while preserving the middle hepatic vein.

surgeons is limited, especially when tumors compress the hepatic hilar structure. We propose the use of 3D images to provide a more objective and accurate evaluation of tumor staging and vascular involvement by utilizing 3D spatial position and distance[17-20]. This method is particularly beneficial for patients with multiple tumors, middle lobe involvement, and variations in liver anatomy and has clinical significance.

In addition, the guidelines for HB surgery prioritize anatomical liver resection, which involves removing more normal liver tissue (greater than 1 cm outside the tumor). Nonanatomical resection or segmental resection, such as extended hepatectomy or middle lobectomy, are often considered for advanced HB[21,22]. However, these procedures make it more challenging to assess the preoperative remnant liver volume. This study utilized three dimensions to track the route of each blood vessel, determine the drainage segment of each vein, and perform the individualized liver segment anatomy. By utilizing 3D volume features, the tumor and liver volume before and after chemotherapy can be objectively calculated, along with the remnant liver volume after simulated surgery. This approach provides overall, comprehensive, and accurate information for liver resection.

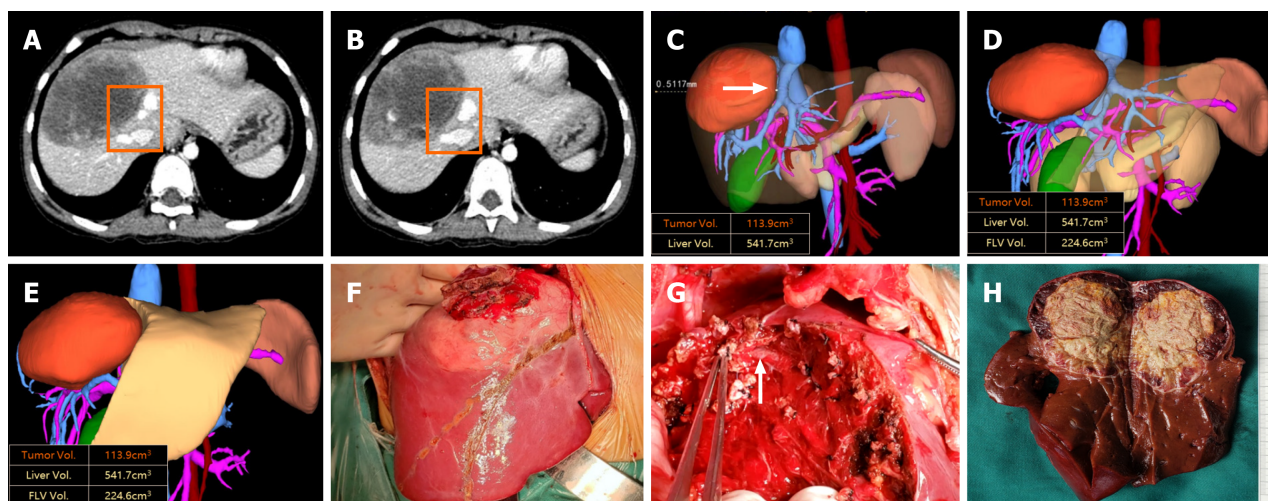


Figure 3 A case of hepatoblastoma evaluated the relationship between the tumor and the major blood vessels of the liver after 5 cycles of neoadjuvant chemotherapy. A and B: Contrast-enhanced computed tomography showed that the tumor was still touching three hepatic veins and the inferior vena cava; C: Three-dimensional imaging based on computed tomography images revealed that the left and middle liver veins merged into the inferior vena cava after the common trunk, with a distance of only 0.5117 mm between the tumor and the common trunk; D and E: Preoperative simulated right hemihepatectomy demonstrated that the future liver remnant volume was sufficient at 34%; F-H: The operation proceeded successfully according to preoperative planning, with careful protection of the common trunk and complete removal of the tumor.

With the advancement of chemotherapy, 2 to 4 cycles of NAC for HB have been shown to increase the probability of surgical resection for unresectable HB at diagnosis. However, more than 4 cycles do not further increase the chance of conventional resection and may instead lead to drug resistance and worsening of chemotherapy toxicity[13]. In this study, we attempted to treat three children with 5 cycles and 1 child with 6 cycles of NAC. However, we observed that the tumor volume did not significantly decrease, and the distance from the major blood vessels increased but still involved after 4 cycles. This could be attributed to drug resistance and vascular targeting. Recent studies have indicated that resection margins less than 1 cm and even microscopic positivity do not affect the overall survival rate of children with HB[23,24]. HB exhibits characteristics such as expansile growth within the capsule and the presence of metastatic cancer nests within the chemotherapy regression area that are still contained within the capsule. Furthermore, postoperative chemotherapy may be crucial for eliminating minimal residual tumor tissue and inhibiting occult micro-metastases[25-27]. We successfully performed extreme liver resection on HB patients whose major blood vessels were involved, and complete resection was achieved. Postoperative AFP levels decreased significantly, and 12 patients dropped to the normal range, indicating good therapeutic efficacy. However, we did observe recurrence in three children (two with tumor thrombus and one with compression), and 1 child died due to insensitivity to chemotherapy and increased tumor size. These patients were considered to have extremely high risk factors associated with the disease itself. This study was limited by the number of patients and the follow-up time. Therefore, further research and long-term follow-up data are necessary to validate our findings.

CONCLUSION

Extreme liver resection for HB that is still in close PMV after a full course of NAC is both safe and feasible. This approach not only reduces the necessity for liver transplantation but also results in a favorable prognosis. Individualized 3D surgical planning is beneficial for accurate and complete resection of HB in children, particularly for assessing vascular involvement, remnant liver volume and anatomical variations.

ARTICLE HIGHLIGHTS

Research background

Hepatoblastoma (HB) is usually a large tumor when it is detected clinically. However, there is currently no consensus on the optimal diagnosis and treatment plan for children with difficult HB who are large size and complex locations. Even after a full course of neoadjuvant chemotherapy (NAC), approximately 25% of HB patients remain in close proximity to the major liver vasculature (PMV). In recent years, aggressive extreme liver resection has become another viable option, and computer-assisted three-dimensional (3D) individualized surgical planning has also been proven to be beneficial for surgery.

Research motivation

Children with HB who still have PMV after a full course of NAC pose a clinical challenge in planning further treatment. After computer-assisted 3D individualized evaluation, aggressive extreme liver resection may be another viable option for reducing the need for liver transplantation.

Research objectives

To explore whether computer-assisted three-dimensional individualized extreme liver resection is safe and feasible for children with HB who still have PMV after a full course of NAC.

Research methods

We retrospectively collected data from children with HB who underwent surgical resection at our center from June 2013 to June 2023. Then, we analyzed the clinical characteristics, PMV classification, 3D individualized assessment, preoperative planning and intraoperative and postoperative results of children with HB who still had PMV after a full course of NAC.

Research results

Sixty-seven children diagnosed with HB underwent surgical resection. After a full course of NAC, 16 patients still had close PMV (within 1 cm in two children, touching in 11 patients, compressing in four patients, and having tumor thrombus in three patients). There were 6 cases of tumors in the middle lobe of the liver, and four of those patients exhibited liver anatomy variations. These 16 children underwent extreme liver resection after comprehensive preoperative evaluation. Intraoperative procedures were performed according to the preoperative plan, and the operations were successfully performed.

Research conclusions

Computer-assisted three-dimensional individualized extreme liver resection for HB patients who are still in close PMV after a full course of NAC is both safe and feasible.

Research perspectives

Aggressive extreme liver resection with individualized 3D surgical planning will provide opportunities for surgical resection of difficult HB patients.

FOOTNOTES

Co-first authors: Wen-Li Xiu and Jie Liu.

Co-corresponding authors: Nan Xia and Qian Dong.

Author contributions: Xiu WL, Liu J, and Zhang JL contributed to data curation and writing of the original draft; Wang JM, Wang XF, and Wang FF contributed to data curation; Mi J, Hao XW, Xia N, and Dong Q contributed to manuscript review and editing; all authors have read and approved the final manuscript.

Supported by National Natural Science Foundation of China, No. 82293665; and Anhui Provincial Department of Education University Research Project, No. 2023AH051763.

Institutional review board statement: This study was approved by the Ethics Committee of the Affiliated Hospital of Qingdao University (approval No. QYFY-WZLL-25776).

Informed consent statement: This is a retrospective study article, and all guardians of the patients signed the informed consent forms before treatment and surgery. The patient's identity information was not disclosed and will not cause any harm to the patient.

Conflict-of-interest statement: The authors declare that they have no conflict of interest to disclose.

Data sharing statement: No additional data are available.

Open-Access: This article is an open-access article that was selected by an in-house editor and fully peer-reviewed by external reviewers. It is distributed in accordance with the Creative Commons Attribution NonCommercial (CC BY-NC 4.0) license, which permits others to distribute, remix, adapt, build upon this work non-commercially, and license their derivative works on different terms, provided the original work is properly cited and the use is non-commercial. See: <https://creativecommons.org/licenses/by-nc/4.0/>

Country/Territory of origin: China

ORCID number: Jie Liu 0000-0003-3956-3209; Qian Dong 0000-0003-4052-4637.

S-Editor: Yan JP

L-Editor: A

REFERENCES

- 1 **Meyers RL**, Maibach R, Hiyama E, Häberle B, Krailo M, Rangaswami A, Aronson DC, Malogolowkin MH, Perilongo G, von Schweinitz D, Ansari M, Lopez-Terrada D, Tanaka Y, Alaggio R, Leuschner I, Hishiki T, Schmid I, Watanabe K, Yoshimura K, Feng Y, Rinaldi E, Saraceno D, Derosa M, Czauderna P. Risk-stratified staging in paediatric hepatoblastoma: a unified analysis from the Children's Hepatic tumors International Collaboration. *Lancet Oncol* 2017; **18**: 122-131 [PMID: 27884679 DOI: 10.1016/S1470-2045(16)30598-8]
- 2 **Murawski M**, Weeda VB, Czauderna P. Surgical management in hepatoblastoma: points to take. *Pediatr Surg Int* 2023; **39**: 81 [PMID: 36631526 DOI: 10.1007/s00383-022-05356-z]
- 3 **Katzenstein HM**, Langham MR, Malogolowkin MH, Krailo MD, Towbin AJ, McCarville MB, Finegold MJ, Ranganathan S, Dunn S, McGahren ED, Tiao GM, O'Neill AF, Qayed M, Furman WL, Xia C, Rodriguez-Galindo C, Meyers RL. Minimal adjuvant chemotherapy for children with hepatoblastoma resected at diagnosis (AHEP0731): a Children's Oncology Group, multicentre, phase 3 trial. *Lancet Oncol* 2019; **20**: 719-727 [PMID: 30975630 DOI: 10.1016/S1470-2045(18)30895-7]
- 4 **Katzenstein HM**, Malogolowkin MH, Krailo MD, Piao J, Towbin AJ, McCarville MB, Tiao GM, Dunn SP, Langham MR, McGahren ED, Finegold MJ, Ranganathan S, Weldon CB, Thompson PA, Trobaugh-Lotrario AD, O'Neill AF, Furman WL, Chung N, Randazzo J, Rodriguez-Galindo C, Meyers RL. Doxorubicin in combination with cisplatin, 5-fluorouracil, and vincristine is feasible and effective in unresectable hepatoblastoma: A Children's Oncology Group study. *Cancer* 2022; **128**: 1057-1065 [PMID: 34762296 DOI: 10.1002/cncr.34014]
- 5 **Busweiler LA**, Wijnen MH, Wilde JC, Sieders E, Terwisscha van Scheltinga SE, van Heurn LW, Ziros J, Bakx R, Heij HA. Surgical treatment of childhood hepatoblastoma in the Netherlands (1990-2013). *Pediatr Surg Int* 2017; **33**: 23-31 [PMID: 27730288 DOI: 10.1007/s00383-016-3989-8]
- 6 **Ziogas IA**, Benedetti DJ, Wu WK, Matsuoka LK, Izzy M, Rauf MA, Pai AK, Bailey CE, Alexopoulos SP. Management of hepatoblastoma in the United States: Can we do better? *Surgery* 2021; **170**: 579-586 [PMID: 33526266 DOI: 10.1016/j.surg.2020.12.035]
- 7 **Agarwala S**, Gupta A, Bansal D, Vora T, Prasad M, Arora B, Kapoor G, Chinnaswamy G, Radhakrishnan V, Laskar S, Kaur T, Dhaliwal RS, Rath GK, Bakhshi S. Management of Hepatoblastoma: ICMR Consensus Document. *Indian J Pediatr* 2017; **84**: 456-464 [PMID: 28353129 DOI: 10.1007/s12098-017-2301-9]
- 8 **Uchida H**, Sakamoto S, Komine R, Kodama T, Nakao T, Okada N, Yanagi Y, Shimizu S, Fukuda A, Shioda Y, Kiyotani C, Matsumoto K, Yoneda A, Haga C, Yoshioka T, Miyazaki O, Nosaka S, Kasahara M. Strategy for hepatoblastoma with major vascular involvement: A guide for surgical decision-making. *Surgery* 2023; **173**: 457-463 [PMID: 36473744 DOI: 10.1016/j.surg.2022.11.002]
- 9 **Yang T**, Whitlock RS, Vasudevan SA. Surgical Management of Hepatoblastoma and Recent Advances. *Cancers (Basel)* 2019; **11** [PMID: 31817219 DOI: 10.3390/cancers11121944]
- 10 **Wu X**, Wang J, Duan Y, Liu Y, Chen X, Xia N, Dong Q. Surgical resection of pediatric PRETEXT III and IV hepatoblastoma: A retrospective study investigating the need for preoperative chemotherapy. *Front Pediatr* 2022; **10**: 878095 [PMID: 36533225 DOI: 10.3389/fped.2022.878095]
- 11 **Liu J**, Xiu W, Duan G, Dong Q. Application of 3D Simulation Software in Chemotherapy and Hepatoblastoma Surgery in Children. *Front Surg* 2022; **9**: 908381 [PMID: 35722529 DOI: 10.3389/fsurg.2022.908381]
- 12 **Honda M**, Uchida K, Irie T, Hirukawa K, Kadohisa M, Shimata K, Isono K, Shimojima N, Sugawara Y, Hibi T. Recent advances in surgical strategies and liver transplantation for hepatoblastoma. *Cancer Med* 2023; **12**: 3909-3918 [PMID: 36394165 DOI: 10.1002/cam4.5300]
- 13 **Trobaugh-Lotrario AD**, Meyers RL, O'Neill AF, Feusner JH. Unresectable hepatoblastoma: current perspectives. *Hepat Med* 2017; **9**: 1-6 [PMID: 28203111 DOI: 10.2147/HMER.S89997]
- 14 **El-Gendi A**, Fadel S, El-Shafei M, Shawky A. Avoiding liver transplantation in post-treatment extent of disease III and IV hepatoblastoma. *Pediatr Int* 2018; **60**: 862-868 [PMID: 29906299 DOI: 10.1111/ped.13634]
- 15 **Towbin AJ**, Meyers RL, Woodley H, Miyazaki O, Weldon CB, Morland B, Hiyama E, Czauderna P, Roebuck DJ, Tiao GM. 2017 PRETEXT: radiologic staging system for primary hepatic malignancies of childhood revised for the Paediatric Hepatic International Tumour Trial (PHITT). *Pediatr Radiol* 2018; **48**: 536-554 [PMID: 29427028 DOI: 10.1007/s00247-018-4078-z]
- 16 **Aronson DC**, Schnater JM, Staalman CR, Weverling GJ, Plaschkes J, Perilongo G, Brown J, Phillips A, Otte JB, Czauderna P, MacKinlay G, Vos A. Predictive value of the pretreatment extent of disease system in hepatoblastoma: results from the International Society of Pediatric Oncology Liver Tumor Study Group SIOPEL-1 study. *J Clin Oncol* 2005; **23**: 1245-1252 [PMID: 15718322 DOI: 10.1200/JCO.2005.07.145]
- 17 **Liu Y**, Xia N, Duan Y, Wu X, Zhao C, Jin C, Chen X, Gao Q, Wang Y, Wang F, Chen Y, Dong Q, Hao X. Application of computer-assisted surgery in pediatric mediastinal tumor surgery. *Int J Med Robot* 2023; **19**: e2489 [PMID: 36471636 DOI: 10.1002/ics.2489]
- 18 **Lamadé W**, Glombitza G, Fischer L, Chiu P, Cárdenas CE Sr, Thorn M, Meinzer HP, Grenacher L, Bauer H, Lehnert T, Herfarth C. The impact of 3-dimensional reconstructions on operation planning in liver surgery. *Arch Surg* 2000; **135**: 1256-1261 [PMID: 11074877 DOI: 10.1001/archsurg.135.11.1256]
- 19 **Zhang G**, Zhou XJ, Zhu CZ, Dong Q, Su L. Usefulness of three-dimensional(3D) simulation software in hepatectomy for pediatric hepatoblastoma. *Surg Oncol* 2016; **25**: 236-243 [PMID: 27566028 DOI: 10.1016/j.suronc.2016.05.023]
- 20 **Warmann SW**, Schenk A, Schaefer JF, Ebinger M, Blumenstock G, Tsiflikas I, Fuchs J. Computer-assisted surgery planning in children with complex liver tumors identifies variability of the classical Couinaud classification. *J Pediatr Surg* 2016; **51**: 1801-1806 [PMID: 27289416 DOI: 10.1016/j.jpedsurg.2016.05.018]
- 21 **Lake CM**, Tiao GM, Bondoc AJ. Surgical management of locally-advanced and metastatic hepatoblastoma. *Semin Pediatr Surg* 2019; **28**: 150856 [PMID: 31931965 DOI: 10.1016/j.sempedsurg.2019.150856]
- 22 **Fuchs J**, Cavdar S, Blumenstock G, Ebinger M, Schäfer JF, Sipos B, Warmann SW. POST-TEXT III and IV Hepatoblastoma: Extended Hepatic Resection Avoids Liver Transplantation in Selected Cases. *Ann Surg* 2017; **266**: 318-323 [PMID: 27501172 DOI: 10.1097/SLA.0000000000001936]
- 23 **Ren X**, Li H, Diao M, Chen L, Xu H, Li L. Results of surgical resections with positive margins for children with hepatoblastoma: Case series from a single Asian center. *Pediatr Blood Cancer* 2019; **66**: e27479 [PMID: 30255649 DOI: 10.1002/pbc.27479]
- 24 **Aronson DC**, Weeda VB, Maibach R, Czauderna P, Dall'Igna P, de Ville de Goyet J, Branchereau S, Perilongo G, Brock P, Ziros J, Semeraro

- M, Chardot C, Wildhaber B, Morland B, Brugières L; Childhood Liver Tumour Strategy Group (SIOPEL). Microscopically positive resection margin after hepatoblastoma resection: what is the impact on prognosis? A Childhood Liver Tumours Strategy Group (SIOPEL) report. *Eur J Cancer* 2019; **106**: 126-132 [PMID: 30528797 DOI: 10.1016/j.ejca.2018.10.013]
- 25 **Shen G**, Wu L, Zhao J, Wei B, Zhou X, Zhuo X, Dong Q. Imaging and Pathology Study of the Chemotherapy Regression Area of Hepatoblastoma - A Prospective Single-Center Study. *Fetal Pediatr Pathol* 2020; **39**: 307-316 [PMID: 31448676 DOI: 10.1080/15513815.2019.1652375]
- 26 **Liu J**, Wu X, Xu C, Ma M, Zhao J, Li M, Yu Q, Hao X, Wang G, Wei B, Xia N, Dong Q. A Novel Method for Observing Tumor Margin in Hepatoblastoma Based on Microstructure 3D Reconstruction. *Fetal Pediatr Pathol* 2022; **41**: 371-380 [PMID: 32969743 DOI: 10.1080/15513815.2020.1822965]
- 27 **Ke M**, Zhou Y, Yang CZ, Li L, Diao M. Analysis of risk factors for angiolymphatic invasion and establishment of a predictive nomogram for hepatoblastomas. *J Pediatr Surg* 2022; **57**: 430-437 [PMID: 35365339 DOI: 10.1016/j.jpedsurg.2022.02.024]



Published by **Baishideng Publishing Group Inc**
7041 Koll Center Parkway, Suite 160, Pleasanton, CA 94566, USA

Telephone: +1-925-3991568

E-mail: office@baishideng.com

Help Desk: <https://www.f6publishing.com/helpdesk>

<https://www.wjgnet.com>

