



Retrospective Study

Comparative analysis of two digestive tract reconstruction methods in total laparoscopic radical total gastrectomy

Tian-Xiang Dong, Dong Wang, Qun Zhao, Zhi-Dong Zhang, Xue-Feng Zhao, Bi-Bo Tan, Yu Liu, Qing-Wei Liu, Pei-Gang Yang, Ping-An Ding, Tao Zheng, Yong Li, Zi-Jing Liu

Specialty type: Gastroenterology and hepatology

Provenance and peer review:

Unsolicited article; Externally peer reviewed.

Peer-review model: Single blind

Peer-review report's scientific quality classification

Grade A (Excellent): 0
Grade B (Very good): 0
Grade C (Good): 0
Grade D (Fair): 0
Grade E (Poor): 0

P-Reviewer: Isobe T, Japan

Received: January 19, 2024

Peer-review started: January 19, 2024

First decision: February 5, 2024

Revised: February 27, 2024

Accepted: March 26, 2024

Article in press: March 26, 2024

Published online: April 27, 2024



Tian-Xiang Dong, Dong Wang, Qun Zhao, Zhi-Dong Zhang, Xue-Feng Zhao, Bi-Bo Tan, Yu Liu, Qing-Wei Liu, Pei-Gang Yang, Ping-An Ding, Tao Zheng, Yong Li, Zi-Jing Liu, Third Department of Surgery of the Fourth Hospital of Hebei Medical University, Hebei Key Laboratory of Precision Diagnosis and Comprehensive Treatment of Gastric Cancer, Shijiazhuang 050011, Hebei Province, China

Corresponding author: Dong Wang, MD, Doctor, Third Department of Surgery of the Fourth Hospital of Hebei Medical University, Hebei Key Laboratory of Precision Diagnosis and Comprehensive Treatment of Gastric Cancer, No. 12 Jiankang Road, Changan District, Shijiazhuang 050011, Hebei Province, China. 15833981527@163.com

Abstract

BACKGROUND

The incidence of gastric cancer has significantly increased in recent years. Surgical resection is the main treatment, but the method of digestive tract reconstruction after gastric cancer surgery remains controversial. In the current study, we sought to explore a reasonable method of digestive tract reconstruction and improve the quality of life and nutritional status of patients after surgery. To this end, we statistically analyzed the clinical results of patients with gastric cancer who underwent jejunal interposition double-tract reconstruction (DTR) and esophageal jejunum Roux-en-Y reconstruction (RY).

AIM

To explore the application effect of DTR in total laparoscopic radical total gastrectomy (TLTG) and evaluate its safety and efficacy.

METHODS

We collected the relevant data of 77 patients who underwent TLTG at the Fourth Hospital of Hebei Medical University from October 2021 to January 2023. Among them, 35 cases were treated with DTR, and the remaining 42 cases were treated with traditional RY. After 1:1 propensity score matching, the cases were grouped into 31 cases per group, with evenly distributed data. The clinical characteristics and short- and long-term clinical outcomes of the two groups were statistically analyzed.

RESULTS

The two groups showed no significant differences in basic data, intraoperative blood loss, number of lymph node dissections, first defecation time after operation, postoperative hospital stay, postoperative complications, and laboratory examination results on the 1st, 3rd, and 5th days after operation. The operation time of the DTR group was longer than that of the RY group [(307.58 ± 65.14) min *vs* (272.45 ± 62.09) min, *P* = 0.016], but the first intake of liquid food in the DTR group was shorter than that in the RY group [(4.45 ± 1.18) d *vs* (6.0 ± 5.18) d, *P* = 0.028]. The incidence of reflux heartburn (Visick grade) and postoperative gallbladder disease in the DTR group was lower than that in the RY group (*P* = 0.033 and *P* = 0.038). Although there was no significant difference in body weight, hemoglobin, prealbumin, and albumin between the two groups at 1, 3 and 6 months after surgery, the diet of patients in the DTR group was better than that in the RY group (*P* = 0.031).

CONCLUSION

The clinical effect of DTR in TLTG is better than that of RY, indicating that it is a more valuable digestive tract reconstruction method in laparoscopic gastric cancer surgery.

Key Words: Gastric cancer; Jejunal interposition double-tract reconstruction; Roux-en-Y reconstruction; Laparoscope

©The Author(s) 2024. Published by Baishideng Publishing Group Inc. All rights reserved.

Core Tip: We statistically analyzed the clinical results of patients with gastric cancer who underwent jejunal interposition double-tract reconstruction (DTR) and esophageal jejunum Roux-en-Y reconstruction (RY). Finally, it was found that compared to RY, DTR can improve postoperative life treatment, improve postoperative nutritional status, and reduce the incidence of gallbladder disease. It can also provide a duodenal pathway for endoscopic retrograde cholangio pancreatography, representing a better digestive tract reconstruction method than traditional Roux-en-Y esophagojejunostomy.

Citation: Dong TX, Wang D, Zhao Q, Zhang ZD, Zhao XF, Tan BB, Liu Y, Liu QW, Yang PG, Ding PA, Zheng T, Li Y, Liu ZJ. Comparative analysis of two digestive tract reconstruction methods in total laparoscopic radical total gastrectomy. *World J Gastrointest Surg* 2024; 16(4): 1109-1120

URL: <https://www.wjgnet.com/1948-9366/full/v16/i4/1109.htm>

DOI: <https://dx.doi.org/10.4240/wjgs.v16.i4.1109>

INTRODUCTION

Gastric cancer is the fourth most common malignant tumor worldwide and is one of the leading causes of cancer-related death[1]. Surgical resection of the entire tumor and complete lymph node dissection are the main treatments for gastric cancer[2]. With the development of laparoscope technology and equipment, radical laparoscopic surgery for gastric cancer has been widely performed in clinical practice[3]. Currently, the incidence of proximal gastric cancer and esophagogastric junction cancer is increasing annually, and the proportion of laparoscopic total gastrectomy in gastric cancer surgery is also increasing. However, compared to laparoscopic distal gastrectomy, laparoscopic total gastrectomy lacks the results of prospective randomized clinical trials to confirm its safety and effectiveness[4]. Although some retrospective and cohort studies have confirmed that the safety and short- and long-term efficacy of laparoscopic total gastrectomy are not inferior to open total gastrectomy[5,6], laparoscopic total gastrectomy is only performed in some experienced and large medical centers in China.

Esophageal jejunum Roux-en-Y reconstruction (RY) is the main method of digestive tract reconstruction after laparoscopic total gastrectomy because it is simple, safe, and has an acceptable probability of serious complications after surgery. However, RY has the disadvantages of a high incidence of reflux esophagitis and postoperative gallstones, and it is difficult for endoscopy to examine or treat biliary and pancreatic diseases[7]. To address these shortcomings, Kajitani and Sato first described jejunal interposition double-tract reconstruction (DTR) after gastrectomy in 1965[8]. Compared to RY, DTR has the advantage of retaining the duodenal pathway. Moreover, the passage of food can stimulate the secretion of digestive juice and enhance the digestion and absorption of food by the gastrointestinal system of patients, thus ensuring good nutritional status. Simultaneously, it can also reduce the incidence of reflux esophagitis and dumping syndrome and improve the quality of life of patients after surgery[2].

At that time, the operation of the DTR was too complicated and the operation time was too long and technically challenging. Therefore, there have been few reports on the completion of DTR under total laparoscopy by domestic and foreign researchers. However, with the iterative update of anastomosis instruments and barbed sutures, a good platform has been built for completing DTR under total laparoscopy. In the process of laparoscopic reconstruction of digestive tract anastomosis, the volume of the circular stapler is larger than that of the linear cutting stapler; therefore, it is necessary to close and reconstruct the pneumoperitoneum and complete the anastomosis repeatedly with the help of the abdominal small incision, which increases the complexity of the operation to some extent. In our center, we use a linear cutting stapler to complete the laparoscopic DTR, avoiding the cumbersome steps of circular stapler anvil and operating rod placement, duodenal purse-string suture, and posterior wall reinforcement suture, thereby reducing the operation time

and improving the safety of the operation[9]. The purpose of this study was to explore the application effect of DTR in total laparoscopic radical total gastrectomy (TLTG) and to evaluate its safety and effectiveness.

MATERIALS AND METHODS

Participant recruitment, inclusion criteria, and exclusion criteria

We retrospectively analyzed the data of 77 patients who underwent TLTG at the Fourth Hospital of Hebei Medical University from October 2021 to January 2023, comprising 35 cases undergoing DTR and 42 cases of RY. After propensity score matching (PSM), the patients were grouped into 31 cases per group. The inclusion criteria were as follows: (1) Patients undergoing TLTG; and (2) postoperative pathological diagnosis of gastric cancer. The exclusion criteria were as follows: (1) Combined organ resection; (2) other surgical problems that should be dealt with during the operation (*e.g.*, hernia repair, cholecystectomy, intestinal adhesion lysis); (3) history of other cancers; (4) confirmed distant metastases; and (5) history of gastric or esophageal surgery or gastric stump cancer. All patients signed informed consent.

Surgical procedure

DTR: (1) D2 Lymph node dissection and total gastrectomy were performed under laparoscopy. The pneumoperitoneum was closed, and the specimen was removed from the supraumbilical median incision (approximately 4 cm in length). After confirming the safety of the upper residual distance of the specimen, it was sent for histopathological examination. The upper jejunum was lifted outside the abdominal cavity. An ultrasonic scalpel was used to open the jejunal mesenteric avascular area at approximately 20 cm from the Treitz ligament, and the vascular arch was ligated and cut off. The jejunum was then severed using a linear cutting stapler. Jejunal side-to-side anastomosis was performed at a distance of 60 cm from the distal jejunum blind loop, and the mesenteric hiatus was closed (Figure 1A-C); (2) After reconstructing the pneumoperitoneum, it was confirmed that the distal jejunum (jejunal food loop) could be easily lifted to the site of the esophageal stump. The area 35 cm away from the jejunal blind loop was fixed with the descending duodenum using an absorbable suture. Then, the ultrasonic scalpel was used to open the above two positions (Figure 1D); (3) A linear cutting stapler (white nail) with a length of 60 or 45 mm was inserted into the abdominal cavity through the left upper Trocar orifice. The two arms of the linear cutting stapler were placed at the above two openings to complete the side-to-side anastomosis of the duodenum-jejunum (the width of the anastomosis was 40–45 mm) (Figure 1E); (4) The duodenum-jejunum side-to-side anastomosis was continuously sutured using a 3-0 barbed suture (Figure 1F); (5) The duodenal stump was sutured with a 3-0 barbed suture (Figure 1G); and (6) The esophageal stump and the distal jejunum blind loop were fixed together with absorbable sutures. The esophageal stump and the distal jejunum blind loop were opened using an ultrasonic scalpel. The esophageal-jejunum side-to-side anastomosis (overlap anastomosis) was completed using a linear cutting stapler. Subsequently, a barbed suture was used for continuous suture to close the common opening and complete the DTR (Figure 1H and I)[10].

RY: (1) D2 Lymph node dissection and total gastrectomy were performed under laparoscopy. The pneumoperitoneum was closed and the specimen was removed from the supraumbilical median incision (approximately 4 cm in length). After confirming the safety of the upper residual distance of the specimen, it was sent for histopathological examination. The upper jejunum was lifted outside the abdominal cavity. An ultrasonic scalpel was used to open the jejunal mesenteric avascular area at approximately 20 cm from the Treitz ligament, and the vascular arch was ligated and cut off. The jejunum was then severed using a linear cutting stapler. Jejunal side-to-side anastomosis was performed at a distance of 60 cm from the distal jejunum blind loop, and the mesenteric hiatus was closed; (2) The duodenal stump was sutured with a 3-0 barbed suture; and (3) The esophageal stump and the distal jejunum blind loop were fixed together with absorbable sutures. The esophageal stump and the distal jejunum blind loop were opened using an ultrasonic scalpel. The esophageal-jejunum side-to-side anastomosis (overlap anastomosis) was completed using a linear cutting stapler. Subsequently, a barbed suture was used for continuous suture to close the common opening and complete the RY.

Observed indices

According to the medical and anesthesia records, we obtained the sex, age, body mass index (BMI), tumor location, pathological stage, tumor size, operation time, intraoperative blood loss, number of lymph node dissections, postoperative first defecation time, first feeding time, and postoperative hospital stay of 77 patients. Laboratory tests were performed on all patients on the 1st, 3rd, and 5th days after surgery, and the levels of white blood cells, neutrophils, and platelets were recorded. Postoperative complications were graded according to the Clavien-Dindo classification. The incidence of gallbladder diseases (including cholecystitis, gallstones, bile salt deposition) was determined according to the CT examination results of the patients at 6 months after surgery. Laboratory tests were performed on the patients at 1, 3, and 6 months after surgery to obtain the patient's hemoglobin, prealbumin, and albumin levels and record the patient's weight. The patients were followed up 6 months after the operation. Reflux heartburn symptoms were graded according to the Visick classification, and the patient's food intake ratio (postoperative total daily intake/preoperative total daily intake) was determined.

Statistical analysis

Statistical analyses were performed using SPSS 26.0. A two-sample Student's *t*-test or rank sum test was used to compare continuous variables, and the χ^2 test or Fisher's exact test was performed for categorical variables. The rank sum test was used for grade data. *P* values < 0.05 were considered statistically significant. All observed factors were subjected to PSM,

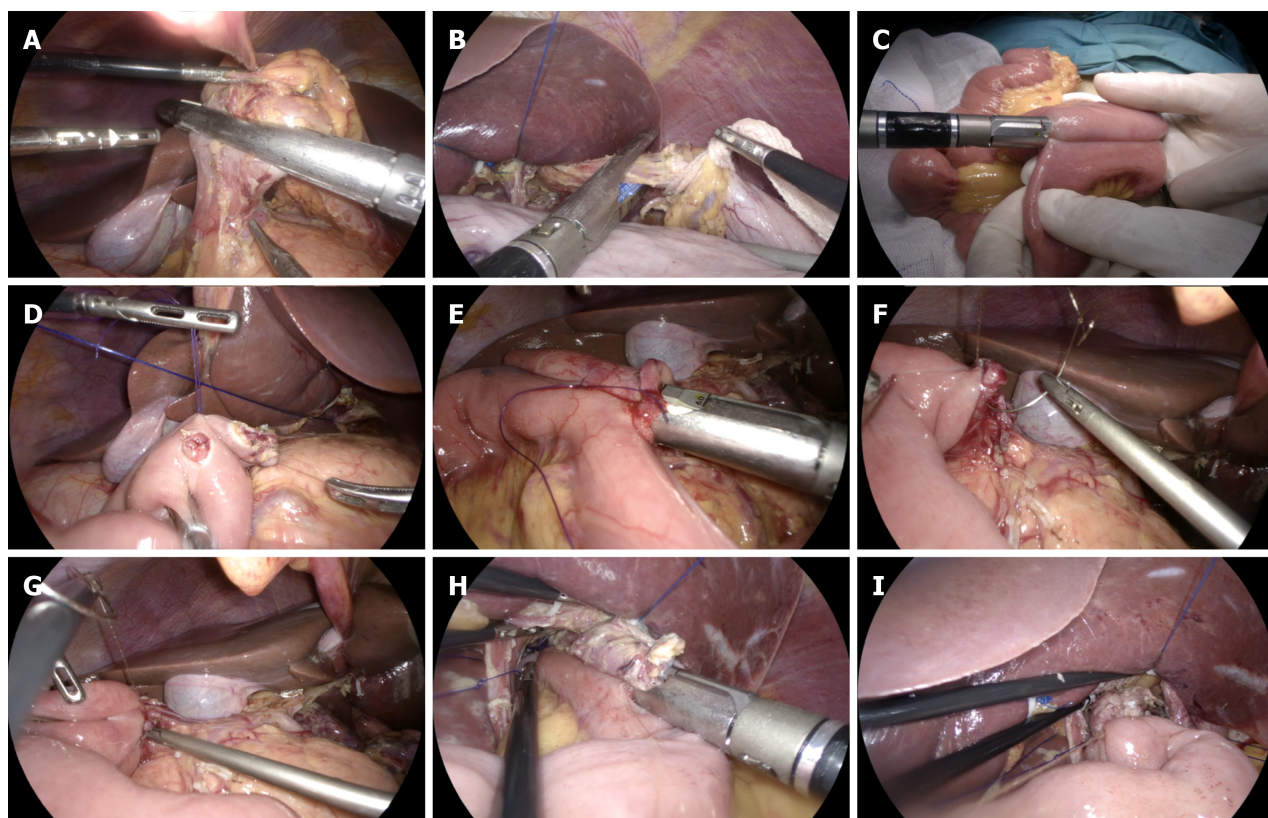


Figure 1 Total laparoscopic radical total gastrectomy + jejunal interposition double-tract reconstruction. A: After cleaning the upper and lower pyloric lymph nodes, the duodenum was severed using a linear cutting stapler; B: Disconnection of esophagus; C: The Jejunal side-to-side anastomosis was completed by a linear cutting stapler; D: Duodenum and jejunum openings; E: Linear cutting stapler to complete duodenum-jejunum side-to-side anastomosis; F: The common opening of duodenum jejunum anastomosis was sutured by barbed suture; G: Suture the duodenal stump with barbed suture; H: Linear cutting stapler to complete esophageal jejunum overlap anastomosis; I: The barbed suture was continuously sutured to close the common opening of esophagus jejunum.

and the matching caliper value was 0.2. Continuous variables are represented as the mean \pm SD, and categorical variables are represented as n (%).

RESULTS

Clinical characteristics of the patients

A total of 77 patients with gastric cancer were included in our study, including 60 males and 17 females; the average age of the patients was (58.49 ± 11.10) years, ranging from 26 to 77 years; and the average BMI was (24.79 ± 3.54). In terms of the tumor location, 44 cases were in the upper part of the gastric body, 15 cases were in the middle part of the gastric body, and 18 cases were in the lower part of the gastric body. Regarding postoperative pathological staging, 20 cases were stage I, 21 cases were stage II, and 36 cases were stage III. The mean longest tumor diameter was (4.40 ± 2.33) cm. Additionally, there were 35 cases of DTR and 42 cases of RY.

Baseline levels before and after PSM

The following six covariates were selected for PSM: Sex, age, BMI, tumor location, postoperative pathological stage, and longest tumor diameter. After 1:1 PSM, 62 patients were finally included in the study (Table 1), with no significant differences in sex, age, BMI, tumor location, pathological stage, and longest tumor diameter between the two groups.

The short-term clinical outcomes of the two groups of patients, including the intraoperative conditions, postoperative recovery, surgical complications, white blood cells, neutrophils, and platelet levels on the 1st, 3rd, and 5th days after surgery, were evaluated

The two groups showed no significant difference in intraoperative blood loss, number of lymph node dissections, postoperative first defecation time, and postoperative hospital stay. The operation time of the DTR group was longer than that of the RY group [(307.58 \pm 65.14) min *vs* (272.45 \pm 62.09) min, $P = 0.016$]. The first intake of liquid food in the DTR group was shorter than that in the RY group [(4.45 \pm 1.18) d *vs* (6.0 \pm 5.18) d, $P = 0.028$]. In terms of surgical complications, there was no significant statistical difference between the two groups. There were 21 cases of type II complications in the DTR group, without abdominal infection or anastomotic-related complications. There were 25 cases of type II complica-

Table 1 Baseline data before and after propensity score matching in the two groups of patients, *n* (%)

Variables	Before PSM		<i>P</i> value	After PSM		<i>P</i> value
	DTR (<i>n</i> = 35)	RY (<i>n</i> = 42)		DTR (<i>n</i> = 31)	RY (<i>n</i> = 31)	
Age (yr)			0.582			1
≤ 60	20 (57.1)	19 (45.2)		16 (51.6)	16 (51.6)	
> 60	15 (42.9)	23 (54.8)		15 (48.4)	15 (48.4)	
Sex			0.989			1
Female	8 (22.9)	9 (21.4)		7 (22.6)	7 (22.6)	
Male	27 (77.1)	33 (78.6)		24 (77.4)	24 (77.4)	
BMI			0.932			0.594
18.4-24.2	16 (45.7)	21 (50.0)		16 (51.6)	12 (38.7)	
24.3-34.67	19 (54.3)	21 (50.0)		15 (48.4)	19 (61.3)	
Tumor location			1			0.968
Upper	20 (57.1)	24 (57.1)		18 (58.1)	17 (54.8)	
Middle/lower	15 (42.9)	18 (42.9)		13 (41.9)	14 (45.2)	
TNM stage			0.481			0.878
I/II	16 (45.7)	25 (59.5)		16 (51.6)	18 (58.1)	
III	19 (54.3)	17 (40.5)		15 (48.4)	13 (41.9)	
Longest tumor diameter (cm)			0.707			0.968
0.8-3.9	15 (42.9)	22 (52.4)		15 (48.4)	16 (51.6)	
4.0-14.0	20 (57.1)	20 (47.6)		16 (51.6)	15 (48.4)	

PSM: Propensity score matching; BMI: Body mass index; TNM: Tumor-node-metastasis; DTR: Double-tract reconstruction; RY: Roux-en-Y reconstruction.

ations and two cases of type III complications in the RY group. In the RY group, one patient had abdominal infection and anastomotic bleeding and one patient had esophagojejunal anastomotic leakage. The two patients were cured and discharged after conservative treatment. There were no cases of death between the two groups of patients, and they were discharged smoothly (Table 2). Additionally, there was no significant difference in the levels of white blood cells, neutrophils, and platelets between the two groups on the 1st, 3rd, and 5th days after surgery (Figure 2).

The long-term clinical outcomes of the two groups of patients, including the postoperative body weight, postoperative hemoglobin, postoperative albumin, postoperative prealbumin level, food intake ratio, gallbladder disease incidence, and postoperative quality of life, were evaluated

The nutritional status between the two groups was compared by assessing body weight, diet recovery, and hemoglobin, prealbumin, and albumin levels. There was no significant difference in body weight, hemoglobin, prealbumin, and albumin levels between the two groups before surgery. At 1, 3, and 6 months after surgery, the body weight, hemoglobin, albumin, and prealbumin levels of the two groups decreased, with no significant difference between the two groups (Figure 3). The ratio of food intake in the DTR group was higher than that in the RY group at 6 months after surgery [$(89.61 \pm 14.75)\%$ vs $(80.06 \pm 17.60)\%$, $P = 0.031$]. According to the CT results of the two groups of patients at 6 months after the operation, the incidence of gallbladder disease (including cholecystitis, gallstones, bile salt deposition) was determined. The incidence of gallbladder disease in the DTR group was 6.5%. The probability of gallbladder disease in the RY group was 25.8%, with a significant statistical difference ($P = 0.038$). During the 6-month follow-up, the postoperative reflux heartburn symptoms (Visick grade) of patients with DTR were significantly lower than those of the RY group ($P = 0.033$), see Table 3.

Postoperative gastrointestinal imaging results of the two groups of patients

The two groups of patients completed upper gastrointestinal angiography approximately 1 wk after surgery. Angiography confirmed that all patients in the DTR group had no complications such as anastomotic leakage and anastomotic stenosis, and the contrast agent could pass smoothly through the esophagojejunal and duodenal jejunum anastomoses. Angiography demonstrated that one patient in the RY group had an esophagojejunal anastomotic fistula, while no anastomotic complications occurred in the remaining patients. The results of the two groups of patients are shown in Figure 4.

Table 2 Recent clinical outcomes of the two groups of patients

	DTR (n = 31)	RY (n = 31)	P value
Operation time (min)	307.58 ± 65.14	272.45 ± 62.09	0.016 ^a
Blood loss during operation (mL)	47.42 ± 29.77	47.58 ± 29.21	0.971
Number of lymph node dissection	45.16 ± 15.10	47.97 ± 16.84	0.512
The first postoperative exhaust time (d)	3.23 ± 0.72	3.06 ± 1.18	0.158
The first time to eat liquid food after operation (d)	4.45 ± 1.18	6.0 ± 5.18	0.028 ^a
Hospital stay after operation (d)	7.71 ± 2.15	8.87 ± 5.49	0.65
Operative complications			0.079
Grade II			
Pneumonia	17	22	
Lower limb thrombosis	11	14	
Grade III			
Abdominal infection	0	2	
Anastomotic bleeding	0	1	
Esophageal jejunum anastomotic fistula	0	1	
White blood cells (10 ⁹ /L)			
Preoperative	5.73 ± 1.41	5.22 ± 1.59	0.19
The first day after surgery	11.51 ± 2.81	10.79 ± 3.14	0.344
The third day after surgery	8.24 ± 2.15	7.65 ± 3.13	0.39
The fifth day after surgery	6.86 ± 1.82	7.43 ± 2.15	0.265
Neutrophils (10 ⁹ /L)			
Preoperative	3.61 ± 1.38	3.28 ± 1.25	0.32
The first day after surgery	10.01 ± 2.73	9.47 ± 2.89	0.449
The third day after surgery	6.74 ± 1.95	6.29 ± 2.97	0.486
The fifth day after surgery	5.02 ± 1.75	5.68 ± 1.99	0.167
Platelets (10 ⁹ /L)			
Preoperative	232.97 ± 63.29	219.65 ± 54.07	0.376
The first day after surgery	198.77 ± 55.44	181.77 ± 51.13	0.214
The third day after surgery	173.45 ± 45.10	152.19 ± 49.45	0.082
The fifth day after surgery	187.94 ± 46.52	174.87 ± 58.41	0.334

^aP < 0.05.

Continuous variables are represented by mean ± SD, and categorical variables are represented by n (%). DTR: Double-tract reconstruction; RY: Roux-en-Y reconstruction.

Patients' gastroscopy results at 6 months after surgery

The patients completed gastroscopy 6 months after the operation. For the patients in the DTR group, it was possible to see the duodenal jejunum anastomosis under gastroscopy, and the width of the anastomosis was approximately 45 mm. No anastomotic ulcer, stenosis, bleeding, or canceration were found in the two groups under gastroscopy. The gastroscopy results of the DTR and RY groups are shown in [Figure 5](#).

DISCUSSION

Total laparoscopic total gastrectomy has been increasingly used since Uyama *et al*[11] first reported the study of total laparoscopic total gastrectomy in 1999. Compared to open surgery, laparoscopic gastric cancer surgery has the advantages of clear vision, less bleeding, less postoperative pain and faster recovery[12]. However, similar to open total

Table 3 Long-term clinical outcomes of the two groups of patients

	DTR (n = 31)	RY (n = 31)	P value
Food intake ratio (%)	89.61 ± 14.75	80.06 ± 17.60	0.031 ^a
Gallbladder disease, n (%)			0.038 ^a
Positive	2 (6.5)	8 (25.8)	
Negative	29 (93.5)	23 (74.2)	
Visick grade, n (%)			0.033 ^a
I	18 (61.3)	11 (35.4)	
II	12 (35.5)	14 (45.2)	
III	1 (3.2)	6 (19.4)	
Weight (kg)			
Preoperative	71.86 ± 12.77	69.34 ± 13.14	0.447
Pos 1m	63.5 ± 11.73	62.03 ± 11.34	0.618
Pos 3m	59.24 ± 11.74	58.15 ± 10.84	0.704
Pos 6m	57.85 ± 10.25	56.55 ± 10.90	0.631
Hemoglobin (g/L)			
Preoperative	134.22 ± 22.05	137.77 ± 18.49	0.495
Pos 1m	123.16 ± 15.84	122.48 ± 12.16	0.849
Pos 3m	118.97 ± 11.39	119.21 ± 8.39	0.925
Pos 6m	119.32 ± 16.68	117.20 ± 11.45	0.561
Prealbumin (mg/L)			
Preoperative	270.09 ± 48.0	265.52 ± 41.41	0.689
Pos 1m	213.17 ± 56.55	204.18 ± 41.68	0.479
Pos 3m	202.37 ± 57.15	201.34 ± 44.37	0.937
Pos 6m	203.25 ± 36.66	185.12 ± 45.44	0.089
Albumin (g/L)			
Preoperative	42.51 ± 3.35	42.20 ± 2.44	0.672
Pos 1m	40.80 ± 2.31	40.25 ± 2.45	0.368
Pos 3m	40.43 ± 3.21	39.93 ± 2.83	0.521
Pos 6m	40.45 ± 3.91	39.66 ± 4.12	0.44

^aP < 0.05.

Continuous variables are represented by mean ± SD, and categorical variables are represented by n (%). DTR: Double-tract reconstruction; RY: Roux-en-Y reconstruction; Pos 1m: At 1 month after operation; Pos 3m: At 3 months after operation; Pos 6m: At 6 months after operation.

gastrectomy, patients undergoing total laparoscopic total gastrectomy cannot avoid postgastrectomy syndromes, such as malnutrition, weight loss, dumping syndrome, gallstones, and alkaline reflux esophagitis, all of which can seriously reduce the quality of life of patients after surgery[13]. The selection of appropriate digestive tract reconstruction during surgery plays a vital role in reducing postoperative complications[14]. Recently, DTR, as a new type of digestive tract reconstruction method, has been gradually valued by some surgeons. This procedure retains the physiological function of the duodenal pathway, fully integrates the digestive fluid with food, and is conducive to improving the postoperative nutritional status of patients. DTR can also reduce the reflux of alkaline digestive fluid and improve the quality of life of patients[2,14,15]. In 2000, the Japanese scholar Uyama *et al*[16] first reported the study of total laparoscopic proximal gastrectomy + jejunal interposition double-channel anastomosis, indicating that the operation of DTR under laparoscopy is both safe and feasible. Our center also uses a linear cutting stapler to anastomose the anastomosis, thereby reducing the operation process and shortening the operation time to ensure the safety of the operation.

The results showed no significant difference in intraoperative blood loss, number of lymph node dissections, first postoperative defecation time, postoperative hospital stay, surgical complications, and postoperative laboratory test results between the two groups of patients. The operation time of the DTR group was longer than that of the RY group

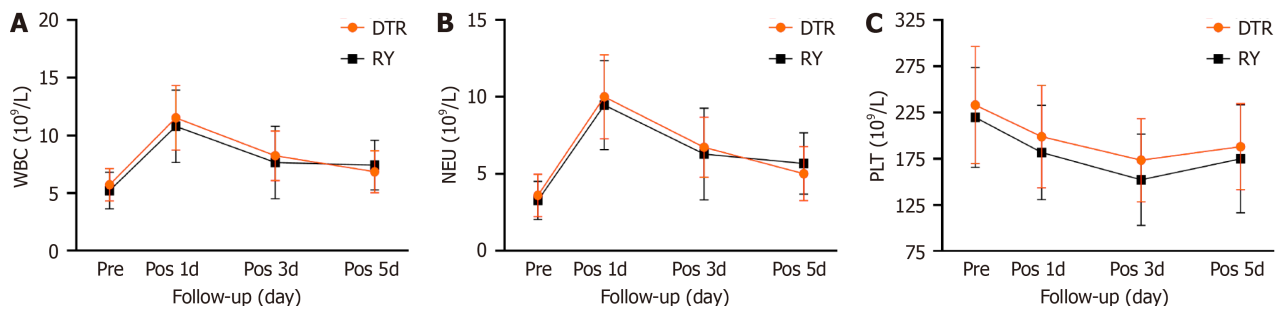


Figure 2 Two groups of patients with postoperative white blood cells, neutrophils and platelets change line chart. A: White blood cells change line chart; B: Neutrophils change line chart; C: Platelets change line chart. DTR: Double-tract reconstruction; RY: Roux-en-Y reconstruction; WBC: White blood cells; NEU: Neutrophils; PLT: Platelets; Pre: Preoperative; Pos 1d: The first day after surgery; Pos 3d: The third day after surgery; Pos 5d: The fifth day after surgery.

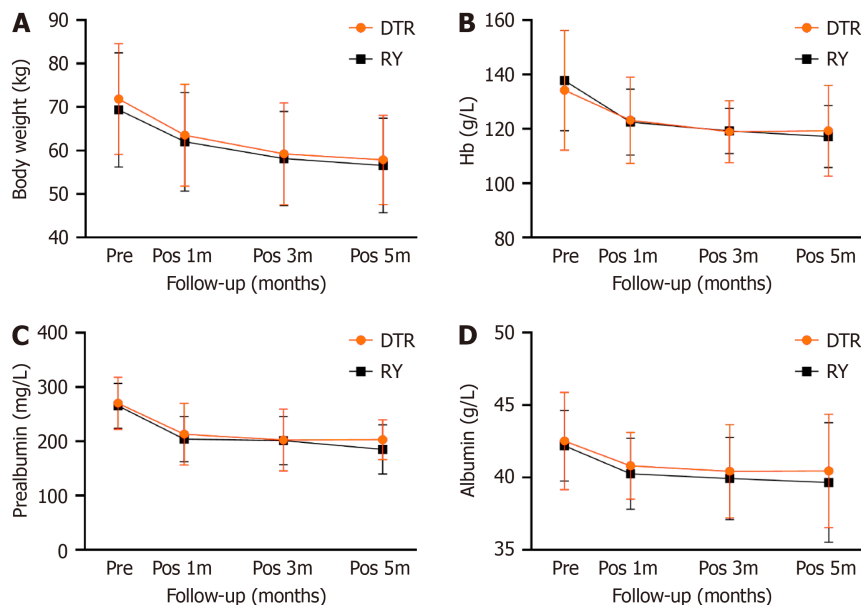


Figure 3 Line chart showing the body weight, prealbumin, albumin, and hemoglobin changes of the two groups of patients. A: Body weight change line chart; B: Hemoglobin change line chart; C: Prealbumin change line chart; D: Albumin change line chart. DTR: Double-tract reconstruction; RY: Roux-en-Y reconstruction; Hb: Hemoglobin; Pre: Preoperative; Pos 1m: At 1 month after operation; Pos 3m: At 3 months after operation; Pos 5m: At 5 months after operation.

[(307.58 ± 65.14) min vs (272.45 ± 62.09) min, $P = 0.016$], but the first intake of liquid food in the DTR group was shorter than that in the RY group [(4.45 ± 1.18) d vs (6.0 ± 5.18) d, $P = 0.028$]. These results confirm the safety and feasibility of DTR, which has the same satisfactory postoperative recovery effect as RY. In general, the risk of DTR is the increase in the number of anastomotic stomas, which increases the probability of postoperative anastomotic complications[8,17]. However, in this study, the DTR group showed no anastomotic complications, whereas one patient in the RY group experienced duodenal stump leakage. Upper gastrointestinal angiography revealed an abnormal bile pancreatic branch intestinal loop, resulting in reverse peristalsis. This may have been caused by the food and digestive juice being unable to enter the jejunum food branch through the duodenal jejunum anastomosis, as well as the high pressure of the duodenal stump. Additionally, when postoperative input loop obstruction occurs because the duodenal stump is connected to the jejunum food branch, the digestive fluid can pass through the duodenal jejunum anastomosis, thereby reducing the pressure in the biliary and pancreatic branches and theoretically reducing the probability of serious complications of input loop obstruction[8].

Although there was no significant difference in body weight, hemoglobin, prealbumin, and albumin between the two groups at 1, 3, and 6 months after operation, the hemoglobin, prealbumin, and albumin levels in the DTR group were higher than those in the RY group at 1, 3, and 6 months after the operation. During the 6-month follow-up, the food intake ratio of the DTR group was also significantly better than that of the RY group ($P = 0.031$). Some studies have suggested that DTR has better food reserve function after gastrectomy, which may influence food intake, which is consistent with our results[8,18]. Additionally, there was no significant difference in body weight, hemoglobin, prealbumin, and albumin levels, which may be related to our short follow-up time and small sample size.

In this study, the symptoms of acid reflux and heartburn in the DTR group were significantly lower than those in the RY group ($P = 0.033$). Previous reports have confirmed that RY can effectively prevent reflux esophagitis[19,20], but some patients still exhibit severe reflux heartburn symptoms after surgery. In our follow-up of 31 patients with RY, 20 (64.5%) had reflux heartburn symptoms, including six (19.3%) that were Visick grade III, which is similar to the results of Chen *et*

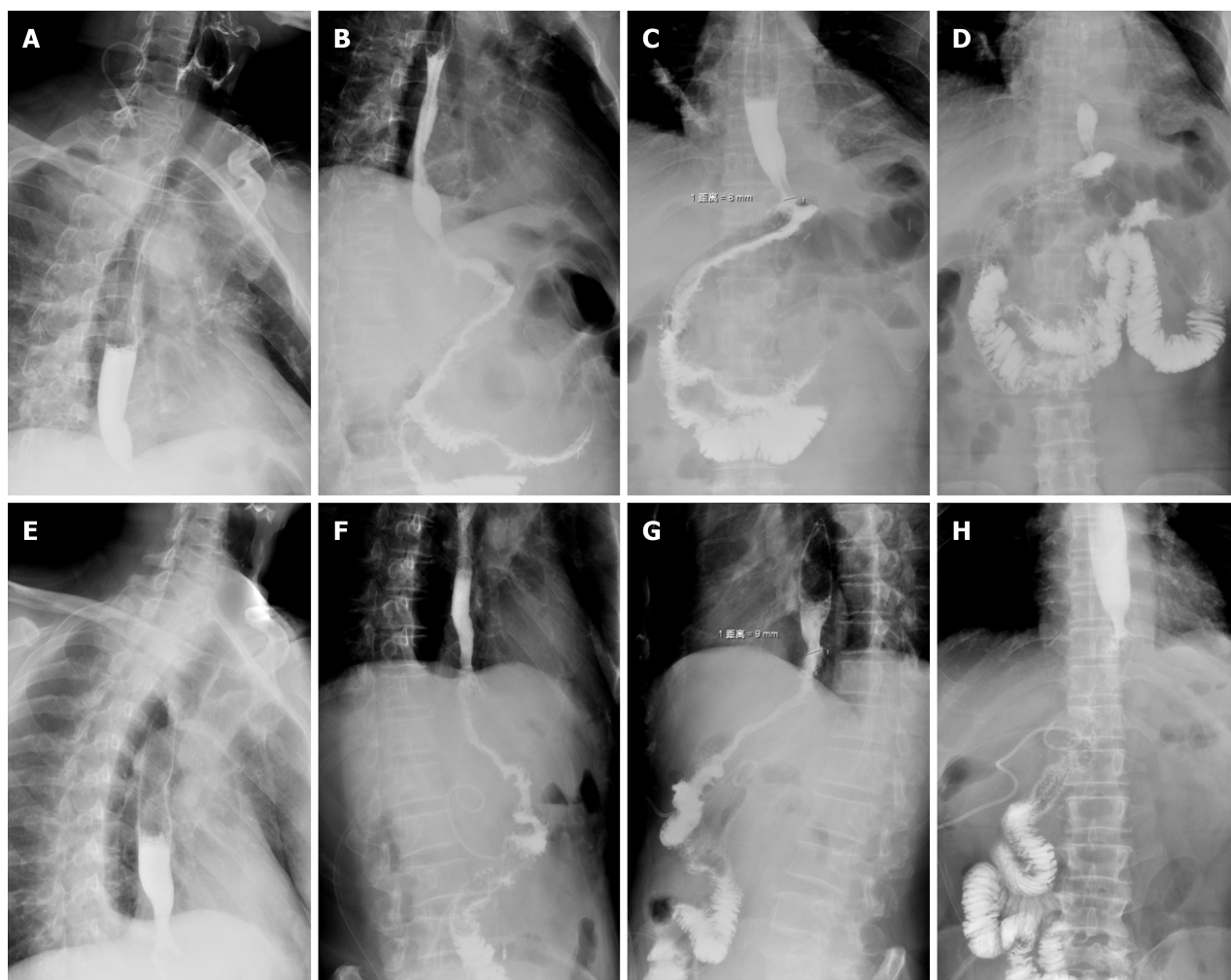


Figure 4 Postoperative angiography of the two groups of patients. A-D: Double-tract reconstruction: Imaging of contrast agent in esophagus (A), the contrast agent passed through the esophagojejunal anastomosis smoothly (B), the contrast agent successfully passed through the duodenal jejunum anastomosis (C), and imaging of contrast agent in distal jejunum (D); E-H: Roux-en-Y reconstruction: Imaging of contrast agent in esophagus (E), the contrast agent passed through the esophagojejunal anastomosis smoothly (F), imaging of contrast agent in proximal jejunum (G), and imaging of contrast agent in distal jejunum (H).

al's study[21]. Reflux heartburn symptoms not only affect the quality of life of patients after surgery but also affect the patient's food intake, indirectly leading to a decline in patient weight[7]. In the DTR group, alkaline digestive juice can flow into the jejunum food branch when reflux occurs due to the presence of dual pathway. Moreover, the length of our interposed small intestine is approximately 35 cm, which will also effectively reduce the occurrence of this complication [14,22].

The incidence of gallbladder disease in patients after RY is generally higher than that in other patients because food does not pass through the duodenum and lacks the stimulation of food to bile secretion[23]. In our study, the incidence of postoperative gallbladder disease in patients with DTR was 6.5%, while the probability of gallbladder disease in the RY group was 25.8%. Additionally, there was a significant difference between the two groups, which was consistent with previous research results[23]. Once gallbladder disease occurs in patients undergoing RY, due to the exclusion of the duodenal pathway, it will be difficult for the endoscope to enter the biliary system for examination or treatment; at this point, only invasive operation or surgery can be used for treatment[22,24]. Therefore, when performing digestive tract reconstruction, it is important to consider the needs of endoscopy, and DTR meets this requirement[8]. Some studies have shown that the preservation of the duodenal pathway also has a positive effect on the long-term prognosis of patients[19, 25-27].

CONCLUSION

In summary, although DTR has a slight increase in operation time, this does not impact the patient's postoperative recovery and the incidence of anastomotic-related complications. It can also improve the quality of life of patients after surgery, improve postoperative nutritional status, and reduce the incidence of gallbladder disease. Simultaneously, it can also provide a duodenal pathway for endoscopic retrograde cholangio pancreatography. Although we demonstrate that DTR is a better digestive tract reconstruction method than traditional RY, the limitations of this study include the small

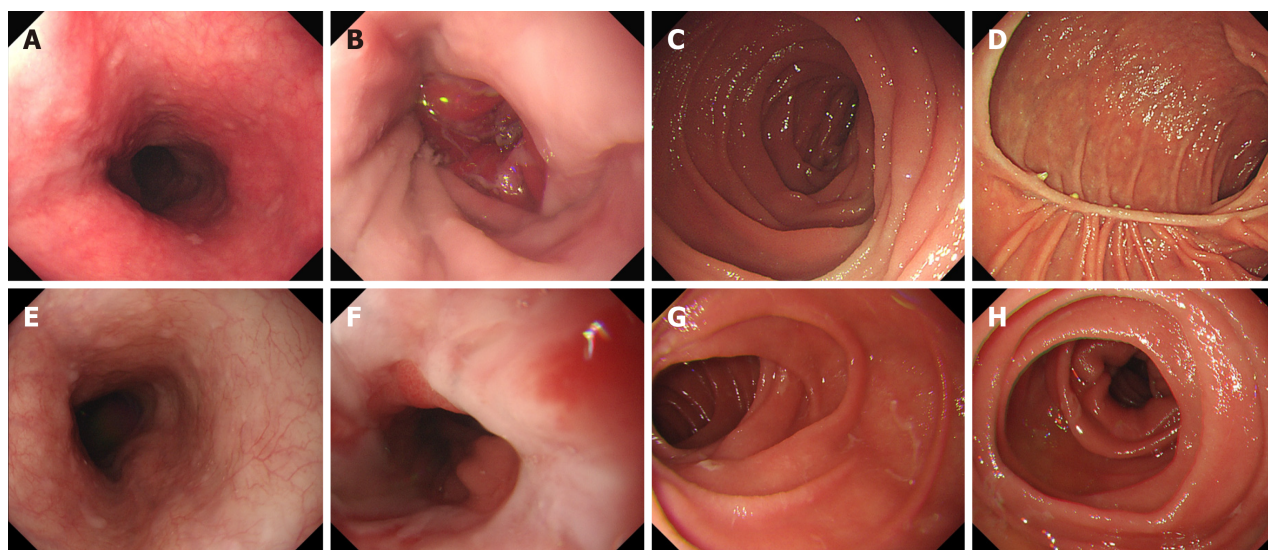


Figure 5 Postoperative gastroscopy results of the two groups of patients. A-D: Double-tract reconstruction: Image of esophagus under gastroscopy (A), image of esophagojejunal anastomosis under gastroscopy (B), image of proximal jejunum under gastroscopy (C), and image of duodenal jejunum anastomosis under gastroscopy (D); E-H: Roux-en-Y reconstruction: Image of esophagus under gastroscopy (E), image of esophagojejunal anastomosis under gastroscopy (F), image of proximal jejunum under gastroscopy (G), and image of distal jejunum under gastroscopy (H).

sample size, the short postoperative follow-up time, and the lack of further analysis of anemia indicators such as vitamin B12 and ferritin. In addition, prospective studies are still needed for comparative analysis.

FOOTNOTES

Author contributions: Wang D contributed to the conception and design; Wang D and Zhao Q contributed to the provision of study materials or patients; Dong TX and Ding PA contributed to the collection and assembly of data, data analysis and interpretation; all authors contributed to the manuscript writing and final approval of manuscript.

Supported by 2024 Government-funded Clinical Medicine Talent Project, No. ZF2024122.

Institutional review board statement: This study was reviewed and approved for publication by the Medical Ethics Committee of the Fourth Hospital of Hebei Medical University, No. 2022KY136.

Informed consent statement: Patients were not required to give informed consent to the study because the analysis used anonymous clinical data that were obtained after each patient agreed to treatment by written consent.

Conflict-of-interest statement: All the Authors have no conflict of interest related to the manuscript.

Data sharing statement: The original anonymous dataset is available on request from the corresponding author at 15833981527@163.com.

Open-Access: This article is an open-access article that was selected by an in-house editor and fully peer-reviewed by external reviewers. It is distributed in accordance with the Creative Commons Attribution NonCommercial (CC BY-NC 4.0) license, which permits others to distribute, remix, adapt, build upon this work non-commercially, and license their derivative works on different terms, provided the original work is properly cited and the use is non-commercial. See: <https://creativecommons.org/licenses/by-nc/4.0/>

Country/Territory of origin: China

ORCID number: Tian-Xiang Dong 0009-0001-2793-4394; Dong Wang 0009-0006-4764-4251; Qun Zhao 0000-0003-1603-3002; Zhi-Dong Zhang 0000-0002-1805-407X; Xue-Feng Zhao 0000-0003-4514-9899; Pei-Gang Yang 0000-0002-1055-4125; Ping-An Ding 0000-0002-8163-0711; Yong Li 0000-0002-2592-5128.

S-Editor: Yan JP

L-Editor: A

P-Editor: Xu ZH

REFERENCES

- 1 Stegnyy KV, Maslyantsev EV, Goncharuk RA, Krekoten AA, Kulakova TA, Dvoynikova ER. Double-tract reconstruction for oesofagocardial gastric cancer: A systematic review. *Ann Med Surg (Lond)* 2021; **67**: 102496 [PMID: 34194733 DOI: 10.1016/j.amsu.2021.102496]
- 2 Yun L, Zhiwei J, Junsheng P, Xiaobin W, Cancan X, Jieshou L. Comparison of Functional Outcomes between Functional Jejunal Interposition and Conventional Roux-en-Y Esophagojejunostomy after Total Gastrectomy for Gastric Cancer. *Dig Surg* 2020; **37**: 240-248 [PMID: 31614348 DOI: 10.1159/000501677]
- 3 Chen Y, Zheng T, Chen Y, Zheng Y, Tan S, Liu S, Zhou Y, Lin X, Chen W, Mi Y, Lin S, Yang C, Li W. Totally laparoscopic total gastrectomy with Uncut Roux-en-Y for gastric cancer may improve prognosis: A propensity score matching comparative study. *Front Oncol* 2022; **12**: 1086966 [PMID: 36620551 DOI: 10.3389/fonc.2022.1086966]
- 4 Liu F, Huang C, Xu Z, Su X, Zhao G, Ye J, Du X, Huang H, Hu J, Li G, Yu P, Li Y, Suo J, Zhao N, Zhang W, Li H, He H, Sun Y; Chinese Laparoscopic Gastrointestinal Surgery Study (CLASS) Group. Morbidity and Mortality of Laparoscopic vs Open Total Gastrectomy for Clinical Stage I Gastric Cancer: The CLASS02 Multicenter Randomized Clinical Trial. *JAMA Oncol* 2020; **6**: 1590-1597 [PMID: 32815991 DOI: 10.1001/jamaoncol.2020.3152]
- 5 Umemura A, Koeda K, Sasaki A, Fujiwara H, Kimura Y, Iwaya T, Akiyama Y, Wakabayashi G. Totally laparoscopic total gastrectomy for gastric cancer: literature review and comparison of the procedure of esophagojejunostomy. *Asian J Surg* 2015; **38**: 102-112 [PMID: 25458736 DOI: 10.1016/j.asjsur.2014.09.006]
- 6 Zhao Y, Zhang J, Yang D, Tang Z, Wang Q. Feasibility of laparoscopic total gastrectomy for advanced Siewert type II and type III esophagogastric junction carcinoma: A propensity score-matched case-control study. *Asian J Surg* 2019; **42**: 805-813 [PMID: 30685144 DOI: 10.1016/j.asjsur.2018.12.014]
- 7 Ikeguchi M, Kuroda H, Saito H, Tatebe S, Wakatsuki T. A new pouch reconstruction method after total gastrectomy (pouch-double tract method) improved the postoperative quality of life of patients with gastric cancer. *Langenbecks Arch Surg* 2011; **396**: 777-781 [PMID: 21448726 DOI: 10.1007/s00423-011-0779-6]
- 8 Hong J, Wang SY, Hao HK. A Comparative Study of Double-Tract Reconstruction and Roux-en-Y After Gastrectomy for Gastric Cancer. *Surg Laparosc Endosc Percutan Tech* 2019; **29**: 82-89 [PMID: 30720693 DOI: 10.1097/SLE.0000000000000639]
- 9 Kim JJ, Song KY, Chin HM, Kim W, Jeon HM, Park CH, Park SM. Totally laparoscopic gastrectomy with various types of intracorporeal anastomosis using laparoscopic linear staplers: preliminary experience. *Surg Endosc* 2008; **22**: 436-442 [PMID: 17593437 DOI: 10.1007/s00464-007-9446-y]
- 10 Chen Z, Wang D, Zhao Q, Yang P, Ding P, Fan H, Dong T, Liu Z, Yang X, Ren L, Li Y. A case series of 10 patients undergone linear cutter/stapler guiding device-led overlapped esophagojejunostomy: a preliminary study. *J Gastrointest Oncol* 2023; **14**: 617-625 [PMID: 37201061 DOI: 10.21037/jgo-23-193]
- 11 Uyama I, Sugioka A, Fujita J, Komori Y, Matsui H, Hasumi A. Laparoscopic total gastrectomy with distal pancreatectomy and D2 lymphadenectomy for advanced gastric cancer. *Gastric Cancer* 1999; **2**: 230-234 [PMID: 11957104 DOI: 10.1007/s101200050069]
- 12 Zhao S, Zheng K, Zheng JC, Hou TT, Wang ZN, Xu HM, Jiang CG. Comparison of totally laparoscopic total gastrectomy and laparoscopic-assisted total gastrectomy: A systematic review and meta-analysis. *Int J Surg* 2019; **68**: 1-10 [PMID: 31189084 DOI: 10.1016/j.ijsu.2019.05.020]
- 13 Syn NL, Wee I, Shabbir A, Kim G, So JB. Pouch Versus No Pouch Following Total Gastrectomy: Meta-analysis of Randomized and Non-randomized Studies. *Ann Surg* 2019; **269**: 1041-1053 [PMID: 31082900 DOI: 10.1097/SLA.0000000000003082]
- 14 Li Z, Dong J, Huang Q, Zhang W, Tao K. Comparison of three digestive tract reconstruction methods for the treatment of Siewert II and III adenocarcinoma of esophagogastric junction: a prospective, randomized controlled study. *World J Surg Oncol* 2019; **17**: 209 [PMID: 31810484 DOI: 10.1186/s12957-019-1762-x]
- 15 Burm AG, van Kleef JW, Gladines MP, van Duinen M, Spierdijk J. Spinal anesthesia with hyperbaric lidocaine and bupivacaine: effects of epinephrine on the plasma concentration profiles. *Anesth Analg* 1987; **66**: 1104-1108 [PMID: 3662055]
- 16 Uyama I, Sugioka A, Fujita J, Komori Y, Matsui H, Hasumi A. Completely laparoscopic proximal gastrectomy with jejunal interposition and lymphadenectomy. *J Am Coll Surg* 2000; **191**: 114-119 [PMID: 10898192 DOI: 10.1016/s1072-7515(00)00283-0]
- 17 Ji X, Jin C, Ji K, Zhang J, Wu X, Jia Z, Bu Z, Ji J. Double Tract Reconstruction Reduces Reflux Esophagitis and Improves Quality of Life after Radical Proximal Gastrectomy for Patients with Upper Gastric or Esophagogastric Adenocarcinoma. *Cancer Res Treat* 2021; **53**: 784-794 [PMID: 33421979 DOI: 10.4143/crt.2020.1064]
- 18 Liu YH, Meng R, Zhu B, Zhan QQ, Yang X, Ding GY, Jia CL, Xu WG. A meta-analysis of the efficacy of Roux-en-Y anastomosis and jejunal interposition after total gastrectomy. *World J Surg Oncol* 2023; **21**: 136 [PMID: 37098553 DOI: 10.1186/s12957-023-03002-z]
- 19 Iwahashi M, Nakamori M, Nakamura M, Naka T, Ojima T, Iida T, Katsuda M, Ueda K, Yamaue H. Evaluation of double tract reconstruction after total gastrectomy in patients with gastric cancer: prospective randomized controlled trial. *World J Surg* 2009; **33**: 1882-1888 [PMID: 19548028 DOI: 10.1007/s00268-009-0109-0]
- 20 Fan KX, Xu ZF, Wang MR, Li DT, Yang XS, Guo J. Outcomes for jejunal interposition reconstruction compared with Roux-en-Y anastomosis: A meta-analysis. *World J Gastroenterol* 2015; **21**: 3093-3099 [PMID: 25780310 DOI: 10.3748/wjg.v21.i10.3093]
- 21 Chen W, Jiang X, Huang H, Ding Z, Li C. Jejunal pouch reconstruction after total gastrectomy is associated with better short-term absorption capacity and quality of life in early-stage gastric cancer patients. *BMC Surg* 2018; **18**: 63 [PMID: 30126403 DOI: 10.1186/s12893-018-0397-0]
- 22 Xiao JW, Liu ZL, Ye PC, Luo YJ, Fu ZM, Zou Q, Wei SJ. Clinical comparison of antrum-preserving double tract reconstruction vs roux-en-Y reconstruction after gastrectomy for Siewert types II and III adenocarcinoma of the esophagogastric junction. *World J Gastroenterol* 2015; **21**: 9999-10007 [PMID: 26379405 DOI: 10.3748/wjg.v21.i34.9999]
- 23 Ikegame K, Hikage M, Fujiya K, Kamiya S, Tanizawa Y, Bando E, Terashima M. The Effect of Minimally Invasive Gastrectomy for Gastric Cancer on Postoperative Gallstone Formation. *World J Surg* 2021; **45**: 3378-3385 [PMID: 34389897 DOI: 10.1007/s00268-021-06270-6]
- 24 Namikawa T, Kitagawa H, Okabayashi T, Sugimoto T, Kobayashi M, Hanazaki K. Double tract reconstruction after distal gastrectomy for gastric cancer is effective in reducing reflux esophagitis and remnant gastritis with duodenal passage preservation. *Langenbecks Arch Surg* 2011; **396**: 769-776 [PMID: 21448727 DOI: 10.1007/s00423-011-0777-8]
- 25 Ishigami S, Natsugoe S, Hokita S, Aoki T, Kashiwagi H, Hirakawa K, Sawada T, Yamamura Y, Itoh S, Hirata K, Ohta K, Mafune K, Nakane Y, Kanda T, Furukawa H, Sasaki I, Kubota T, Kitajima M, Aikou T. Postoperative long-term evaluation of interposition reconstruction

compared with Roux-en-Y after total gastrectomy in gastric cancer: prospective randomized controlled trial. *Am J Surg* 2011; **202**: 247-253 [PMID: [21871978](#) DOI: [10.1016/j.amjsurg.2011.04.004](#)]

- 26 **Ogoshi K**, Okamoto Y, Nabeshima K, Morita M, Nakamura K, Iwata K, Soeda J, Kondoh Y, Makuuchi H. Focus on the conditions of resection and reconstruction in gastric cancer. What extent of resection and what kind of reconstruction provide the best outcomes for gastric cancer patients? *Digestion* 2005; **71**: 213-224 [PMID: [16024924](#) DOI: [10.1159/000087046](#)]
- 27 **Hu Y**, Zaydfudim VM. Quality of Life After Curative Resection for Gastric Cancer: Survey Metrics and Implications of Surgical Technique. *J Surg Res* 2020; **251**: 168-179 [PMID: [32151826](#) DOI: [10.1016/j.jss.2020.02.005](#)]



Published by **Baishideng Publishing Group Inc**
7041 Koll Center Parkway, Suite 160, Pleasanton, CA 94566, USA

Telephone: +1-925-3991568

E-mail: office@baishideng.com

Help Desk: <https://www.f6publishing.com/helpdesk>

<https://www.wjgnet.com>

