



Retrospective Cohort Study

## Clinical profile and outcomes of hepatocellular carcinoma in primary Budd-Chiari syndrome

Ankit Agarwal, Sagnik Biswas, Shekhar Swaroop, Arnav Aggarwal, Ayush Agarwal, Gautam Jain, Anshuman Elhence, Arun Vaidya, Amit Gupte, Ravi Mohanka, Ramesh Kumar, Ashwani Kumar Mishra, Shivanand Gamanagatti, Shashi Bala Paul, Subrat Kumar Acharya, Akash Shukla, Shalimar

**Specialty type:** Gastroenterology and hepatology

**Provenance and peer review:** Invited article; Externally peer reviewed.

**Peer-review model:** Single blind

**Peer-review report's scientific quality classification**

Grade A (Excellent): 0  
Grade B (Very good): 0  
Grade C (Good): C, C  
Grade D (Fair): 0  
Grade E (Poor): 0

**P-Reviewer:** Niu XK, China; Rong GH, China

**Received:** October 3, 2023

**Peer-review started:** October 3, 2023

**First decision:** December 5, 2023

**Revised:** December 22, 2023

**Accepted:** January 16, 2024

**Article in press:** January 16, 2024

**Published online:** March 15, 2024



**Ankit Agarwal, Sagnik Biswas, Shekhar Swaroop, Arnav Aggarwal, Ayush Agarwal, Anshuman Elhence, Subrat Kumar Acharya, Shalimar,** Department of Gastroenterology and Human Nutrition, All India Institute of Medical Sciences, New Delhi 110029, Delhi, India

**Gautam Jain, Arun Vaidya, Akash Shukla,** Department of Gastroenterology, Seth Gordhandas Sunderdas Medical College and KEM Hospital, Mumbai 400012, Maharashtra, India

**Amit Gupte,** Department of Gastroenterology, Sir HN Reliance Foundation Hospital, Mumbai 400004, India

**Ravi Mohanka,** Department of Liver Transplant and HPB, Sir HN Reliance Foundation Hospital, Mumbai 400004, India

**Ramesh Kumar,** Department of Gastroenterology, All India Institute of Medical Sciences, Patna 801507, India

**Ashwani Kumar Mishra,** Professor of Biostatistics, National Drug Dependence Treatment Centre (NDDTC), All India Institute of Medical Sciences, New Delhi 110029, India

**Shivanand Gamanagatti, Shashi Bala Paul,** Department of Radiodiagnosis, All India Institute of Medical Sciences, New Delhi 110029, Delhi, India

**Corresponding author:** Shalimar, MD, Professor, Department of Gastroenterology and Human Nutrition, All India Institute of Medical Sciences, Sri Aurobindo Marg, Ansari Nagar, New Delhi 110029, Delhi, India. [drshalimar@yahoo.com](mailto:drshalimar@yahoo.com)

### Abstract

#### BACKGROUND

There is scant literature on hepatocellular carcinoma (HCC) in patients with Budd-Chiari syndrome (BCS).

#### AIM

To assess the magnitude, clinical characteristics, feasibility, and outcomes of treatment in BCS-HCC.

#### METHODS

A total of 904 BCS patients from New Delhi, India and 1140 from Mumbai, India were included. The prevalence and incidence of HCC were determined, and among patients with BCS-HCC, the viability and outcomes of interventional therapy were evaluated.

## RESULTS

In the New Delhi cohort of 35 BCS-HCC patients, 18 had HCC at index presentation (prevalence 1.99%), and 17 developed HCC over a follow-up of 4601 person-years, [incidence 0.36 (0.22-0.57) per 100 person-years]. BCS-HCC patients were older when compared to patients with BCS alone ( $P = 0.001$ ) and had a higher proportion of inferior vena cava block, cirrhosis, and long-segment vascular obstruction. The median alpha-fetoprotein level was higher in patients with BCS-HCC at first presentation than those who developed HCC at follow-up (13029 ng/mL *vs* 500 ng/mL,  $P = 0.01$ ). Of the 35 BCS-HCC, 26 (74.3%) underwent radiological interventions for BCS, and 22 (62.8%) patients underwent treatment for HCC [transarterial chemoembolization in 18 (81.8%), oral tyrosine kinase inhibitor in 3 (13.6%), and transarterial radioembolization in 1 (4.5%)]. The median survival among patients who underwent interventions for HCC compared with those who did not was 3.5 years *vs* 3.1 mo ( $P = 0.0001$ ). In contrast to the New Delhi cohort, the Mumbai cohort of BCS-HCC patients were predominantly males, presented with a more advanced HCC [Barcelona Clinic Liver Cancer C and D], and 2 patients underwent liver transplantation.

## CONCLUSION

HCC is not uncommon in patients with BCS. Radiological interventions and liver transplantation are feasible in select primary BCS-HCC patients and may improve outcomes.

**Key Words:** Budd chiari syndrome; Cancer; Cirrhosis; Thrombosis; Liver; Varices; Transarterial chemoembolization; Hepatic venous outflow tract obstruction

©The Author(s) 2024. Published by Baishideng Publishing Group Inc. All rights reserved.

**Core Tip:** Hepatocellular carcinoma is not uncommon in patients with Budd-Chiari syndrome. It may be the presenting feature or may develop later during illness. Early diagnosis and intervention are the keys to improving outcomes. Strategies for surveillance include serial alpha-fetoprotein and ultrasound assessment every 6 mo with biopsy in cases with high clinical suspicion. Endovascular intervention, which improves liver functions, is usually done prior to therapy for hepatocellular carcinoma. Liver transplantation and surgical resection have curative potential, while locoregional therapy may be offered to a select group with more advanced disease, which improves outcomes in these patients.

**Citation:** Agarwal A, Biswas S, Swaroop S, Aggarwal A, Agarwal A, Jain G, Elhence A, Vaidya A, Gupte A, Mohanka R, Kumar R, Mishra AK, Gamanagatti S, Paul SB, Acharya SK, Shukla A, Shalimar. Clinical profile and outcomes of hepatocellular carcinoma in primary Budd-Chiari syndrome. *World J Gastrointest Oncol* 2024; 16(3): 699-715

**URL:** <https://www.wjgnet.com/1948-5204/full/v16/i3/699.htm>

**DOI:** <https://dx.doi.org/10.4251/wjgo.v16.i3.699>

## INTRODUCTION

Budd-Chiari syndrome (BCS) is characterized by obstruction of the hepatic venous outflow tract at any level from hepatic veins (HV) to the junction of the inferior vena cava (IVC) with the right atrium[1]. Prior to the turn of the century, hepatocellular carcinoma (HCC) was considered a rare event in the natural history of BCS[2]. The incidence of HCC in BCS patients varies between 2.0% to 51.6%[3]. Chronic vascular injury (hepatic congestion) has been postulated to contribute to the development of fibrosis and cirrhosis in BCS, resulting in dysplastic nodules and HCC. However, there remains uncertainty regarding the risk factors for HCC in BCS. Some studies have identified factors that might increase the risk of HCC in these patients, including male sex, cirrhosis, prolonged ischemia time, long segment IVC block, combined HV and IVC block, and duration of the BCS itself[4-9].

Multiple therapeutic options may be utilized to manage HCC, and the choice depends upon the stage of disease and the expertise of the treating center[10]. In a study by Gwon *et al*[11], 20 patients with HCC, who had membranous obstruction of IVC, underwent transarterial chemoembolization (TACE). The 3-year and 5-year survival rates were 61% and 46%, respectively, comparable to other etiologies of HCC. In another study by Liu *et al*[6], 14 patients underwent TACE, and 9 patients also had angioplasty for BCS. However, the chronology of angioplasty and intervention for HCC was not consistent across all the cases. It was performed with the first session of TACE in 5 patients and with the second session of TACE in the remaining 4 patients.

There is a paucity of data regarding the safety and efficacy of radiological interventions for HCC and BCS in patients with BCS-HCC. Also, it is unknown whether revascularization procedures can reduce the occurrence of new HCC and

improve the results of locoregional therapies for HCC. Multifocal disease and new HCC lesions over time further add to the complexity of management options. Therefore, in this study, we described the clinical presentations, radiological interventions employed for management, and the clinical outcomes of BCS-HCC patients.

## MATERIALS AND METHODS

All consecutive patients diagnosed with primary BCS-HCC between January 1987 and January 2023 at the All-India Institute of Medical Sciences, New Delhi, India were assessed for inclusion for this retrospective analysis from a prospectively maintained database. Patients with secondary BCS, insufficient baseline data, and inaccessible follow-up data were excluded. In addition, patients with other etiologies for HCC were also excluded. The institute ethics committee approved the study (IEC/NP-458/12.12.2014, RP-22/2015). Written informed consent was waived (de-identified data). We also included BCS-HCC patients diagnosed at King Edward Memorial Hospital, Mumbai, Maharashtra, India.

### Definitions

**BCS:** Diagnosis of BCS was made when the IVC and/or HV (two out of three major HV) showed thrombosis/stenosis on either ultrasound doppler/computed tomography (CT)/magnetic resonance venogram. The site of the venous block was based on the available imaging and categorized as either HV/IVC alone or combined. The obstruction of the vein was classified as either short segment (< 3 cm) or long segment (≥ 3 cm)[9].

**Cirrhosis:** Diagnosed based on a combination of clinical, biochemical, and imaging findings, endoscopy, or liver biopsy [12].

**HCC:** Standard diagnostic criteria accepted at the period were used. Prior to 2001, HCC was diagnosed based on either fine needle biopsy or by demonstrating a liver lesion enhancing on the arterial phase of a CT scan together with raised serum alpha-fetoprotein (AFP) ≥ 300 ng/mL. Subsequently, the European Association for the Study of the Liver guidelines were followed[13,14]. The European Association for the Study of the Liver guidelines for the diagnosis of HCC recommend considering HCC as every nodule > 1 cm with arterial phase hyperenhancement and washout on the portal venous phase on one of the two dynamic imaging techniques [CT scan or magnetic resonance imaging (MRI)] and to biopsy a nodule > 1 cm when the imaging is inconclusive.

**HCC at presentation:** When HCC was diagnosed at index presentation to our clinic in a previously unevaluated case or within 6 mo of diagnosis of BCS.

**HCC at follow-up:** It was defined as patient(s) who developed HCC after at least 6 mo after the diagnosis of BCS.

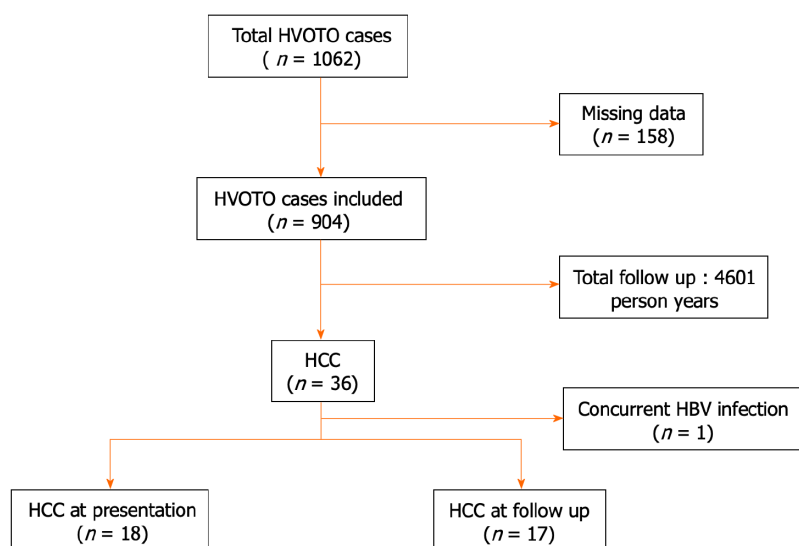
### Management protocol for BCS

**Angiographic interventions:** We have previously published our protocol for BCS management[15,16]. Our institutional policy is to offer the patients radiologic interventions upfront for decompression of hepatic vasculature, followed by management of HCC. In patients with focal obstruction of the IVC and/or HV, revascularization of the occluded segment was performed by angioplasty using balloon dilatation attempted *via* the transjugular or transfemoral route. Stenting of these focal obstructions was performed if there was residual stenosis or persistence of collaterals after balloon angioplasty. Patients with combined IVC and HV occlusion underwent angioplasty/stenting of both segments. Transjugular intrahepatic portosystemic shunt (TIPSS) was performed in patients with long-segment/diffuse involvement of all three HVs.

**Anticoagulation protocol:** Patients subjected to radiological interventions for BCS were anticoagulated initially with heparin infusion overlapping with oral anticoagulants (vitamin K antagonists). The dose of oral anticoagulants was titrated to maintain the international normalized ratio between 2.0 and 2.5. The underlying hypercoagulable state was managed in consultation with hematologists.

### Management protocol for HCC

The management plan was decided by a multidisciplinary team, including a hepatologist, interventional radiologist, and liver transplant surgeon. Staging and treatment allocation in each HCC patient was completed per the Barcelona Clinic Liver Cancer (BCLC) staging classification, wherever applicable[10,17]. Response to treatment of HCC was assessed by the modified response evaluation criteria in solid tumors (mRECIST) on multiphasic CT/MRI[18]. For patients diagnosed with HCC prior to the publication of the BCLC and mRECIST criteria, their data was retrospectively analyzed to identify which BCLC class they belonged to as well as the radiological response after therapy. Subsequent radiological interventions were decided according to the clinical and radiological response. Surveillance with AFP in patients with HCC has been recommended by the expert guidelines. Our cohort dates to 1985 (19 years prior to the randomized controlled trial recommending surveillance), and hence the routine implementation of AFP or surveillance was not available for all patients. This may also have a potential impact on the survival estimates provided and is a limitation of the retrospective nature of our data.



**Figure 1 Risk of hepatocellular carcinoma in patients with Budd-Chiari syndrome.** HBV: Hepatitis B virus; HCC: Hepatocellular carcinoma; HVOTO: Hepatic venous outflow tract obstruction.

### Follow-up schedule

A Doppler ultrasound was conducted on the day after the procedure in each case and repeated 3 mo thereafter or when required (clinical/biochemical worsening) to assess for restenosis. In cases where the patency of the veins could not be confidently ascertained by Doppler or an intrahepatic mass was suspected, a multiphasic CT/MRI was done.

Stent block was defined when the stent in IVC/HV showed thrombosis/stenosis. Time to restenosis was calculated by calculating the number of days between the diagnosis of the stent block and the initial intervention for BCS.

Total follow-up days were determined by calculating the number of days between the date of the first outpatient visit and the date of death or the last follow-up. Patients who were lost to follow-up were contacted by telephone, and the follow-up was updated; otherwise, the date of the last outpatient visit was considered as the last follow-up.

### Data collection

All clinical records, including the details of BCS, HCC, and management were retrieved from the electronic database. Data about clinical presentation and the following parameters were collected: hematological/biochemical tests (complete blood count, liver function tests, and kidney function tests) and serum AFP. Details of viral serology, including hepatitis B surface antigen, anti-hepatitis C virus (HCV) antibodies, tests for Wilson's disease, autoimmune markers, and serum ferritin were noted.

### Statistical analysis

Continuous data were expressed as mean, standard deviation for non-skewed and median (interquartile range) for skewed data and were compared among groups using Student's *t*-test/Mann-Whitney *U* test, as appropriate. Categorical data were expressed as proportions and were compared using the  $\chi^2$  test/Fisher's exact test, as appropriate. Kaplan-Meier survival curve analysis was used to calculate the median survival of HCC among BCS patients in this study by using the available follow-up of each patient and compared using the log-rank test. A  $P < 0.05$  was statistically significant. The data was analyzed using the IBM SPSS Statistics software (version 25.0, Chicago, IL, United States) and MedCalc Software (version 15.11.4, MedCalc Software, Ostend, Belgium).

## RESULTS

Of the total 1062 BCS patients initially evaluated, 904 were included in the final analysis after exclusion of 158 patients with missing data. Overall, 35 out of 904 (3.8%) had primary BCS-HCC (Figure 1). Of the 35 BCS-HCC patients, 19 (54.3%) were females. The proportions of patients in Child Turcotte Pugh (CTP) classes A, B, and C were 21 (60.0%), 11 (31.4%), and 3 (8.5%), respectively. Complete etiological evaluation for hypercoagulable states was available in 11 patients with BCS-HCC. However, none of the markers were found to be positive.

### Prevalence and incidence of HCC

Of the 35 HCC patients, 18 had HCC at presentation [prevalence 18/904 (1.9%)] and 17 developed HCC (among 886) over a follow-up of 4601 person-years with an incidence of 0.36 (0.22-0.57) per 100 person-years. The cumulative incidence of HCC during the follow-up period was assessed after the exclusion of the 18 patients who had HCC at presentation.

### Comparison of baseline characteristics of BCS patients with and without HCC

BCS-HCC patients ( $n = 35$ ), when compared to those with BCS alone ( $n = 869$ ), were older (median age 32 years *vs* 26 years,  $P = 0.001$ ) and had a higher prevalence of IVC block [7/35 (20.0%) *vs* 50/869 (5.7%),  $P = 0.02$ ], cirrhosis [35/35 (100%) *vs* 716/869 (82.4%),  $P = 0.006$ ], and long-segment vascular obstruction [27/35 (77.1%) *vs* 429/869 (49.4%),  $P = 0.001$ ] (Table 1).

**Table 1** Baseline characteristics of patients having Budd-Chiari syndrome with and without hepatocellular carcinoma

Characteristic	Overall population, $n = 904$	BCS w/o HCC, $n = 869$	BCS-HCC, $n = 35$	<i>P</i> value
Age in yr at first presentation	26 (21-33)	26 (20-33)	32 (25-40)	0.001
Duration of symptoms in month	12 (4-36)	12 (4-36)	3 (2-24)	< 0.001
Male sex	496 (54.87)	480 (55.24)	16 (45.71)	0.270
Site of block				
Inferior vena cava	57 (6.31)	50 (5.75)	7 (20.00)	0.020
Hepatic vein	398 (44.03)	388 (44.65)	10 (28.57)	
Combined inferior vena cava and hepatic vein	449 (49.67)	431 (49.60)	18 (51.43)	
Type of block, BCS				
Short segment	448 (49.56)	440 (50.63)	8 (22.86)	0.001
Long segment	456 (50.44)	429 (49.37)	27 (77.14)	
Child class				
A	420 (46.46)	399 (45.91)	21 (60.00)	0.050
B	260 (28.76)	249 (28.65)	10 (28.57)	
C	71 (7.85)	68 (7.83)	4 (11.40)	
Cirrhosis	751 (83.08)	716 (82.39)	35 (100.00)	0.006
Pain in abdomen	335 (37.06)	321 (36.94)	14 (40.00)	0.710
Ascites	679 (75.11)	658 (75.72)	21 (60.00)	0.035
Gastrointestinal bleeding	195 (21.57)	189 (21.75)	6 (17.14)	0.510
Jaundice	200 (22.12)	190 (21.86)	10 (28.57)	0.340
Hepatic encephalopathy at presentation	35 (3.87)	34 (3.91)	1 (2.86)	0.750
Hemoglobin in g/dL	11.7 (9.9-13.4)	11.7 (9.9-13.4)	10.7 (9.2-12.8)	0.150
Total leucocyte count as /mm <sup>3</sup>	5560 (3850-7500)	5600 (3880-7550)	3800 (4600-6900)	0.310
Platelet count as $\times 10^3$ /mm <sup>3</sup>	151 (110-219)	152 (110-225)	130 (75-161)	0.006
Creatinine in mg/dL	0.7 (0.6-0.9)	0.7 (0.6-0.9)	0.7 (0.6-0.9)	0.330
Total bilirubin in mg/dL	1.5 (0.9-2.4)	1.5 (0.9-2.4)	1.7 (1.0-2.3)	0.310
Aspartate transaminase in IU/L	42 (32-63)	42 (31-62)	59 (35-80)	0.008
Alanine transaminase in IU/L	31 (22-47)	31 (22-47)	46 (27-65)	0.010
Albumin in g/dL	3.9 (3.3-4.5)	3.9 (3.3-4.5)	4.2 (2.9-4.6)	0.620
Alkaline phosphatase in IU/L	250.0 (159-372)	250.5 (160.0-372.0)	239.0 (148-314)	0.820
Alpha-fetoprotein	3.3 (2.1-9.6)	2.9 (1.9-4.3)	1310.0 (237.0-14308.0)	< 0.001
BCS intervention received	654 (72.34)	628 (72.26)	26 (74.28)	0.189
Inferior vena cava	317 (35.06)	302 (34.70)	15 (42.8)	
Hepatic vein	106 (11.72)	102 (11.73)	4 (11.42)	
TIPSS	198 (21.90)	194 (22.32)	4 (11.42)	
IVC + HV	28 (3.09)	26 (2.90)	2 (5.70)	

PSRS	5 (0.50)	4 (0.46)	1 (2.80)	
Stent block	159/654 (24.31)	151/637 (23.70)	8/17 (47.05)	0.063
Time to restenosis in d	496.0 (181.0-1253.0)	496.0 (18.0-1198.0)	692.5 (226.5-1540.0)	0.550
Follow-up in d	1249.5 (503.5-2573.0)	1248.0 (530.0-2513.0)	1307.0 (158.0-3811.0)	0.530

Data are *n* (%) or median (interquartile range) or *n* (%). BCS: Budd-Chiari syndrome; HCC: Hepatocellular carcinoma; HV: Hepatic vein; IVC: Inferior vena cava; PSRS: Proximal splenorenal shunt; TIPSS: Transjugular intrahepatic portosystemic shunt.

BCS-HCC patients, compared to those without HCC, had higher aspartate aminotransaminase and alanine aminotransferase levels. The platelet counts were lower among those with BCS-HCC. Ascites was more frequent in patients without HCC than those with HCC (75.7% *vs* 60.0%,  $P = 0.035$ ). There were no significant differences in other clinical and biochemical parameters (Table 1).

Of the 906 patients with BCS, 676 (74.6%) patients underwent radiological interventions. Data for stent block was available for 654/676 (96.7%) patients until the last follow-up. A total of 159/654 (24.3%) patients developed stent blocks and required reintervention for BCS. The BCS-HCC group had a higher, though statistically insignificant, proportion of stent block (restenosis) than the BCS alone group (47.05% *vs* 23.70%,  $P = 0.063$ ). The median time to restenosis was 692 d in the BCS-HCC group compared to 496 d in the BCS alone group ( $P = 0.55$ ).

### Comparison of BCS patients with HCC at presentation and HCC at follow-up

The BCS patients who developed HCC on follow-up were similar to those who presented with HCC (Table 2) in terms of age at onset of BCS, duration of symptoms, sex distribution, site of block, length of the block, presence of cirrhosis, and CTP class ( $P > 0.05$  for all). The median serum AFP levels in the BCS-HCC group were 1310 ng/mL, with higher levels in patients with BCS-HCC at first presentation compared to those who developed HCC during follow-up (13029 ng/mL *vs* 500 ng/mL,  $P = 0.01$ ). BCLC (A, B, C, and D) stages in patients developing HCC at follow-up compared to those at first presentation were 1 (5.8%), 10 (58.8%), 2 (11.7%), and 4 (23.5%) *vs* 4 (22.2%), 7 (38.8%), 7 (38.8%), and 0, respectively ( $P = 0.029$ ).

**Table 2** Baseline characteristics of patients having Budd-Chiari syndrome hepatocellular carcinoma at follow-up and at presentation

Characteristic	BCS-HCC on follow-up, <i>n</i> = 17	BCS-HCC at first presentation, <i>n</i> = 18	<i>P</i> value
Age in yr at onset of BCS	30.0 (24.0-40.0)	32.5 (26.0-38.0)	0.640
Duration of symptoms	3 (2-18)	3 (2-24)	0.880
Sex, males	9 (52.90)	7 (38.88)	0.880
Site of block			
Inferior vena cava	4 (23.50)	3 (16.67)	0.450
Hepatic vein	4 (23.50)	6 (33.33)	
Combined inferior vena cava and hepatic vein	9 (52.90)	9 (50.00)	
Type of block, BCS			
Short segment	4 (23.50)	4 (22.22)	0.370
Long segment	13 (76.40)	14 (77.78)	
Child class			
A	8 (47.1)	13 (72.22)	0.120
B	5 (29.40)	5 (27.78)	
C	4 (23.50)	0 (0)	
Pain in abdomen	7 (41.18)	7 (38.89)	0.890
Ascites	11 (64.71)	10 (55.56)	0.580
Gastrointestinal bleeding	2 (11.76)	4 (22.22)	0.660
Hepatic encephalopathy at presentation	1 (5.88)	0 (0)	0.490
Hemoglobin in g/dL	10.40 (8.50-11.50)	12.10 (9.75-13.90)	0.110
Total leucocyte count in	4300 (3500-6400)	4735 (4050-6950)	0.610



mm <sup>3</sup>			
Platelet count as $\times 10^3/\text{mm}^3$	101.0 (71.0-156.0)	150.0 (113.0-166.5)	0.210
Creatinine in mg/dL	0.7 (0.5-0.9)	0.7 (0.6-0.9)	0.550
Total bilirubin in mg/dL	1.8 (1.5-3.2)	1.5 (0.8-2.1)	0.160
Aspartate transaminase in IU/L	66.0 (46.0-120.0)	51.5 (35.0-76.0)	0.280
Alanine transaminase in IU/L	46.0 (27.0-59.0)	42.5 (28.0-66.0)	0.890
Albumin in g/dL	4.0 (2.9-4.7)	4.3 (3.3-4.5)	0.530
Alkaline phosphatase in IU/L	274.0 (178.0-394.0)	210.5 (143.0-300.0)	0.320
Alpha-fetoprotein in ng/mL	500.0 (66.6-1320.0)	13029.0 (500.0-17943.0)	0.010
Intervention received	14 (82.35)	12 (66.67)	0.170
Inferior vena cava angioplasty/stenting	9 (52.90)	6 (33.33)	
Hepatic vein angioplasty/stenting	2 (11.70)	2 (11.11)	
IVC + HV angioplasty/stenting	0	2 (11.11)	
TIPSS	2 (11.70)	2 (11.11)	
PSRS	1 (5.80)	0	
Barcelona Clinic Liver Cancer staging			0.029
A	1 (5.80)	4 (22.20)	
B	10 (58.80)	7 (38.80)	
C	2 (11.70)	7 (38.80)	
D	4 (23.50)	0	

Data are *n* (%) or median (interquartile range). BCS: Budd-Chiari syndrome; HCC: Hepatocellular carcinoma; HV: Hepatic vein; IVC: Inferior vena cava; PSRS: Proximal splenorenal shunt; TIPSS: Transjugular intrahepatic portosystemic shunt.

Of the 35 BCS-HCC patients, 26 (74.3%) underwent radiological interventions for BCS, and 22 (62.8%) patients underwent treatment for HCC (Table 2). Twelve (34.2%) BCS-HCC patients were not treated for HCC for various reasons including advanced stage of disease (*n* = 7), and refusal for treatment (*n* = 5). One patient is currently under evaluation and awaiting multidisciplinary discussion.

The initial interventions for HCC included TACE in 18/35 (51.4%) patients, oral tyrosine kinase inhibitor (TKI) in 3 (8.5%) patients and transarterial radioembolization (TARE) in 1 (2.8%) patient. The maximum number of interventions a patient required for HCC was five in 1 patient, with a median of one (range 1-5) per patient. mRECIST was assessed for patients who underwent interventions (TACE and TARE). The response at 1 mo based on mRECIST criteria was available in 15/19 (78.9%) cases. Of these 15 patients, 5 (33.3%) patients showed complete response, 6 (40.0%) patients showed partial response, and 4 (26.7%) patients had progressive disease. One patient died within 1 mo of TACE.

Median survival in those who underwent interventions for HCC was 3.5 years (Figure 2A). The median survival in patients as per BCLC stages A, B, C, and D was 172 d, 1352 d, 240 d, and 40 d, respectively (Figure 2B).

### Management of patients with BCS-HCC at first presentation

Two-thirds (12/18) of patients underwent endovascular intervention for BCS. Among them, 6 (33.3%) patients underwent IVC angioplasty, 2 (11.1%) patients each underwent HV angioplasty, combined IVC and HV angioplasty, and TIPSS (Table 3). The remaining 6 patients refused treatment. None of the patients had restenosis/stent block after the initial intervention for BCS.

All 12 who underwent BCS intervention also received therapy for HCC. Of these, 9 (75.0%) patients underwent TACE, 2 (16.6%) received oral TKIs, and 1 patient underwent TARE. Repeat sessions of locoregional therapy for HCC were done in 4 patients. The response at 1 mo based on mRECIST criteria was available for 7/10 (70%) patients. A partial response was seen in 4 (40%) patients, complete response in 1 patient, and progressive disease in 2 patients (1 patient received TKIs after progression). A total of 7 patients were alive at the last follow-up. The median duration of follow-up in those who underwent interventions was 201 d (39-500). The details of the patients are shown in Table 3.

A representative image of a patient with BCS-HCC pretreatment (Figure 3) and post-treatment (Figure 4) highlights the imaging findings and management of both BCS and HCC.

### Management of patients with BCS-HCC at follow-up

A total of 14/17 (82.3%) patients had undergone intervention for BCS. Nine (52.9%) patients had IVC angioplasty, 2 (11.7%) patients each underwent HV angioplasty and TIPSS, and 1 patient underwent a surgical proximal splenorenal

**Table 3 Management of patients with Budd-Chiari syndrome at first presentation**

Age	Sex	Site of obstruction	Length of block	BCS management	AFP	BCLC	CTP	HCC initial management	HCC response	Survival after HCC diagnosis in d	No. of lesions/size in cm	Reinterventions for HCC
35	M	IVC + HV	Long	IVC + HV angioplasty	115	A	A	TACE	PR	680	1 (10 cm × 10 cm)	1, TACE
38	F	HV	Long	HV angioplasty	239	B	A	TACE	PR	1656	2.0 (5.5 cm × 5.5 cm)	4, TACE, followed by TKI
37	M	IVC	Short	IVC angioplasty	17943	C (lung metastasis)	A	TACE	NA	39	1 (> 10 cm)	-
30	F	IVC	Short	IVC angioplasty	11430	B	A	TACE	PR	1280	2 (5.2 cm × 5.4 cm)	-
17	F	IVC + HV	Long	TIPSS	34930	B	A	TACE	PR	500	4 (4 cm × 5 cm)	2, TACE
38	F	HV	Long	Medical management	5905	C (PVT)	B	SC	NA	93	NA	-
52	M	HV	Long	Medical management	237	A	A	SC	NA	158	1.0 (1.6 cm × 1.8 cm)	-
22	F	IVC + HV	Long	Medical management	56804	C (PVT)	A	SC	NA	14	1 (11 cm × 11 cm)	-
48	M	HV	Long	Medical management	NA	A	A	SC	NA	5 <sup>1</sup>	1 (2.5 cm × 3.0 cm)	-
26	M	IVC + HV	Long	IVC angioplasty	15314	A	A	TACE	PD	172	1 (2.5 cm × 3.5 cm)	TKI
30	F	IVC + HV	Long	Medical management	31068	C (PVT)	B	TKI	NA	21 <sup>1</sup>	Infiltrative	-
63	M	IVC	Short	IVC angioplasty	20312	C (Rt. PVT)	A	TARE	NA	488 <sup>1</sup>	3 (> 5 cm)	-
32	F	IVC + HV	Long	IVC angioplasty	3153	B	A	TACE	CR	229 <sup>1</sup>	Multiple (2.9 cm × 2.8 cm)	1, TACE
32	M	IVC + HV	Long	IVC angioplasty	13211	C (Lt. PVT)	A	TACE	PD	240	3.0 (12.0 cm × 5.6 cm)	-
25	F	HV	Short	HV angioplasty	16.6	B	B	TACE	NA	402 <sup>1</sup>	2.0 (5.0 cm × 3.3 cm)	-
29	F	IVC + HV	Long	IVC + HV angioplasty	13029	C (PVT)	B	TKI	NA	523	1.0 (9.5 cm × 7.1 cm)	-
21	F	HV	Long	TIPSS	500	B	A	SC	NA	9 <sup>1</sup>	2 (6 cm × 8 cm)	-
33	F	IVC + HV	Long	Medical management	14308	B	B	SC	NA	97 <sup>1</sup>	2.0 (6.9 cm × 5.4 cm)	-

<sup>1</sup>Alive at last follow up. AFP: Alpha-fetoprotein; BCLC: Barcelona Clinic Liver Cancer; BCS: Budd-Chiari syndrome; CR: Complete response; CTP: Child Turcotte Pugh; F: Female; HCC: Hepatocellular carcinoma; HV: Hepatic vein; IVC: Inferior vena cava; Lt.: Left; M: Male; NA: Not available; PD: Progressive disease; PR: Partial response; PVT: Portal vein thrombosis; Rt.: Right; SC: Supportive care; TACE: Transarterial chemoembolization; TARE: Transarterial radioembolization; TIPSS: Transjugular intrahepatic portosystemic shunt; TKI: Tyrosine kinase inhibitor.

shunt. Of the remaining 3 patients, 2 (11.7%) patients chose anticoagulation alone, and 1 patient denied treatment. Eight (47.05%) patients had restenosis/stent blocks after the initial intervention for the BCS and required reintervention.

Ten out of seventeen (58.8%) patients received treatment for HCC. Nine out of ten (90.0%) patients underwent TACE, and 1 (10%) patient received oral TKIs. Of the 7 patients who did not receive HCC treatment, 4 had BCLC-D disease, and 3 refused treatment. Re-interventions for HCC were done in 3 patients. The response at 1 mo based on mRECIST criteria was available for 8/9 patients who underwent radiological interventions. There was a complete response in 4 patients and partial response and progressive disease in 2 patients each. A total of 12 patients were alive at the last follow-up. The details of the patients are shown in Table 4.

### BCS-HCC data from Mumbai

A total of 9 out of 1140 BCS patients were diagnosed with HCC (85% males). CTP class B and C proportions were 5



**Table 4 Management of patients with Budd-Chiari syndrome-hepatocellular carcinoma at follow-up**

Age	Sex	Site of obstruction	Length of block	BCS intervention	BCS: Restenosis	BCS: Time between intervention and stent block in d	No. of reinterventions for BCS	Time between BCS and HCC diagnosis in d	AFP	BCLC	CTP	Initial HCC management	HCC response	Survival after diagnosis of HCC until last follow-up in d	No. of lesion/size	Reintervention for HCC
20	M	IVC + HV	Long	Medical management	No			2374	1320.0	B	B	TACE	PD	456	2.0 (3.0 cm × 3.6 cm)	2 (PAI, TACE)
35	F	IVC	Short	IVC angioplasty	Yes	1411	1 (IVC angioplasty)	2396	8.8	B	A	TACE	CR	306 <sup>1</sup>	3.0 (2.9 cm × 2.5 cm)	-
40	M	IVC + HV	Long	Medical management	No			186	8489.0	B	A	SC	NA	573 <sup>1</sup>	3 (6 cm × 7 cm)	-
52	M	HV	Long	HV angioplasty	Yes	116	1 (RHV stenting)	2148	4.0	B	B	TACE	CR	524 <sup>1</sup>	2 (9 cm × 5 cm)	-
35	F	IVC	Long	IVC angioplasty	No			4273	3888.0	B	A	TACE	PD	147 <sup>1</sup>	7.0 (4.0 cm × 3.9 cm)	-
47	F	IVC + HV	Long	IVC angioplasty	Yes	169	2 (IVC angioplasty, IVC angioplasty)	788	1240.0	B	A	TACE	PR	3928 <sup>1</sup>	3 (7 cm × 7 cm)	5 (TACE, TACE, PAI, TACE, TACE)
24	M	IVC + HV	Short	Medical management	No			3771	177910.0	D	C	SC	NA	58	Infiltrative	-
21	M	HV	Long	TIPSS	Yes	166	1 (TIPSS revision)	424	4.4	B	A	TACE	CR	2374 <sup>1</sup>	Multiple (3.1 cm × 2.3 cm)	-
22	F	IVC	Long	IVC angioplasty	Yes	973	2 (TIPSS, TIPSS revision)	2062	1300.0	C	B	TACE	NA	24 <sup>1</sup>	1 (11.2 cm × 8.8 cm)	-
45	F	IVC + HV	Long	IVC angioplasty	Yes	412	2 (Balloon dilatation, balloon)	4603	500.0	B	A	SC	NA	6 <sup>1</sup>	Multiple/NA	-
26	F	IVC + HV	Long	IVC angioplasty	No			4018	315.0	C	B	TKI	NA	2164	Infiltrative	-
52	F	IVC + HV	Long	IVC angioplasty	Yes	284	1 (IVC angioplasty)	1768	14951.0	D	C	SC	NA	40 <sup>1</sup>	Multiple	-
30	M	HV	Short	HV angioplasty	No			306	66.6	B	A	TACE	CR	1352	4.0 (4.1 cm × 3.6 cm)	2 (TACE, TACE)
40	M	IVC + HV	Long	IVC angioplasty	No			262	131.0	D	C	SC	NA	35	Infiltrative with PVT	-

32	F	IVC	Short	IVC angioplasty	No			3762	2.2	A	A	SC	NA	49 <sup>1</sup>	2 (2 cm × 1 cm)	-
30	M	IVC + HV	Long	PSRS	Yes	5484	1 (TIPSS)	5599	353.0	B	B	TACE	PR	17 <sup>1</sup>	2.0 (4.0 cm × 4.2 cm)	TKI
28	M	HV	Long	TIPSS	No			4023	500.0	D	C	SC	NA	22 <sup>1</sup>	Infiltrative with PVT	-

<sup>1</sup>Alive at last follow-up. AFP: Alpha-fetoprotein; BCLC: Barcelona Clinic Liver Cancer; BCS: Budd-Chiari syndrome; CR: Complete response; CTP: Child Turcotte Pugh; F: Female; HCC: Hepatocellular carcinoma; HV: Hepatic vein; IVC: Inferior vena cava; M: Male; NA: Not available; PAI: Percutaneous acetic acid injection; PD: Progressive disease; PR: Partial response; PSRS: Proximal splenorenal shunts; PVT: Portal vein thrombosis; RHV: Right hepatic vein; SC: Supportive care; TACE: Transarterial chemoembolization; TIPSS: Transjugular intrahepatic portosystemic shunt; TKI: Tyrosine kinase inhibitor.

(55.5%) and 4 (44.4%), respectively. All had a long segment block and a combined IVC and HV block, except 1 patient who had a short segment HV block. All except 1 patient were diagnosed with HCC during follow-up. The median AFP was 900 ng/mL (25-1450). In comparison with the New Delhi cohort, there were no differences in the median age of onset of BCS (32 years *vs* 30 years), duration of symptoms, length, site of block (long segment and combined blocks), and number of nodules (multinodular disease). In contrast to the New Delhi Centre, HCC was found predominantly in males (85% *vs* 45%,  $P = 0.09$ ), and presented with a more advanced HCC (BCLC C and D, 6 (66.7%) *vs* 13 (37.1%),  $P = 0.14$ ), and patients were not amenable to any locoregional therapy at the time of presentation.

Three out of nine (33%) patients underwent TIPSS for BCS; the rest were managed with anticoagulation alone. Only 1 patient had restenosis/stent block after the initial intervention for BCS, for which reintervention was done. Two patients underwent liver transplantation for HCC (alive at last follow-up of 3 years and 8 years, respectively). A total of 7 patients were alive at the last follow-up (Table 5).

## DISCUSSION

The present study highlighted that HCC can manifest at the time of diagnosis of BCS or develop later. Radiological interventions are feasible in a select group of patients and may improve outcomes. In this study, the prevalence of primary HCC at index presentation was 1.99%, and the incidence was 0.36 (0.22-0.57) per 100 person-years.

In a meta-analysis of 1487 articles on BCS, only 16 studies provided the frequency of HCC[3]. Heterogeneity among the included studies was statistically significant and arose due to variable periods of inclusion, discrepancy in diagnostic criteria and methods, different follow-up periods, and inclusion of studies with concomitant viral hepatitis. The variability in the prevalence of HCC in BCS is significant (2.0%-46.2% in 12 Asian studies, 40.0%-51.6% in 2 African studies, 11.3% in 1 European study, and 11.1% in 1 American study). The analysis showed that among BCS patients with viral hepatitis, the pooled prevalence of HCC was 17.6% (95% confidence interval: 10.1%-26.7%), whereas among those with BCS alone, the pooled prevalence of HCC was 15.4% (95% confidence interval: 6.8%-26.7%). Table 6 details studies reporting the prevalence of BCS-HCC among patients with BCS. The higher prevalence in Africa and Japan compared to Western countries and India may be due to differences in the patient populations, the follow-up periods, the underlying etiology of BCS, the severity of cirrhosis at the time of diagnosis, and the exclusion or inclusion of patients with chronic viral hepatitis[19,20]. Many previous studies that reported the association of HCC with BCS included cases with HBV or HCV co-infection[7,21-23]. Therefore, the present study on primary BCS cases without other known risk factors of HCC

Table 5 Management of patients with Budd-Chiari syndrome-hepatocellular carcinoma (Mumbai center)

Age	Sex	Site of obstruction	Length of block	BCS intervention	BCS: Restenosis	BCS: Time between intervention and stent block	No. of Reinterventions for HVOTO	Time between BCS and HCC diagnosis in d	AFP	BCLC	CTP	Initial HCC management	HCC response	Survival after diagnosis of HCC until last follow-up in d	No. of lesion	Reintervention for HCC
30	M	IVC + HV	Long	Medical management	No			3500	58000	C	C	Conservative		120 <sup>1</sup>	4	None
46	M	IVC+ HV	Long	Medical management	No			150	25.60	D	C	Conservative		365 <sup>1</sup>	4	None
51	M	HV	Short	Medical management	No			350	1.16	D	C	Conservative		90 <sup>1</sup>	4	None
22	M	IVC + HV	Long	Medical management	No			460	600	C	B	Conservative		150 <sup>1</sup>	3	None
35	M	IVC + HV	Long	TIPSS	No			3400	1200	D	C	Conservative		30	4	None
15	F	IVC + HV	Long	Medical management	No			240	NA	B	B	LT		1000 <sup>1</sup>	1	None
16	M	IVC + HV	Long	TIPSS	Yes	150	IVC angioplasty	3300	NA	B	B	LT		2900 <sup>1</sup>	2	None
NA	NA	IVC + HV	Long	TIPSS	No			1200	NA	B	B	Conservative		60 <sup>1</sup>	1	None
NA	NA	IVC +HV	Long	Medical management				400	1450	D	B	Conservative		180 <sup>1</sup>	4	None

<sup>1</sup>Alive at last follow-up. AFP: Alpha-fetoprotein; BCLC: Barcelona Clinic Liver Cancer; BCS: Budd-Chiari syndrome; CTP: Child Turcotte Pugh; F: Female; HCC: Hepatocellular carcinoma; HV: Hepatic vein; HVOTO: Hepatic venous outflow tract obstruction; IVC: Inferior vena cava; LT: Liver transplant; M: Male; NA: Not available; TIPSS: Transjugular intrahepatic portosystemic shunt.

assumes importance.

Our study found a relatively low prevalence of 1.9% of primary BCS-HCC (18/904 cases of HCC at first presentation). The sample sizes in the previously reported studies were small and may have been associated with selection bias. Two previous studies reported the incidence of HCC in BCS prospectively as 2.85% and 5.30%, respectively, and both were limited by a low number of patients and short follow-up durations (7 years and 10 years, respectively)[24,25]. Our results suggest that the incidence of BCS-HCC is low compared to viral hepatitis-related HCC[21,26,27].

Four previous studies have reported the presence of long-segment IVC strictures and combined IVC and HV blocks as risk factors for the development of HCC in patients with BCS[4,6,7,9]. In agreement with the reported studies, we found that a long segment IVC block and combined IVC and HV block were associated with HCC. Long segment block may be associated with more hepatic congestion and extensive fibrosis due to persistent, progressive parenchymal injury.

In our study cases, a liver lesion might have gone undetected on Doppler ultrasound, as the scans were focused on assessing stent patency. This could have affected our incidence estimates. It is difficult to biopsy suspicious lesions in BCS, as there is a high risk of bleeding consequent to anticoagulation and the risk of recurrent thrombosis upon its discontinuation. Therefore, the decision to biopsy is generally taken on a case-by-case basis. The above facts highlight the

**Table 6 Summary of incidence, risk factors, and management of hepatic venous outflow tract obstruction-hepatocellular carcinoma**

Ref.	Country	Patients, <i>n</i>	Incidence of HCC, <i>n</i> (%)	Risk factors	Treatment offered
Nakamura <i>et al</i> [31], 1968	Japan	64	28 (43.7)	Not provided	Details not provided
Nakamura and Takezawa <i>et al</i> [32], 1982	Japan	13	6 (46.0)	Age at BCS diagnosis < 44 yr; complete obstruction of IVC	Details not provided
Simson <i>et al</i> [33], 1982	South Africa	101	48 (47.5)	Not provided	Details not provided
Rector <i>et al</i> [34], 1985	United States	10	2 (20.0)	Not provided	Details not provided
Kew <i>et al</i> [35], 1989	South Africa	15	6 (40.0)	Not provided	Details not provided
Okuda <i>et al</i> [1], 1998	Japan	148	10 (6.7)	Not provided	Details not provided
Shrestha <i>et al</i> [36], 1996	Nepal	150	7 (4.6)	Not provided	Details not provided
Bayraktar <i>et al</i> [24], 1998	Turkey	56 (prospective study duration 10 years)	3 (5.3)	Hepatic vein thrombosis	Details not provided
Dilawari <i>et al</i> [37], 1994	India	115	9 (7.8)	Not provided	Details not provided
Matsui <i>et al</i> [38], 2000	Japan	12	3 (25.0)	Chronic congestion	Resection (1); TACE (1); chemotherapy (1)
Shin <i>et al</i> [23], 2004	South Korea	73	15 (20.5), 6 <i>de novo</i> /9 follow up	Female sex not provided	TACE (11); resection (2); conservative (2)
Moucari <i>et al</i> [4], 2008	France	97	11 (11.3)	Male, factor V Leiden mutation, IVC obstruction	TACE (7); LT (3); conservative (1)
Amarapurkar <i>et al</i> [25], 2008	India	35 (prospective study); follow-up 42 mo	1 (2.8)	Not provided	Details not provided
Shrestha <i>et al</i> [39], 2009	Nepal	56	6 (10.7)	HV block	PAI (1); supportive (5)
Gwon <i>et al</i> [11], 2010	Korea	98	23 (23.4)	Female sex	TACE (20); TACE + LT (3)
Park <i>et al</i> [5], 2012	Korea	95	17, annual incidence 2.8	Elevated HVPG	Intraarterial chemotherapy (3); conservative (3); LT (2)
Liu <i>et al</i> [6], 2013	China	246	14 (5.6)	IVC block + stricture of hepatic venous outflow	TACE (14)
Paul <i>et al</i> [9], 2015	India	421	16 (3.8)	Cirrhosis; combined IVC and HV block; long segment IVC block	TACE (11); TKI (1); conservative (4)
Sakr <i>et al</i> [8], 2017	Egypt	348	15 (4.3)	Male, older age; cigarette smoking, AFP > 24.5	TACE (4); TACE + RFA (2); TACE + TKI (1); conservative (8)
Li <i>et al</i> [7], 2022	China	113	12 (10.6)	IVC block + stricture of hepatic venous outflow	Resection (2); RFA (1); Conservative (4); TACE (5)

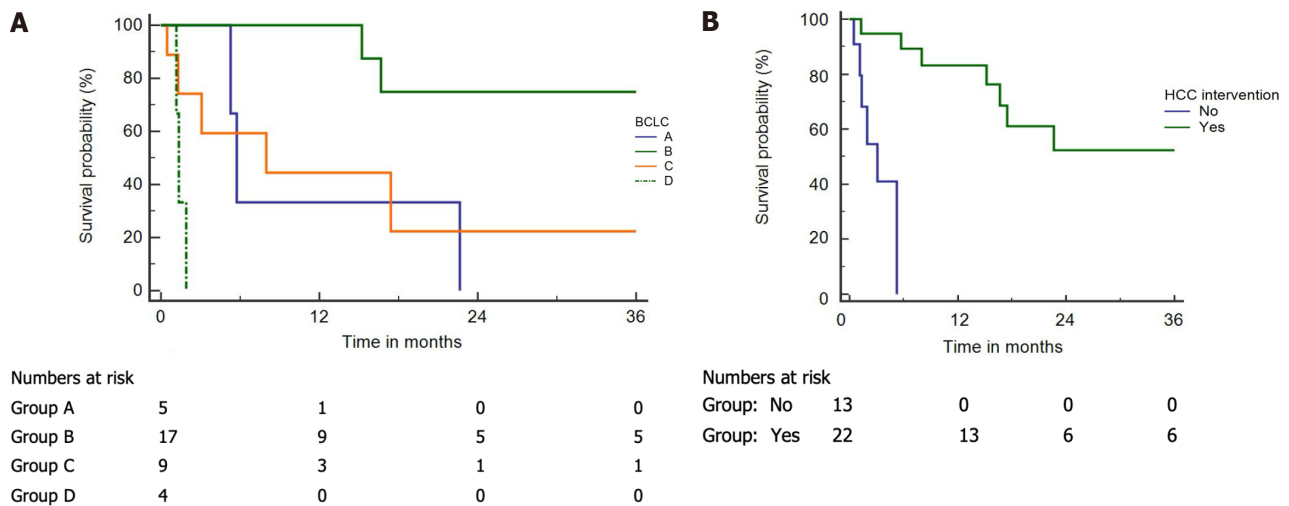
AFP: Alpha-fetoprotein; BCS: Budd-Chiari syndrome; HV: Hepatic vein; HVPG: Hepatic venous pressure gradient; IVC: Inferior vena cava; LT: Liver transplant; TACE: Transarterial chemoembolization; HCC: Hepatocellular carcinoma; PAI: Percutaneous acetic acid injection; RFA: Radiofrequency ablation; TKI: Tyrosine kinase inhibitor.

difficulties in screening patients with BCS having liver cirrhosis for development of HCC and may explain why most of these patients were detected in advanced stages of liver cancer, as in our study.

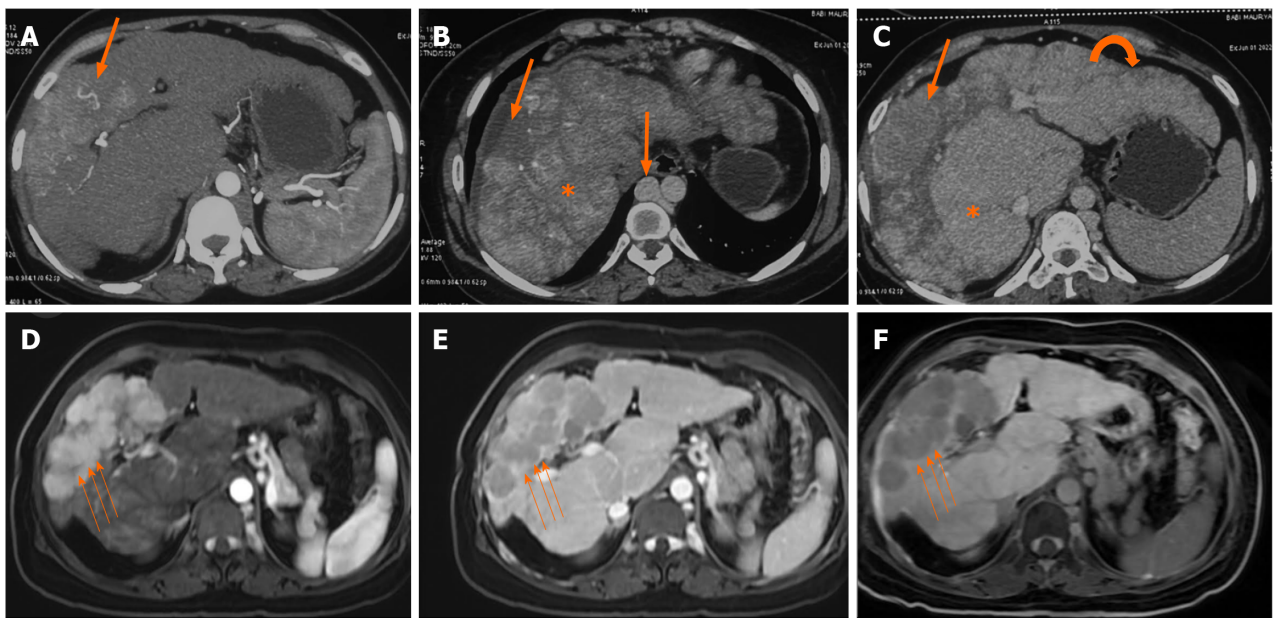
The serum AFP levels in BCS-HCC were significantly higher than BCS patients without HCC (1310.0 ng/mL *vs* 2.9 ng/mL). The median serum AFP in patients with BCS-HCC at presentation was higher than those who developed HCC at follow-up (13029 ng/mL *vs* 500 ng/mL). Not all HCCs produce AFP; at the same time, false positive results due to raised AFP levels are not infrequent, such as in active viral hepatitis[28-30].

Of all BCS patients, approximately 70% of patients in both HCC and non-HCC groups received an intervention for vascular decompression, with no significant differences in the rates of stent block or reintervention on follow-up.

In our cohort, most BCS-HCC patients presented as BCLC-B, had multinodular disease, underlying cirrhosis, and portal hypertension and were not eligible for curative resection or ablation. Our data suggests that the choice of modalities of therapy varies between centers. This may be related to the choice of therapy as per the treating physician, expertise of interventional radiologist, cost of the procedure, and the availability of liver transplantation. The most common treatment modality was TACE in 18 (81.8%) patients. Shin *et al*[23] suggested that HCC patients associated with BCS were responsive to interventions such as TACE. Gwon *et al*[11] showed that, for HCC patients with membranous obstruction of the IVC who underwent TACE, the 3-year and 5-year survival rates were 61% and 46%, respectively. In our



**Figure 2 Kaplan-Meier curves of Budd-Chiari syndrome-hepatocellular carcinoma patients.** A and B: Kaplan-Meier curves of Budd-Chiari syndrome-hepatocellular carcinoma (HCC) patients; A: Per the Barcelona Clinic Liver Cancer (BCLC) stages (log-rank  $P < 0.001$ ); B: Intervention and without intervention (log-rank  $P < 0.001$ ).



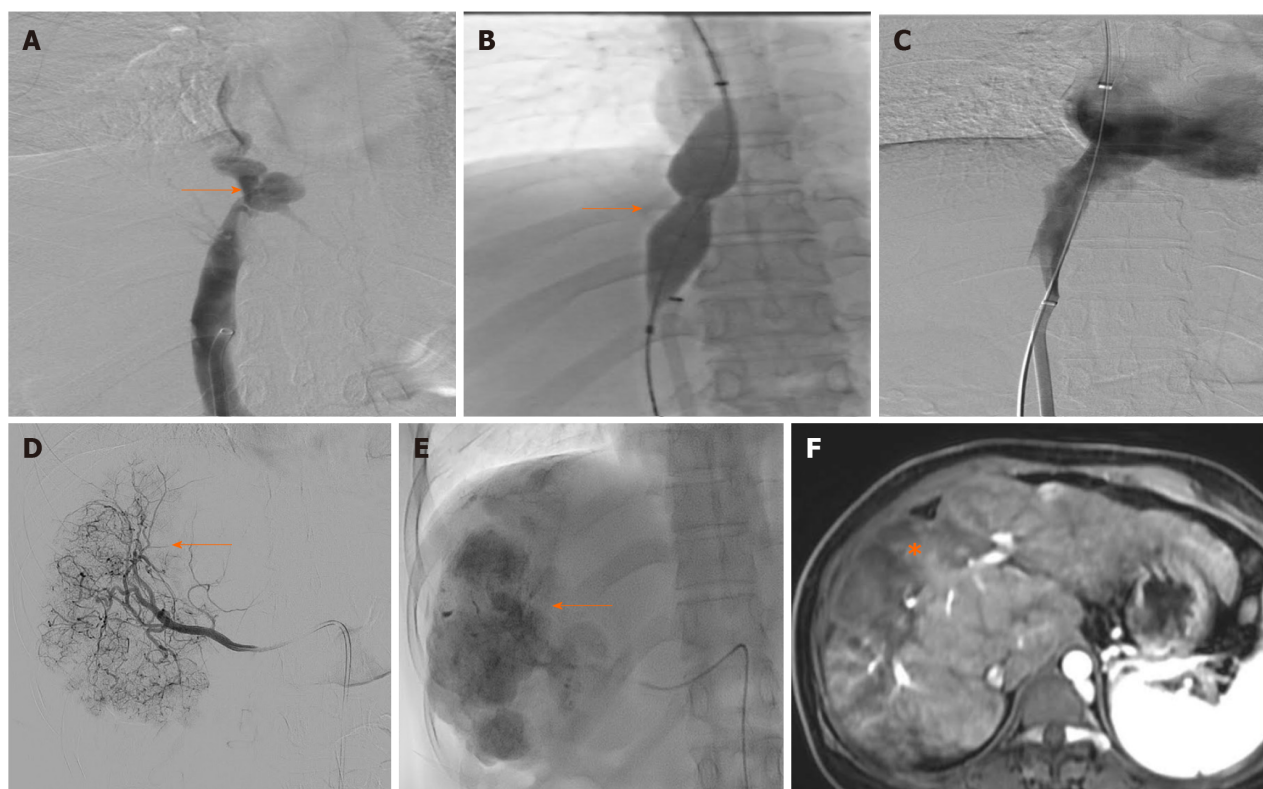
**Figure 3 Axial multiphase computed tomography images.** A-C: Axial multiphase computed tomography images showed a large arterial phase enhancing lesion (arrow) in the arterial phase and washout in portovenous phase (B) and delayed phase (C) in segment VIII and IV of the liver with background liver showing features of congestive changes (asterix) and cirrhotic changes (curved arrow). Note: Dilated azygous system due to inferior vena cava obstruction (block arrow); D and E: Axial multiphase magnetic resonance imaging (post angioplasty) showed resolution of congestive changes and normal caliber azygous system; F: Non-retention of contrast in hepatobiliary phase. Large arterial phase enhancing lesion (small arrows) in arterial phase (A) with washout in portovenous phase (E) and non-retention of contrast in hepatobiliary phase (F).

study, the median survival among cases with BCLC stages A, B, C, and D who underwent intervention was 6 mo, 45 mo, 8 mo, and 40 d, respectively. The apparent low survival of patients in the BCLC-A group may be attributed to fewer patients in this subgroup, potentially skewing the results. Also, only 2 patients among these received treatment for HCC. Therefore, it seems that the survival of patients with BCS-HCC is comparable to patients with other etiologies of HCC.

Treatment of BCS is associated with improvement in liver function tests, whereas interventions for HCC carry a risk of decompensation. Therefore, as a protocol, we treat BCS-HCC patients with interventions first for BCS, followed by HCC. There is no consensus in the literature regarding the methods and timing of treatment of HCC in patients with BCS. It remains unclear whether angioplasty and stenting can reduce the occurrence of new HCC and improve the results of TACE and other interventional procedures for HCC.

Our study has a few limitations. Our analysis included patients with BCS spanning more than three decades. The diagnostic modalities and our understanding of BCS and HCC have evolved over this period. In the initial part of the study, radiological investigations and interventions were unavailable for diagnosing and managing BCS and HCC.





**Figure 4 Digital subtraction spot images.** A-F: Digital subtraction spot images showed short segment narrowing of inferior vena cava (A, arrow) which was dilated using 20 mm × 40 mm balloon catheter (B, arrow), post angioplasty angiogram (C) good flow across the inferior vena cava without any residual narrowing. Selective right hepatic angiogram showed tumor blush (D, arrow), which was treated using lipiodol transarterial chemoembolization (E, arrow), follow-up magnetic resonance imaging after transarterial chemoembolization showed no residual enhancing lesion in the treated lesion (F, asterisk).

Hence, this lack of uniformity may have impacted the results of this study. It is possible that we might have missed BCS-HCC lesions in the initial part of the study. We excluded 158 (14.8%) patients because of missing data. The relationship between prothrombotic disorders, venous outflow obstruction level, and HCC development could not be assessed, as the data for all patients was unavailable at the time of analysis. Future studies need to assess the differences in the risk of development of HCC among patients with and without hypercoagulable states. Patients were assessed for hepatitis B surface antigen and anti-HCV antibody but not for the presence of hepatitis B virus-DNA and HCV-RNA in serum, which is a shortcoming. We diagnosed HCC based on imaging, elevated alpha-fetoprotein levels, and an increase in the size of the liver lesion over time. A lack of biopsy in the majority of patients for the diagnosis of HCC was another limitation of this study.

## CONCLUSION

HCC is not uncommon in patients with BCS. Radiological interventions and liver transplantation are feasible in primary BCS patients with HCC and may improve outcomes.

## ARTICLE HIGHLIGHTS

### Research background

Hepatocellular carcinoma (HCC) is a cancer with poor survival outcomes. Budd-Chiari syndrome (BCS) is a disease of the liver that leads to cirrhosis and may lead to HCC. Current guidelines are not clear regarding management of patients with both BCS and HCC. In clinical practice there can be barriers to providing treatments that can improve outcomes for those with HCC. Liver transplant or curative surgery are not an option for those diagnosed with advanced disease. Treatment protocols include managing BCS first followed by treating HCC. Locoregional therapies (*e.g.*, transarterial chemoembolization) is feasible in a selected group of patients and improves outcomes.

### Research motivation

There is very little data to decide management of HCC in BCS. Therefore, research into this area is needed due to the complexity of treating patients with both HCC and BCS. We hypothesize that treating BCS first followed by treatment of



HCC should be one of the strategies to improve outcomes in these patients.

### Research objectives

To investigate the magnitude, clinical characteristics, and treatment outcomes in patients with HCC and BCS.

### Research methods

We conducted a retrospective cohort study including patients diagnosed with BCS over a span of more than 30 years. We used Kaplan-Meier survival curve analysis to calculate the median survival of HCC among BCS patients using the available follow-up of each patient.

### Research results

In a study of 904 BCS patients, 35 developed BCS-associated HCC (BCS-HCC). Prevalence stood at 3.8%, with an HCC incidence of 0.36 per 100 person-years. BCS-HCC patients were older, had increased complications, and higher liver enzyme levels compared to BCS alone. Most underwent BCS interventions (74.3%), with 62.8% receiving HCC treatment. Those undergoing interventions exhibited prolonged median survival (3.5 years) as compared to those who did not (3.1 mo).

### Research conclusions

We found that HCC is not uncommon in patients with BCS. A significant proportion of them present as advanced disease precluding them from liver transplant or curative surgeries. Improvement in survival was statistically significant in patients receiving treatment for HCC as compared to ones who did not. Locoregional therapies were suitable in these patients and improves outcomes.

### Research perspectives

This study, a retrospective analysis of clinical records, observed that locoregional therapies are feasible in patients with HCC due to BCS, consequently leading to improved treatment outcomes. This further validates the role of locoregional therapies in patients with BCS-HCC.

---

## FOOTNOTES

**Author contributions:** Agarwal A and Biswas S designed and conducted the study, acquired the data, performed analysis and interpretation of data, and drafted the manuscript; Swaroop S, Aggarwal A, Agarwal A, Jain G, Vaidya A, Gupte A, Mohanka R, and Kumar R acquired the data and revised the manuscript; Mishra AK undertook the statistical analysis, interpretation of data, and revision of the manuscript; Elhence A, Gamanagatti S, Paul SB, Acharya SK, and Shukla A acquired the data and revised the manuscript; Shalimar conceptualized and designed the study and provided administrative, technical, or material support and study supervision, interpretation of data, critical revision, and final approval of the manuscript.

**Institutional review board statement:** This study was reviewed and approved by the Ethics Committee of the All India Institute of Medical Sciences, New Delhi (Approval No. IEC/NP-458/12.12.2014, RP 22-2015).

**Informed consent statement:** Written informed consent was waived (de-identified data).

**Conflict-of-interest statement:** We have no financial relationships to disclose.

**Data sharing statement:** No additional data are available.

**STROBE statement:** The authors have read the STROBE Statement—checklist of items, and the manuscript was prepared and revised according to the STROBE Statement—checklist of items.

**Open-Access:** This article is an open-access article that was selected by an in-house editor and fully peer-reviewed by external reviewers. It is distributed in accordance with the Creative Commons Attribution NonCommercial (CC BY-NC 4.0) license, which permits others to distribute, remix, adapt, build upon this work non-commercially, and license their derivative works on different terms, provided the original work is properly cited and the use is non-commercial. See: <https://creativecommons.org/licenses/by-nc/4.0/>

**Country/Territory of origin:** India

**ORCID number:** Ankit Agarwal 0000-0001-6372-9112; Sagnik Biswas 0000-0003-3487-4921; Shekhar Swaroop 0000-0001-7792-6846; Arnab Aggarwal 0000-0002-0638-8769; Ayush Agarwal 0000-0001-7271-4297; Gautam Jain 0000-0003-3759-0350; Anshuman Elhence 0000-0002-4192-0861; Arun Vaidya 0000-0001-6843-2406; Ramesh Kumar 0000-0001-5136-4865; Akash Shukla 0000-0001-7718-9452; Shalimar 0000-0003-1247-437X.

**S-Editor:** Chen YL

**L-Editor:** Filipodia

**P-Editor:** Zhang XD

# REFERENCES

- 1 **Okuda K**, Kage M, Shrestha SM. Proposal of a new nomenclature for Budd-Chiari syndrome: hepatic vein thrombosis versus thrombosis of the inferior vena cava at its hepatic portion. *Hepatology* 1998; **28**: 1191-1198 [PMID: [9794901](#) DOI: [10.1002/hep.510280505](#)]
- 2 **Afredj N**, Debsi N. Hepatocellular Carcinoma in Budd-Chiari Syndrome. In: Qi X, editor. Budd-Chiari Syndrome [Internet]. Singapore: Springer, 2020: 113-129 [DOI: [10.1007/978-981-32-9232-1\\_9](#)]
- 3 **Ren W**, Qi X, Yang Z, Han G, Fan D. Prevalence and risk factors of hepatocellular carcinoma in Budd-Chiari syndrome: a systematic review. *Eur J Gastroenterol Hepatol* 2013; **25**: 830-841 [PMID: [23411869](#) DOI: [10.1097/MEG.0b013e32835eb8d4](#)]
- 4 **Moucari R**, Rautou PE, Cazals-Hatem D, Geara A, Bureau C, Consigny Y, Francoz C, Denninger MH, Vilgrain V, Belghiti J, Durand F, Valla D, Plessier A. Hepatocellular carcinoma in Budd-Chiari syndrome: characteristics and risk factors. *Gut* 2008; **57**: 828-835 [PMID: [18218675](#) DOI: [10.1136/gut.2007.139477](#)]
- 5 **Park H**, Yoon JY, Park KH, Kim DY, Ahn SH, Han KH, Chon CY, Park JY. Hepatocellular carcinoma in Budd-Chiari syndrome: a single center experience with long-term follow-up in South Korea. *World J Gastroenterol* 2012; **18**: 1946-1952 [PMID: [22563176](#) DOI: [10.3748/wjg.v18.i16.1946](#)]
- 6 **Liu FY**, Wang MQ, Duan F, Fan QS, Song P, Wang Y. Hepatocellular carcinoma associated with Budd-Chiari syndrome: imaging features and transcatheter arterial chemoembolization. *BMC Gastroenterol* 2013; **13**: 105 [PMID: [23800233](#) DOI: [10.1186/1471-230X-13-105](#)]
- 7 **Li KS**, Guo S, Chen YX, Zhang ZL. Budd-Chiari syndrome and its associated hepatocellular carcinoma: Clinical risk factors and potential immunotherapeutic benefit analysis. *Front Oncol* 2022; **12**: 1075685 [PMID: [36568193](#) DOI: [10.3389/fonc.2022.1075685](#)]
- 8 **Sakr M**, Abdelhakam SM, Dabbous H, Hamed A, Hefny Z, Abdelmoaty W, Shaker M, El-Gharib M, Eldorriy A. Characteristics of hepatocellular carcinoma in Egyptian patients with primary Budd-Chiari syndrome. *Liver Int* 2017; **37**: 415-422 [PMID: [27507647](#) DOI: [10.1111/liv.13219](#)]
- 9 **Paul SB**, Shalimar, Sreenivas V, Gamanagatti SR, Sharma H, Dhamija E, Acharya SK. Incidence and risk factors of hepatocellular carcinoma in patients with hepatic venous outflow tract obstruction. *Aliment Pharmacol Ther* 2015; **41**: 961-971 [PMID: [25809735](#) DOI: [10.1111/apt.13173](#)]
- 10 **Reig M**, Forner A, Rimola J, Ferrer-Fàbrega J, Burrel M, Garcia-Criado Á, Kelley RK, Galle PR, Mazzaferro V, Salem R, Sangro B, Singal AG, Vogel A, Fuster J, Ayuso C, Bruix J. BCLC strategy for prognosis prediction and treatment recommendation: The 2022 update. *J Hepatol* 2022; **76**: 681-693 [PMID: [34801630](#) DOI: [10.1016/j.jhep.2021.11.018](#)]
- 11 **Gwon D**, Ko GY, Yoon HK, Sung KB, Kim JH, Lee SS, Lee JM, Ohm JY, Shin JH, Song HY. Hepatocellular carcinoma associated with membranous obstruction of the inferior vena cava: incidence, characteristics, and risk factors and clinical efficacy of TACE. *Radiology* 2010; **254**: 617-626 [PMID: [20093533](#) DOI: [10.1148/radiol.09090738](#)]
- 12 **Brown JJ**, Naylor MJ, Yagan N. Imaging of hepatic cirrhosis. *Radiology* 1997; **202**: 1-16 [PMID: [8988182](#) DOI: [10.1148/radiology.202.1.8988182](#)]
- 13 **Bruix J**, Sherman M, Llovet JM, Beaugrand M, Lencioni R, Burroughs AK, Christensen E, Pagliaro L, Colombo M, Rodés J; EASL Panel of Experts on HCC. Clinical management of hepatocellular carcinoma. Conclusions of the Barcelona-2000 EASL conference. European Association for the Study of the Liver. *J Hepatol* 2001; **35**: 421-430 [PMID: [11592607](#) DOI: [10.1016/s0168-8278\(01\)00130-1](#)]
- 14 **European Association for the Study of the Liver**. EASL Clinical Practice Guidelines: Management of hepatocellular carcinoma. *J Hepatol* 2018; **69**: 182-236 [PMID: [29628281](#) DOI: [10.1016/j.jhep.2018.03.019](#)]
- 15 **Hemachandran N**, Shalimar, Acharya S, Kedia S, Gunjan D, Saraya A, Sharma R, Gamanagatti S. Long-Term Outcomes of Endovascular Interventions in More than 500 patients with Budd-Chiari Syndrome. *J Vasc Interv Radiol* 2021; **32**: 61-69.e1 [PMID: [33218919](#) DOI: [10.1016/j.jvir.2020.08.035](#)]
- 16 **Shalimar**, Kumar A, Kedia S, Sharma H, Gamanagatti SR, Gulati GS, Nayak B, Thakur B, Acharya SK. Hepatic venous outflow tract obstruction: treatment outcomes and development of a new prognostic score. *Aliment Pharmacol Ther* 2016; **43**: 1154-1167 [PMID: [27060876](#) DOI: [10.1111/apt.13604](#)]
- 17 **Llovet JM**, Fuster J, Bruix J; Barcelona-Clinic Liver Cancer Group. The Barcelona approach: diagnosis, staging, and treatment of hepatocellular carcinoma. *Liver Transpl* 2004; **10**: S115-S120 [PMID: [14762851](#) DOI: [10.1002/Lt.20034](#)]
- 18 **Lencioni R**, Llovet JM. Modified RECIST (mRECIST) assessment for hepatocellular carcinoma. *Semin Liver Dis* 2010; **30**: 52-60 [PMID: [20175033](#) DOI: [10.1055/s-0030-1247132](#)]
- 19 **Valla DC**. Hepatic venous outflow tract obstruction etiopathogenesis: Asia vs the West. *J Gastroenterol Hepatol* 2004; **19**: S204-11 [DOI: [10.1111/j.1440-1746.2004.03642.x](#)]
- 20 **Chaubal A**, Shukla A. Budd-Chiari Syndrome: East vs West. *Budd-Chiari Syndrome* 2019; 231-243 [DOI: [10.1007/978-981-32-9232-1\\_18](#)]
- 21 **Shrestha SM**, Shrestha S, Shrestha A, Tsuda F, Endo K, Takahashi M, Okamoto H. High prevalence of hepatitis B virus infection and inferior vena cava obstruction among patients with liver cirrhosis or hepatocellular carcinoma in Nepal. *J Gastroenterol Hepatol* 2007; **22**: 1921-1928 [PMID: [17914971](#) DOI: [10.1111/j.1440-1746.2006.04611.x](#)]
- 22 **Valla DC**. Budd-Chiari syndrome/hepatic venous outflow tract obstruction. *Hepatol Int* 2018; **12**: 168-180 [PMID: [28685257](#) DOI: [10.1007/s12072-017-9810-5](#)]
- 23 **Shin SH**, Chung YH, Suh DD, Shin JW, Jang MK, Ryu SH, Park NH, Lee HC, Lee YS, Suh DJ. Characteristic clinical features of hepatocellular carcinoma associated with Budd-Chiari syndrome: evidence of different carcinogenic process from hepatitis B virus-associated hepatocellular carcinoma. *Eur J Gastroenterol Hepatol* 2004; **16**: 319-324 [PMID: [15195897](#) DOI: [10.1097/00042737-200403000-00012](#)]
- 24 **Bayraktar Y**, Egesel T, Sağlam F, Balkanci F, Van Thiel DH. Does hepatic vein outflow obstruction contribute to the pathogenesis of hepatocellular carcinoma? *J Clin Gastroenterol* 1998; **27**: 67-71 [PMID: [9706774](#) DOI: [10.1097/00004836-199807000-00014](#)]
- 25 **Amarapurkar DN**, Punamiya SJ, Patel ND. Changing spectrum of Budd-Chiari syndrome in India with special reference to non-surgical treatment. *World J Gastroenterol* 2008; **14**: 278-285 [PMID: [18186568](#) DOI: [10.3748/wjg.14.278](#)]
- 26 **Lin L**, Yan L, Liu Y, Qu C, Ni J, Li H. The Burden and Trends of Primary Liver Cancer Caused by Specific Etiologies from 1990 to 2017 at the Global, Regional, National, Age, and Sex Level Results from the Global Burden of Disease Study 2017. *Liver Cancer* 2020; **9**: 563-582 [PMID: [33083281](#) DOI: [10.1159/000508568](#)]
- 27 **Llovet JM**, Kelley RK, Villanueva A, Singal AG, Pikarsky E, Roayaie S, Lencioni R, Koike K, Zucman-Rossi J, Finn RS. Hepatocellular carcinoma. *Nat Rev Dis Primers* 2021; **7**: 6 [PMID: [33479224](#) DOI: [10.1038/s41572-020-00240-3](#)]
- 28 **Trevisani F**, D'Intino PE, Morselli-Labate AM, Mazzella G, Accogli E, Caraceni P, Domenicali M, De Notariis S, Roda E, Bernardi M. Serum alpha-fetoprotein for diagnosis of hepatocellular carcinoma in patients with chronic liver disease: influence of HBsAg and anti-HCV status. *J*

- Hepatol 2001; **34**: 570-575 [PMID: 11394657 DOI: 10.1016/s0168-8278(00)00053-2]
- 29 **Farinati F**, Marino D, De Giorgio M, Baldan A, Cantarini M, Cursaro C, Rapaccini G, Del Poggio P, Di Nolfo MA, Benvegnù L, Zoli M, Borzio F, Bernardi M, Trevisani F. Diagnostic and prognostic role of alpha-fetoprotein in hepatocellular carcinoma: both or neither? *Am J Gastroenterol* 2006; **101**: 524-532 [PMID: 16542289 DOI: 10.1111/j.1572-0241.2006.00443.x]
  - 30 **Llovet JM**, Real MI, Montaña X, Planas R, Coll S, Aponte J, Ayuso C, Sala M, Muchart J, Solà R, Rodés J, Bruix J; Barcelona Liver Cancer Group. Arterial embolisation or chemoembolisation versus symptomatic treatment in patients with unresectable hepatocellular carcinoma: a randomised controlled trial. *Lancet* 2002; **359**: 1734-1739 [PMID: 12049862 DOI: 10.1016/s0140-6736(02)08649-x]
  - 31 **Nakamura T**, Nakamura S, Aikawa T, Suzuki O, Onodera A, Karoji N. Obstruction of the inferior vena cava in the hepatic portion and the hepatic veins. Report of eight cases and review of the Japanese literature. *Angiology* 1968; **19**: 479-498 [PMID: 5677579 DOI: 10.1177/000331976801900805]
  - 32 **Nakamura S**, Takezawa Y. Obstruction of the inferior vena cava in the hepatic portion and hepatocellular carcinoma. *Tohoku J Exp Med* 1982; **138**: 119-120 [PMID: 6293115 DOI: 10.1620/tjem.138.119]
  - 33 **Simson IW**. Membranous obstruction of the inferior vena cava and hepatocellular carcinoma in South Africa. *Gastroenterology* 1982; **82**: 171-178 [PMID: 6274728 DOI: 10.1016/0016-5085(82)90001-4]
  - 34 **Rector WG Jr**, Xu YH, Goldstein L, Peters RL, Reynolds TB. Membranous obstruction of the inferior vena cava in the United States. *Medicine (Baltimore)* 1985; **64**: 134-143 [PMID: 3871892 DOI: 10.1097/00005792-198503000-00005]
  - 35 **Kew MC**, McKnight A, Hodgkinson J, Bukofzer S, Esser JD. The role of membranous obstruction of the inferior vena cava in the etiology of hepatocellular carcinoma in Southern African blacks. *Hepatology* 1989; **9**: 121-125 [PMID: 2461892 DOI: 10.1002/hep.1840090121]
  - 36 **Shrestha SM**, Okuda K, Uchida T, Maharjan KG, Shrestha S, Joshi BL, Larsson S, Vaidya Y. Endemicity and clinical picture of liver disease due to obstruction of the hepatic portion of the inferior vena cava in Nepal. *J Gastroenterol Hepatol* 1996; **11**: 170-179 [PMID: 8672764 DOI: 10.1111/j.1440-1746.1996.tb00056.x]
  - 37 **Dilawari JB**, Bamberg P, Chawla Y, Kaur U, Bhusnurmath SR, Malhotra HS, Sood GK, Mitra SK, Khanna SK, Walia BS. Hepatic outflow obstruction (Budd-Chiari syndrome). Experience with 177 patients and a review of the literature. *Medicine (Baltimore)* 1994; **73**: 21-36 [PMID: 8309360 DOI: 10.1097/00005792-199401000-00003]
  - 38 **Matsui S**, Ichida T, Watanabe M, Sugitani S, Suda T, Takahashi T, Asakura H. Clinical features and etiology of hepatocellular carcinoma arising in patients with membranous obstruction of the inferior vena cava: in reference to hepatitis viral infection. *J Gastroenterol Hepatol* 2000; **15**: 1205-1211 [PMID: 11106103 DOI: 10.1046/j.1440-1746.2000.02303.x]
  - 39 **Shrestha SM**. Liver cirrhosis and hepatocellular carcinoma in hepatic vena cava disease, a liver disease caused by obstruction of inferior vena cava. *Hepatol Int* 2009; **3**: 392-402 [PMID: 19669366 DOI: 10.1007/s12072-009-9122-5]



Published by **Baishideng Publishing Group Inc**  
7041 Koll Center Parkway, Suite 160, Pleasanton, CA 94566, USA

**Telephone:** +1-925-3991568

**E-mail:** [office@baishideng.com](mailto:office@baishideng.com)

**Help Desk:** <https://www.f6publishing.com/helpdesk>

<https://www.wjgnet.com>

