



Observational Study

Des-gamma-carboxy prothrombin and alpha-fetoprotein levels as biomarkers for hepatocellular carcinoma and their correlation with radiological characteristics

Muhammad Ali Qadeer, Zaigham Abbas, Shaima Amjad, Bushra Shahid, Abeer Altaf, Mehreen Siyal

Specialty type: Gastroenterology and hepatology

Provenance and peer review: Invited article; Externally peer reviewed.

Peer-review model: Single blind

Peer-review report's scientific quality classification

Grade A (Excellent): 0
Grade B (Very good): 0
Grade C (Good): C
Grade D (Fair): 0
Grade E (Poor): 0

P-Reviewer: Nasrallah O, Syria

Received: December 16, 2023

Peer-review started: December 16, 2023

First decision: January 31, 2024

Revised: February 13, 2024

Accepted: March 26, 2024

Article in press: March 26, 2024

Published online: April 22, 2024



Muhammad Ali Qadeer, Zaigham Abbas, Abeer Altaf, Mehreen Siyal, Department of Hepato-gastroenterology, Dr. Ziauddin University Hospital Clifton, Karachi 75600, Pakistan

Shaima Amjad, Family Medicine, Dr. Ziauddin University Hospital Clifton, Karachi 75600, Pakistan

Bushra Shahid, Internal Medicine, Dr. Ziauddin University Hospital Clifton, Karachi 75600, Pakistan

Corresponding author: Zaigham Abbas, AGAF, FACG, FACP, FCPS, FRCP, MBBS, Professor, Department of Hepatogastroenterology, Dr. Ziauddin University Hospital, 4/B Shahrah-e-Ghalib Rd, Block 6, Clifton, Karachi 75600, Pakistan. drzabbas@gmail.com

Abstract

BACKGROUND

Alpha-fetoprotein (AFP), a commonly used biomarker for hepatocellular carcinoma (HCC), is normal in up to one-third of patients.

AIM

To evaluate the diagnostic performance of des-gamma-carboxy-prothrombin (DCP) alone and in combination with AFP.

METHODS

In this study, 202 patients with radiologically proven HCC were enrolled, and their DCP and AFP levels were evaluated for their diagnostic performance.

RESULTS

The mean age of the enrolled patients was 58.5 years; 72.0% were male. DCP was elevated in 86.6% ($n = 175$) of all patients, 100.0% ($n = 74$) of patients with portal vein thrombus, and 87.4% ($n = 111$) of patients with multicentric HCC. AFP was elevated in 64.3% ($n = 130$) of all the patients, 74% ($n = 55$) of the patients with portal vein thrombus, and 71.6% ($n = 91$) of the patients with multicentric HCC ($P = 0.030$, 0.001 , and 0.015 , respectively). In tumors less than 2 cm in size ($n = 46$), DCP was increased in 32 (69.5%) patients, and AFP was increased in 25 (54.3%) patients ($P = 0.801$). There was good pairing between DCP and AFP for HCCs of 2 cm size or larger ($P < 0.001$); however, the pairing among tumors < 2 cm size was

not significant ($P = 0.210$). In 69 of the patients (34.1%), only one of the tumor markers was positive; DCP was elevated alone in 57/202 (28.2%) of all patients, and AFP alone was elevated in 12/202 (5.9%) of the patients. The areas under receiver operating characteristic curves (AUROC) for tumors > 2 cm was 0.74 for DCP and 0.59 for AFP; combining both markers resulted in an AUROC of 0.73. For tumors < 2 cm, the AUROC was 0.25 for DCP and 0.40 for AFP.

CONCLUSION

DCP, as an individual marker, had a better diagnostic performance in many cases of HCC. Hence, DCP may replace AFP as the primary HCC biomarker.

Key Words: Des-gamma-carboxy prothrombin; Protein induced by vitamin K absence-II; Cirrhosis; Alpha-fetoprotein; Biomarkers; Hepatocellular carcinoma; Portal vein thrombus

©The Author(s) 2024. Published by Baishideng Publishing Group Inc. All rights reserved.

Core Tip: In this prospective study, the performance of des-gamma-carboxy prothrombin (DCP) relative to alpha-fetoprotein (AFP) was assessed in 202 patients diagnosed with hepatocellular carcinoma (HCC). DCP, when used as a standalone marker, exhibited superior diagnostic performance compared to AFP. Combining both tumor markers increased the overall detection rate of HCC, particularly in tumors less than 2 cm in length. Nevertheless, it is recommended that, if a single tumor marker is used, DCP is preferred. The role of DCP as a screening biomarker should be incorporated into the HCC guidelines.

Citation: Qadeer MA, Abbas Z, Amjad S, Shahid B, Altaf A, Siyal M. Des-gamma-carboxy prothrombin and alpha-fetoprotein levels as biomarkers for hepatocellular carcinoma and their correlation with radiological characteristics. *World J Gastrointest Pathophysiol* 2024; 15(1): 90893

URL: <https://www.wjgnet.com/2150-5330/full/v15/i1/90893.htm>

DOI: <https://dx.doi.org/10.4291/wjgp.v15.i1.90893>

INTRODUCTION

Hepatocellular carcinoma (HCC), the predominant liver malignancy, is the sixth most commonly diagnosed cancer[1]. Radiological modalities have been at the forefront of screening and diagnosing HCC, but tumor markers have also contributed to its early detection[2]. Early detection of HCC not only dictates treatment modality but also influences expected survival[3]. Tumor markers such as alpha-fetoprotein (AFP) and the protein induced by vitamin K absence-II (PIVKA-II) also known as des-gamma-carboxy-prothrombin (DCP), if elevated beyond certain limits, can influence the HCC recurrence rate after liver transplantation[4].

Various studies have noted the inadequacy of AFP for screening for HCC, with almost 40% of tumors flagged as non-AFP-producing[5]. PIVKA II/DCP, an abnormal prothrombin precursor, has also been described as a potential screening tool for liver cancer[6]. A large body of evidence supports that it has better sensitivity than AFP, with reported sensitivities reaching up to 84%[7-9]. DCP has been shown to be effective not only for detecting HCC but also for predicting its radiological and histological characteristics[9]. However, despite this supportive literature, conflicting data have also been published that have limited the use of DCP in clinical practice. Hence, we evaluated the diagnostic performance of DCP alone and in combination with AFP and analyzed its correlation with radiographic parameters such as size, lobe involvement, and vascular invasion. The diagnostic performance of DCP for AFP-negative HCC was also analyzed.

MATERIALS AND METHODS

Patient data

A total of 202 patients with radiologically confirmed HCC were included in this prospective study at Dr. Ziauddin University Hospital from January 2019 to March 2022. This study was approved by Dr. Ziauddin University's ethical review board. Informed consent was obtained from all the participants following the ethical standards of the 1964 Helsinki Declaration.

HCC was diagnosed based on the Liver Imaging Reporting and Data System v2017. Liver lesions falling within the LIRAD-V were considered acceptable for inclusion in this study. Patients aged less than 18 years with a history of HCC treatment, use of vitamin K antagonists, or obstructive jaundice were excluded.

Analysis of PIVKA and AFP

The ARCHITECT PIVKA-II assay3C10 (Abbott Laboratories, IL, United States) using chemiluminescent technology was used for the quantification of PIVKA-II. DCP was considered normal if the value fell below 46 mAU/mL. The AFP

concentration was analyzed using an ARCHITECT AFP 3P36 (Abbott Laboratories, IL, United States) kit, which uses a two-step immunoassay for quantitative measurement. AFP was considered normal if the value was less than 8.78 ng/mL.

Statistical analysis

SPSS version 26 was used for the statistical analysis. For all dichotomous variables, the data are summarized as percentages. Categorical variables were compared using Fisher's exact test. The Mann-Whitney *U* test was used for continuous variables. The McNemar test was used to assess the performance of the two tumor markers, and the areas under receiver operating characteristic curves (AUROC) was also calculated.

RESULTS

A total of 202 HCC patients with a mean age of 58.5 years \pm 10.3 years were enrolled. Seventy-two percent ($n = 146$) of the enrolled patients were male. The main causes of HCC were hepatitis C virus (HCV) in 51.0% ($n = 103$) and hepatitis B virus (HBV) in 25% ($n = 52$), while non-alcoholic fatty liver disease (NAFLD) was diagnosed in 13.9% ($n = 28$) of patients. A decompensated CLD was found in 77% ($n = 157$) of the patients. A total of 36.6% ($n = 74$) of the included patients had portal vein thrombosis. A total of 22.8% ($n = 46$) of the HCCs were less than 2 cm in length. HCC was classified as multicentric in 62.9% ($n = 127$) of patients. Satellite lesions were identified in 15.3% ($n = 31$) of the patients. A total of 63.9% ($n = 129$) of the HCCs involved one lobe, while 36.1% ($n = 73$) had bilobar involvement (Table 1).

A total of 86.6% ($n = 175$) of the total HCC patients enrolled had elevated DCP levels (> 45 mAU/L), while 64.3% ($n = 130$) of the total patients had elevated AFP levels (> 10 ng/mL; $P = 0.03$). For small HCCs, less than 2 cm in size ($n = 46$), the DCP was increased in 69.5% ($n = 32$) and the AFP was increased in 54.3% ($n = 25$; $P = 0.801$). Among a total of 127 patients with multicentric HCC, 87.4% ($n = 111$) had increased DCP, while 71.6% ($n = 91$) had increased AFP ($P = 0.015$). Radiographic evidence of satellite lesions was observed in 31 patients, of which DCP and AFP were elevated in 87% ($n = 27$) and 54.8% ($n = 17$; $P = 0.835$), respectively. Thrombi in the portal vein were observed in 74 patients; all had increased DCP, and 74.3% ($n = 55$) had increased AFP ($P < 0.001$).

In patients with HCC caused by hepatitis C ($n = 103$), the DCP concentration increased by 92.2% ($n = 95$), while the AFP concentration increased by 66.9% ($n = 69$; $P = 0.009$). Of the 52 HCC patients with underlying hepatitis B etiology, 76.9% ($n = 40$) had a positive DCP result, and 67.3% ($n = 35$) had a positive AFP result ($P = 0.095$). Among the 28 patients with NAFLD and HCC, DCP was elevated in 82.1% ($n = 23$), and AFP was elevated in 57.1% ($n = 16$; $P = 0.887$).

Among the 202 patients, 58.4% had elevated both tumor marker levels ($n = 118$). In 34.1% ($n = 69$) of the patients, one of the tumor markers was positive, and in 7.4% of the patients, both tumor markers were negative ($n = 15$). In the group in which one of the tumor biomarker markers was positive, DCP alone was elevated in 57 (28.2% of all patients), whereas AFP alone was elevated in 12 (5.9%) patients. There was a strong pairing between DCP and AFP levels for HCCs of all sizes ($P < 0.001$) and for HCCs of 2 cm or larger ($P < 0.001$), but the pairing was weaker for smaller HCCs ($P = 0.210$).

There was a correlation between the DCP and AFP according to Spearman's correlation test ($P < 0.001$; Figure 1). ROC plots were drawn to analyze the magnitude of the increase in DCP and AFP levels. For tumors larger than 2 cm in size, the log₁₀ values of DCP exceeded the log₁₀ values of AFP, with areas under the curve of 0.74 and 0.59, respectively (Figure 2). Combining the values of two markers to detect HCC did not improve diagnostic ability, with an AUROC of 0.739. For tumors less than 2 cm in length, the area under the curve for the log value of DCP was 0.250 *vs* 0.409 for AFP. Therefore, DCP elevation may be modest in smaller localized tumors, although it crossed the positivity threshold in more patients than did AFP elevation.

DISCUSSION

HCC, a leading liver cancer, not only has a considerable mortality rate but also imposes an enormous economic burden[1, 10]. The false-negative rate of AFP, the most widely used tumor marker for HCC, is 30%-40%, motivating researchers to discover a more potent tumor marker with better diagnostic performance[11-13].

In this study, we examined the performance of DCP compared to AFP and correlated the values with radiological features. Our study showed that DCP performed better as a single marker than AFP for detecting HCC, but the combination of both markers did not improve the diagnostic capability. These observations agree with those reported by Xing *et al*[14], who showed that DCP was superior to AFP regardless of primary tumor size and underlying etiology, and the combination of the two markers resulted in increased sensitivity but decreased specificity, resulting in a decrease in overall diagnostic power[14,15].

Consistent with previous data from Pakistan, HCV appears to be a major cause of HCC development[16]. A subgroup analysis showed that DCP performed better in the HCV group. Similar findings were made in a Chinese study by Liu *et al* [17]. A statistically significant difference was not found between the two tumor markers in the HBV group in our study, possibly due to the small sample size, but DCP was still able to outcompete AFP in terms of diagnostic performance because of its detectability in a larger number of HCC patients. Several studies conducted to date on patients with HBV have shown that DCP alone and in combination with AFP yield better results than AFP alone[7,18].

It has been reported that DCP, when elevated, acts as a predictor of microvascular invasion, even in the absence of radiological evidence[9,19]. Although we did not assess microvascular invasion histologically, we did evaluate the diagnostic ability of these two markers for tumor portal vein thrombosis (PVT). Interestingly, our findings showed that

Table 1 Characteristics of study patients

Variables	Values
Age (yr)	58.5 ± 10.3
Gender: Males	146 (72.3)
Etiology	
HCV	103 (51.0)
HBV	52 (25.7)
Alcohol	8 (4.0)
NAFLD	28 (13.9)
Autoimmune liver disease	7 (3.5)
Cryptogenic	9 (4.5)
Lab parameters	
Hemoglobin (g/dL)	11.3 ± 2.1
White cell count ($\times 10^9/L$)	8.3 ± 5.5
Platelets ($\times 10^9/L$)	148.0 ± 102.0
Total bilirubin (mg/dL)	3.3 ± 5.6
Alanine aminotransferase (IU/L)	63.9 ± 51.4
Aspartate aminotransferase (IU/L)	113.0 ± 206.0
Alkaline phosphatase (IU/L)	203.0 ± 227.0
International normalization ratio	1.3 ± 0.4
Tumor parameters	
HCC size 2 cm or more	156 (77.2)
HCC less than 2 cm	46 (22.8)
Portal vein thrombus	74 (36.6)
Unilobed	129 (63.9)
Bilobed	73 (36.1)
Satellite lesions	31 (15.3)
Multicentric tumor	127 (62.9)
Des-gamma carboxyprothrombin (mAU/L)	669.4 (16.7-300000.0)
Alpha-fetoprotein (ng/mL)	32 (1-20000)

Values are mean ± SD or *n* (%).

HCV: Hepatitis C virus; HBV: Hepatitis B virus; NAFLD: Non-alcoholic fatty liver disease; HCC: Hepatocellular carcinoma.

DCP was elevated in all subjects with portal vein thrombus. Similar results were reported by Xu *et al*[20]. In their study, all 65 participants with PVT had elevated DCP levels.

Since patients with small HCCs (< 2 cm) have a good prognosis, it is important to detect them early in the disease course[3]. Interestingly, although a greater percentage of small HCC lesions exceeded the positivity threshold for DCP, the log values of AFP were much greater. The McNemar test did not reveal good agreement between the two markers, underscoring the value of testing both tumor markers in patients with small HCC. Data from other studies also have similar conclusions regarding sensitivity[21].

The GALAD scoring system, which consists of these two tumor markers in addition to sex, age, and AFP-L3, has been proposed and validated for determining the risk of HCC[22,23]. We did not test for AFP-L3. Recent studies have shown that sex, age, AFP, and DCP combination, the “GAAD” score, can be used to predict the presence of HCC effectively when the value is greater than 2.57[24]. AFP and DCP (PIVKA II) assays were performed on the Elecsys platform with an AFP cutoff of 20 ng/mL and a PIVKA II cutoff of 28.4 ng/mL. We used a cutoff AFP of 10 ng/mL to increase the sensitivity, and a cutoff DCP of 45.0 mAU/mL was used. As our assays were performed on the Architect platform, calculation, and implementation of GAAD scoring were not possible.

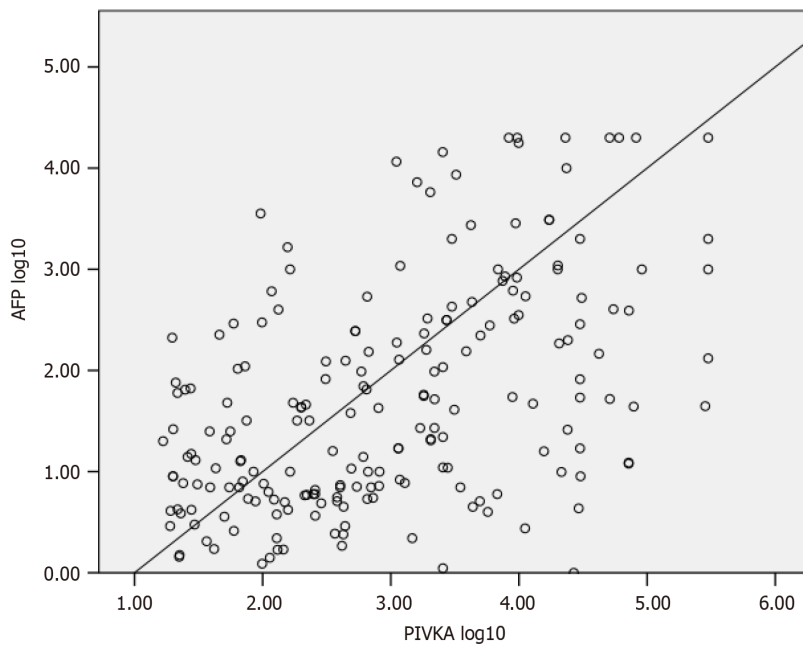


Figure 1 Correlation of Des-gamma-carboxy prothrombin (DCP) and alpha fetoprotein in hepatocellular carcinoma patients using Spearman's rank correlation analysis. $P < 0.001$. AFP: Alpha fetoprotein; PIVKA: protein induced by vitamin K absence-II also known as DCP.

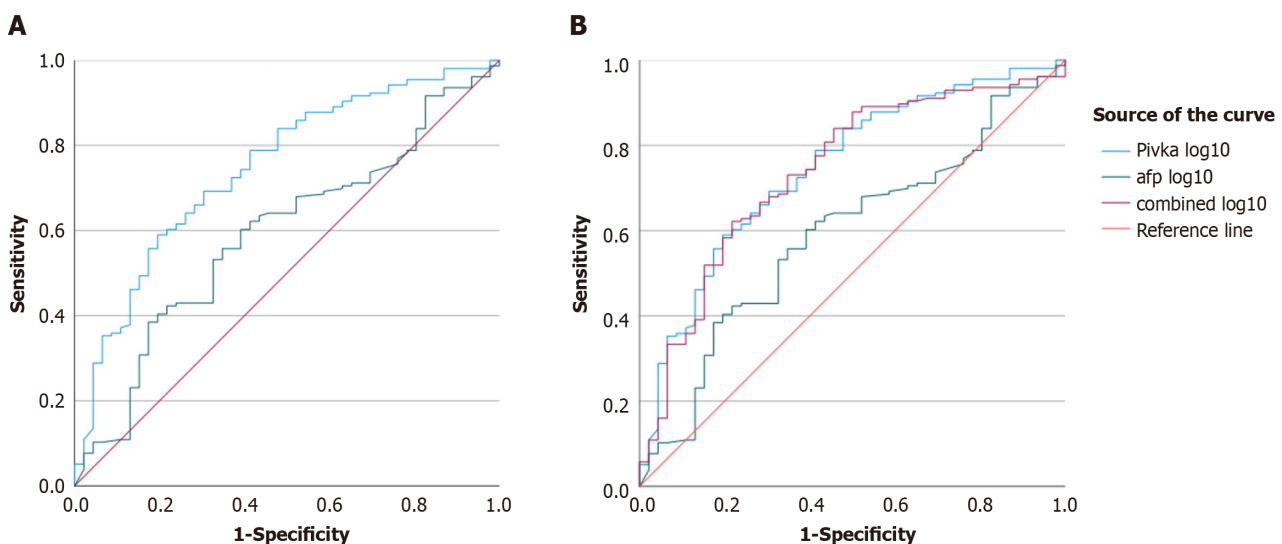


Figure 2 Receiver operating characteristic curve. A and B: Receiver operating characteristic curve comparing the values of two hepatocellular carcinoma biomarkers, des-gamma-carboxy-prothrombin, and alpha fetoprotein alone (A) or in combination (B) in a tumour size of 2 cm or more. Pivka: Protein induced by vitamin K absence-II [same as des-gamma-carboxy-prothrombin (DCP)]; afp: Alpha fetoprotein; combined: Combining DCP and AFP.

This study has several notable strengths that are worth acknowledging. First, our research, which focused on the effectiveness of DCP and AFP as biomarkers for HCC, is relevant and significant, given the increasing incidence of this cancer globally. Second, we employed rigorous statistical analyses, such as McNemar's test and AUROC analysis, to evaluate the correlation between DCP and AFP levels in patients with HCC. Third, the study illustrates the complementarity of DCP and AFP as biomarkers for diagnosing HCC in patients with a tumor diameter of less than 2 cm. Fourth, the study contributes to the mounting evidence supporting the use of DCP and AFP as biomarkers for HCC, which could result in better patient outcomes through earlier detection and treatment. Finally, the study offers valuable insights into the potential use of DCP as a biomarker for patients with HCC with portal vein thrombosis, which may guide future research in this field.

The current study has some limitations that must be considered when interpreting the results. First, the sample size was relatively small, and the study was conducted in a single center, which may limit the generalizability of the findings to other populations. Second, the cross-sectional design of the study makes it difficult to establish a causal relationship between DCP and AFP levels and the development of HCC. Additionally, the lack of a control group limits the ability to compare the results to individuals without HCC or other liver diseases. Finally, due to the small sample size, there was

limited statistical power to obtain statistically significant differences in DCP and AFP levels for tumors smaller than 2 cm, which may limit the generalizability of the results to individuals with early-stage HCC. Overall, these limitations must be taken into consideration when interpreting the findings of this study.

CONCLUSION

According to the results of our study, DCP was found to be a better biomarker than AFP for HCC detection, especially in patients with portal vein thrombosis. DCP, as an individual marker, performed better in many categories of HCC. Hence, DCP may replace AFP as the primary HCC biomarker. The findings also suggest that DCP and AFP may have complementary roles in the diagnosis of small HCC, and the combination of both markers could be considered for early detection of HCC, highlighting the importance of utilizing multiple biomarkers in the diagnosis of small HCC, as relying on a single biomarker may not be sufficient. The role of DCP as a screening biomarker should be incorporated into the HCC guidelines.

FOOTNOTES

Co-first authors: Muhammad Ali Qadeer and Zaigham Abbas.

Author contributions: Qadeer MA and Abbas Z contributed equally to the manuscript; Qadeer MA drafted the manuscript, supervised data collection, and assisted in data analysis; Abbas Z conceived the study, performed data analysis, supervised manuscript writing, and revised manuscript according to the reviewers' comments; Amjad S, Shahid B, Altaf A, and Siyal M were involved in the data collection; and all authors read the final manuscript and approved it.

Institutional review board statement: The study was reviewed and approved by Dr. Ziauddin University's Ethical Review Board.

Informed consent statement: All study participants, or their legal guardian, provided informed written consent prior to study enrollment.

Conflict-of-interest statement: All authors declare that they have no conflict of interest.

Data sharing statement: No additional data are available.

STROBE statement: The authors have read the STROBE Statement—checklist of items, and the manuscript was prepared and revised according to the STROBE Statement—checklist of items.

Open-Access: This article is an open-access article that was selected by an in-house editor and fully peer-reviewed by external reviewers. It is distributed in accordance with the Creative Commons Attribution NonCommercial (CC BY-NC 4.0) license, which permits others to distribute, remix, adapt, build upon this work non-commercially, and license their derivative works on different terms, provided the original work is properly cited and the use is non-commercial. See: <https://creativecommons.org/licenses/by-nc/4.0/>

Country/Territory of origin: Pakistan

ORCID number: Zaigham Abbas 0000-0002-9513-5324.

S-Editor: Chen YL

L-Editor: A

P-Editor: Zhao YQ

REFERENCES

- 1 Ferlay J, Ervik M, Lam F, Colombet M, Mery L, Piñeros M, Znaor A, Soerjomataram I, Bray F. Global Cancer Observatory: Cancer Today. Lyon, France: International Agency for Research on Cancer. 2020. [cited 10 July 2023]. Available from: <https://gco.iarc.fr/today>
- 2 Singal AG, Llovet JM, Yarchoan M, Mehta N, Heimbach JK, Dawson LA, Jou JH, Kulik LM, Agopian VG, Marrero JA, Mendiratta-Lala M, Brown DB, Rilling WS, Goyal L, Wei AC, Taddei TH. AASLD Practice Guidance on prevention, diagnosis, and treatment of hepatocellular carcinoma. *Hepatology* 2023; **78**: 1922-1965 [PMID: 37199193 DOI: 10.1097/HEP.000000000000466]
- 3 Reig M, Forner A, Rimola J, Ferrer-Fàbrega J, Burrel M, Garcia-Criado Á, Kelley RK, Galle PR, Mazzaferro V, Salem R, Sangro B, Singal AG, Vogel A, Fuster J, Ayuso C, Bruix J. BCLC strategy for prognosis prediction and treatment recommendation: The 2022 update. *J Hepatol* 2022; **76**: 681-693 [PMID: 34801630 DOI: 10.1016/j.jhep.2021.11.018]
- 4 Kim SH, Moon DB, Kim WJ, Kang WH, Kwon JH, Jwa EK, Cho HD, Ha SM, Chung YK, Lee SG. Preoperative prognostic values of α -fetoprotein (AFP) and protein induced by vitamin K absence or antagonist-II (PIVKA-II) in patients with hepatocellular carcinoma for living donor liver transplantation. *Hepatobiliary Surg Nutr* 2016; **5**: 461-469 [PMID: 28124000 DOI: 10.21037/hbsn.2016.11.05]
- 5 Chi X, Jiang L, Yuan Y, Huang X, Yang X, Hochwald S, Liu J, Huang H. A comparison of clinical pathologic characteristics between alpha-fetoprotein negative and positive hepatocellular carcinoma patients from Eastern and Southern China. *BMC Gastroenterol* 2022; **22**: 202

- [PMID: 35461226 DOI: 10.1186/s12876-022-02279-w]
- 6 **Liebman HA**, Furie BC, Tong MJ, Blanchard RA, Lo KJ, Lee SD, Coleman MS, Furie B. Des-gamma-carboxy (abnormal) prothrombin as a serum marker of primary hepatocellular carcinoma. *N Engl J Med* 1984; **310**: 1427-1431 [PMID: 6201741 DOI: 10.1056/NEJM198405313102204]
 - 7 **Seo SI**, Kim HS, Kim WJ, Shin WG, Kim DJ, Kim KH, Jang MK, Lee JH, Kim JS, Kim HY, Lee MS, Park CK. Diagnostic value of PIVKA-II and alpha-fetoprotein in hepatitis B virus-associated hepatocellular carcinoma. *World J Gastroenterol* 2015; **21**: 3928-3935 [PMID: 25852278 DOI: 10.3748/wjg.v21.i13.3928]
 - 8 **Zakhary NI**, Khodeer SM, Shafik HE, Abdel Malak CA. Impact of PIVKA-II in diagnosis of hepatocellular carcinoma. *J Adv Res* 2013; **4**: 539-546 [PMID: 25685463 DOI: 10.1016/j.jare.2012.10.004]
 - 9 **Poté N**, Cauchy F, Albuquerque M, Voitot H, Belghiti J, Castera L, Puy H, Bedossa P, Paradis V. Performance of PIVKA-II for early hepatocellular carcinoma diagnosis and prediction of microvascular invasion. *J Hepatol* 2015; **62**: 848-854 [PMID: 25450201 DOI: 10.1016/j.jhep.2014.11.005]
 - 10 **Likhitsup A**, Parikh ND. Economic Implications of Hepatocellular Carcinoma Surveillance and Treatment: A Guide for Clinicians. *Pharmacoeconomics* 2020; **38**: 5-24 [PMID: 31573053 DOI: 10.1007/s40273-019-00839-9]
 - 11 **Trevisani F**, D'Intino PE, Morselli-Labate AM, Mazzella G, Accogli E, Caraceni P, Domenicali M, De Notariis S, Roda E, Bernardi M. Serum alpha-fetoprotein for diagnosis of hepatocellular carcinoma in patients with chronic liver disease: influence of HBsAg and anti-HCV status. *J Hepatol* 2001; **34**: 570-575 [PMID: 11394657 DOI: 10.1016/s0168-8278(00)00053-2]
 - 12 **Nikolova D**. Alpha Fetoprotein and Hepatocellular Carcinoma: An Opinion. *BJSTR* 2019; **12** [DOI: 10.26717/BJSTR.2019.12.002316]
 - 13 **Gupta S**, Bent S, Kohlwes J. Test characteristics of alpha-fetoprotein for detecting hepatocellular carcinoma in patients with hepatitis C. A systematic review and critical analysis. *Ann Intern Med* 2003; **139**: 46-50 [PMID: 12834318 DOI: 10.7326/0003-4819-139-1-200307010-00012]
 - 14 **Xing H**, Zheng YJ, Han J, Zhang H, Li ZL, Lau WY, Shen F, Yang T. Protein induced by vitamin K absence or antagonist-II versus alpha-fetoprotein in the diagnosis of hepatocellular carcinoma: A systematic review with meta-analysis. *Hepatobiliary Pancreat Dis Int* 2018; **17**: 487-495 [PMID: 30257796 DOI: 10.1016/j.hbpd.2018.09.009]
 - 15 **Hafeez Bhatti AB**, Dar FS, Waheed A, Shafique K, Sultan F, Shah NH. Hepatocellular Carcinoma in Pakistan: National Trends and Global Perspective. *Gastroenterol Res Pract* 2016; **2016**: 5942306 [PMID: 26955390 DOI: 10.1155/2016/5942306]
 - 16 **Parkash O**, Hamid S. Next big threat for Pakistan Hepatocellular Carcinoma (HCC). *J Pak Med Assoc* 2016; **66**: 735-739 [PMID: 27339578]
 - 17 **Liu S**, Sun L, Yao L, Zhu H, Diao Y, Wang M, Xing H, Lau WY, Guan M, Pawlik TM, Shen F, Xu M, Tong X, Yang T. Diagnostic Performance of AFP, AFP-L3, or PIVKA-II for Hepatitis C Virus-Associated Hepatocellular Carcinoma: A Multicenter Analysis. *J Clin Med* 2022; **11** [PMID: 36079006 DOI: 10.3390/jcm11175075]
 - 18 **Perne MG**, Sitar-Tăut AV, Alexescu TG, Ciumărnean L, Milaciu MV, Coste SC, Vlad CV, Cozma A, Sitar-Tăut DA, Orășan OH, Crăciun A. Diagnostic Performance of Extrahepatic Protein Induced by Vitamin K Absence in the Hepatocellular Carcinoma: A Systematic Review and Meta-Analysis. *Diagnostics (Basel)* 2023; **13** [PMID: 36899960 DOI: 10.3390/diagnostics13050816]
 - 19 **Masuda T**, Beppu T, Okabe H, Nitta H, Imai K, Hayashi H, Chikamoto A, Yamamoto K, Ikeshima S, Kuramoto M, Shimada S, Baba H. Predictive factors of pathological vascular invasion in hepatocellular carcinoma within 3 cm and three nodules without radiological vascular invasion. *Hepatol Res* 2016; **46**: 985-991 [PMID: 26670198 DOI: 10.1111/hepr.12637]
 - 20 **Xu F**, Zhang L, He W, Song D, Ji X, Shao J. The Diagnostic Value of Serum PIVKA-II Alone or in Combination with AFP in Chinese Hepatocellular Carcinoma Patients. *Dis Markers* 2021; **2021**: 8868370 [PMID: 33628341 DOI: 10.1155/2021/8868370]
 - 21 **Saitta C**, Raffa G, Alibrandi A, Brancatelli S, Lombardo D, Tripodi G, Raimondo G, Pollicino T. PIVKA-II is a useful tool for diagnostic characterization of ultrasound-detected liver nodules in cirrhotic patients. *Medicine (Baltimore)* 2017; **96**: e7266 [PMID: 28658121 DOI: 10.1097/MD.00000000000007266]
 - 22 **Johnson PJ**, Pirrie SJ, Cox TF, Berhane S, Teng M, Palmer D, Morse J, Hull D, Patman G, Kagebayashi C, Hussain S, Graham J, Reeves H, Satomura S. The detection of hepatocellular carcinoma using a prospectively developed and validated model based on serological biomarkers. *Cancer Epidemiol Biomarkers Prev* 2014; **23**: 144-153 [PMID: 24220911 DOI: 10.1158/1055-9965.EPI-13-0870]
 - 23 **Berhane S**, Toyoda H, Tada T, Kumada T, Kagebayashi C, Satomura S, Schweitzer N, Vogel A, Manns MP, Benckert J, Berg T, Ebker M, Best J, Dechêne A, Gerken G, Schlaak JF, Weinmann A, Wörns MA, Galle P, Yeo W, Mo F, Chan SL, Reeves H, Cox T, Johnson P. Role of the GALAD and BALAD-2 Serologic Models in Diagnosis of Hepatocellular Carcinoma and Prediction of Survival in Patients. *Clin Gastroenterol Hepatol* 2016; **14**: 875-886.e6 [PMID: 26775025 DOI: 10.1016/j.cgh.2015.12.042]
 - 24 **Piratvisuth T**, Hou J, Tanwandee T, Berg T, Vogel A, Trojan J, De Toni EN, Kudo M, Eiblmaier A, Klein HG, Hegel JK, Madin K, Kroeniger K, Sharma A, Chan HLY. Development and clinical validation of a novel algorithmic score (GAAD) for detecting HCC in prospective cohort studies. *Hepatol Commun* 2023; **7** [PMID: 37938100 DOI: 10.1097/HCC9.0000000000000317]



Published by **Baishideng Publishing Group Inc**
7041 Koll Center Parkway, Suite 160, Pleasanton, CA 94566, USA

Telephone: +1-925-3991568

E-mail: office@baishideng.com

Help Desk: <https://www.f6publishing.com/helpdesk>

<https://www.wjgnet.com>

