



Interest of thoracic ultrasound after cardiac surgery or interventional cardiology

Martin Boussuges, Philippe Blanc, Fabienne Bregeon, Alain Boussuges

Specialty type: Cardiac and cardiovascular systems

Provenance and peer review: Invited article; Externally peer reviewed.

Peer-review model: Single blind

Peer-review report's scientific quality classification

Grade A (Excellent): A
Grade B (Very good): 0
Grade C (Good): 0
Grade D (Fair): 0
Grade E (Poor): 0

P-Reviewer: Lee SS, South Korea

Received: December 22, 2023

Peer-review started: December 22, 2023

First decision: January 17, 2024

Revised: January 19, 2024

Accepted: February 20, 2024

Article in press: February 20, 2024

Published online: March 26, 2024



Martin Boussuges, Service de Pneumologie, Centre Hospitalier Universitaire Sud Reunion, Saint Pierre 97410, Ile de la Reunion, France

Philippe Blanc, Department of Cardiac and Pulmonary Rehabilitation, Ste Clotilde & YlangYlang Rehabilitation Center, Sainte Clotilde 97491, Ile de la Reunion, France

Fabienne Bregeon, Alain Boussuges, Service d'Explorations Fonctionnelles Respiratoires, Centre Hospitalier Universitaire Nord, Assistance Publique des Hôpitaux de Marseille, Marseille 13015, France

Fabienne Bregeon, Institut Hospitalo-Universitaire-Méditerranée Infection, Aix Marseille Université, Marseille 13005, France

Alain Boussuges, Center for Cardiovascular and Nutrition Research, Aix Marseille Université, Institut National de la Santé et de la Recherche Médicale, Institut National de Recherche pour l'Agriculture, l'Alimentation et l'Environnement, Marseille 13005, France

Corresponding author: Alain Boussuges, MD, PhD, Professor, Center for Cardiovascular and Nutrition Research, Aix Marseille Université, Faculté des Sciences Médicales et Paramédicales, 27 bd Jean Moulin, Marseille 13005, France. alain.boussuges@univ-amu.fr

Abstract

Thoracic ultrasound has attracted much interest in detecting pleural effusion or pulmonary consolidation after cardiac surgery. In 2016, Trovato reported, in the *World Journal of Cardiology*, the interest of using, in addition to echocardiography, thoracic ultrasound. In this editorial, we highlight the value of assessing diaphragm function after cardiac surgery and interventional cardiology procedures. Various factors are able to impair diaphragm function after such interventions. Diaphragm motion may be decreased by chest pain secondary to sternotomy, pleural effusion or impaired muscle function. Hemidiaphragmatic paralysis may be secondary to phrenic nerve damage complicating cardiac surgery or atrial fibrillation ablation. Diagnosis may be delayed. Indeed, respiratory troubles induced by diaphragm dysfunction are frequently attributed to pre-existing heart disease or pulmonary complications secondary to surgery. In addition, elevated hemidiaphragm secondary to diaphragm dysfunction is sometimes not observed on chest X-ray performed in supine position in the intensive care unit. Analysis of diaphragm function by ultrasound during the recovery period appears essential. Both hemidiaphragms can be studied by two complementary ultrasound methods. The mobility of each hemidiaphragms is

measured by M-mode ultrasonography. In addition, recording the percentage of inspiratory thickening provides important information about the quality of muscle function. These two approaches make it possible to detect hemidiaphragm paralysis or dysfunction. Such a diagnosis is important because persistent diaphragm dysfunction after cardiac surgery has been shown to be associated with adverse respiratory outcome. Early respiratory physiotherapy is able to improve respiratory function through strengthening of the inspiratory muscles *i.e.* diaphragm and accessory inspiratory muscles.

Key Words: Ultrasonography; Diaphragm; Phrenic nerve; Hemidiaphragm; Thickening fraction; Physiotherapy

©The Author(s) 2024. Published by Baishideng Publishing Group Inc. All rights reserved.

Core Tip: Diaphragm dysfunction can be secondary to cardiac surgery or atrial fibrillation ablation *via* phrenic nerve injury. In patients with comorbidities such as obesity and cardiac or respiratory diseases, unilateral diaphragm paralysis may be poorly tolerated. Diaphragm ultrasound is the most appropriate tool for early diagnosis.

Citation: Boussuges M, Blanc P, Bregeon F, Boussuges A. Interest of thoracic ultrasound after cardiac surgery or interventional cardiology. *World J Cardiol* 2024; 16(3): 118-125

URL: <https://www.wjgnet.com/1949-8462/full/v16/i3/118.htm>

DOI: <https://dx.doi.org/10.4330/wjc.v16.i3.118>

INTRODUCTION

The diaphragm is the main inspiratory muscle and contributes to 60%-70% of the total ventilation at rest. It is a musculotendinous structure (2-4 mm) with a central tendinous portion and a peripheral muscular portion. It includes two hemidiaphragms: The right with a dome positioned higher than the left. Motor innervation of the diaphragm comes from two phrenic nerves formed from the C3-C5 nerve roots. The left and right phrenic nerves cross the neck and thorax between the mediastinal surface of the parietal pleura and the fibrous pericardium to reach the corresponding hemidiaphragm. The left phrenic nerve is close to the subclavian artery and passes in front of the pericardial sac of the left ventricle. The right phrenic nerve runs superficial to the anterior scalene muscle and right subclavian artery and passes over the right atrium and right ventricle. Arterial blood flow to the diaphragm comes from collaterals of the internal mammary artery, collaterals of the abdominal aorta, and vessels originating from intercostal arteries. During contraction, the diaphragm shortens and moves caudally, leading to an expansion of the thoracic cavity. This phenomenon increases abdominal pressure and decreases alveolar pressure below atmospheric pressure resulting in airflow into the lungs[1]. Various procedures used in patients with heart diseases can impair diaphragmatic function. Diaphragm dysfunction was exceptionally reported after central vein cannulation and pacemaker battery change[2,3]. In contrast, this was regularly observed after cardiac surgery and atrial fibrillation ablation[4,5]. We underline in this editorial the interest of assessing diaphragm function after such procedures.

DIAPHRAGM DYSFUNCTION AFTER CARDIAC SURGERY

Impaired diaphragmatic function was reported in a significant percentage of patients after cardiac surgery. Depending on the detection method and the delay from the surgery, diaphragm dysfunction has been variously estimated: 21% for Dimopoulou *et al*[6], 38% for Bruni *et al*[7], 46% for DeVita *et al*[8], and 75% for Moury *et al*[9]. In a recent observational study[10], symptomatic diaphragm dysfunction was found in 272 out of 3577 patients (7.6%). In our experience (unpublished study), the percentage of diaphragm dysfunction in patients admitted in a cardiac rehabilitation center after cardiac surgery was 15% (39 out of 264 patients). Diaphragm ultrasound detected weakness in 10% of cases and hemidiaphragm paralysis in 5%. Various mechanisms may explain diaphragm dysfunction in these patients. Diaphragmatic motion may be reduced by chest pain secondary to sternotomy, pleural effusion or impaired muscle function[11]. Furthermore, phrenic nerve damage is a well-known, complication of cardiac surgery. It has been shown that the phrenic nerve can be injured through thermal lesions secondary to topical cardiac cooling with ice-cold solution in the pericardium. To reduce the risk of injury, the use of insulation pads placed between the heart and the left pericardium has been proposed to protect the phrenic nerve from hypothermic surgery[12,13]. The use of warm-blood cardioplegia has also demonstrated its interest in reducing the risk of diaphragm paralysis[14]. However, other mechanisms may explain phrenic nerve damage during cardiac surgery. During coronary artery bypass grafting, phrenic nerve injury may be secondary to direct surgical trauma during dissection of the internal mammary artery (IMA) or indirect injury due to stretching by the sternal retractor[15]. In addition, IMA harvesting may result in decreased blood flow to the phrenic nerve through ligation of some branches such as the pericardiophrenic artery. These mechanisms could explain the increased risk of phrenic nerve dysfunction in patients who underwent IMA harvesting compared to the group that did

not undergo IMA harvesting[16]. Inflammation secondary to cardiopulmonary bypass surgery may also be involved in the development of diaphragm dysfunction *via* significant production of reactive oxygen species and proinflammatory and pro-apoptotic signaling pathways activation[17].

DIAPHRAGM DYSFUNCTION INDUCED BY ATRIAL FIBRILLATION ABLATION

Minimally invasive treatment of atrial fibrillation appeared in the late 1990s and is now widely used as a safe alternative to antiarrhythmic drugs. Procedures have improved while the number of patients eligible for such treatments has increased.

The most commonly used fibrillation ablation techniques are thermal energy sources with cold (cryoablation around -55°C) or heat (radiofrequency heating around +55°C). Due to the short distance between the ablation site and the phrenic nerve, thermal injury is not uncommon (mainly on the right side) resulting in diaphragmatic dysfunction. Electromyography-guided phrenic nerve monitoring has been proposed to prevent serious phrenic nerve injury during superior vena cava isolation. Detection of reduced contraction of the diaphragm during the procedure leads to the change in the ablation trajectory[18,19]. Despite the development of prevention strategies, new sophisticated devices and experienced operators, phrenic nerve injuries remain a possible outcome of up to 15% for early transient paralysis of the diaphragm, which usually disappears at the end of the procedure. Persistent symptomatic diaphragmatic paralysis is rare (reported in less than 1% of cases). A large population study from the "Netherlands Heart Registration" focused on persistent diaphragm dysfunction (> 24 h) among 7433 procedures performed between 2016 and 2017[20]. The incidence of persistent diaphragm paralysis was 0.7%, the risk being increased in women. In a recent prospective, multicenter study conducted in 375 subjects comparing cryoballoon to radiofrequency, data showed that cryoablation has the highest level of phrenic nerve injury with 7.20% transient paralysis compared to 3.20% for radiofrequency[21]. Today, a new non-thermal energy modality, called pulse field ablation (PFA) therapy has emerged. PFA therapy involves the application of high voltage levels to tissues in order to induce hyperpermeabilization of cell membranes and cell death through the mechanism of irreversible electroporation. This procedure is believed to be more selective than thermal procedures and may be less damaging to the phrenic nerve[22].

DETECTION OF DIAPHRAGM DYSFUNCTION BY ULTRASOUND

Chest ultrasound has gained much interest in detecting pleural effusion and pulmonary consolidation or edema after cardiac surgery. In 2016, Trovato[23] reported, in the *World Journal of Cardiology*, the interest of using, in addition to echocardiography, thoracic ultrasound for cardiologists. Since the frequency of diaphragm dysfunction is significant after cardiac surgery and atrial fibrillation ablation, the ultrasound analysis of diaphragm function is important.

Ultrasound methods

The two hemidiaphragms can be studied by two complementary ultrasound methods. Diaphragm mobility can be recorded by a sub-costal approach using a cardiac probe[24-26]. Excursions of both hemidiaphragms are measured by M-mode ultrasonography during various volitional maneuvers such as quiet breathing (Figure 1) voluntary sniffing and deep inspiration. In addition, it is useful to measure the thickness changes at the zone of apposition during breathing (Figure 2, Video) by a superficial probe using B-mode[27]. The percentage of thickening during inspiration provides important information about the quality of the muscle function of the diaphragm[28]. These two approaches make it possible to detect paralysis or weakness of hemidiaphragm.

Diagnosis of hemidiaphragm paralysis

In patients with unilateral diaphragmatic paralysis, hemidiaphragm movement is absent or paradoxical when breathing at rest[29,30]. During voluntary sniffing, a paradoxical movement (*i.e.* cranial) of the hemidiaphragm (Figure 3) is reported using M-mode ultrasonography[29,30]. During deep inspiration, a biphasic movement can be recorded with a first paradoxical movement followed by a cranio-caudal excursion[30]. The study of inspiratory thickening is important to support the results of the diaphragm excursion analysis. The failure of the paralyzed diaphragm to thicken results in a decrease in the thickening fraction (TF) calculated as the difference between the diaphragm thickness measured at the end of maximal inspiration and the diaphragm thickness at the end of expiration divided by the diaphragm thickness at the end of expiration $\times 100$. No significant thickening (TF less than 20%) or thinning of paralyzed hemidiaphragm is observed [31].

Diagnosis of diaphragm weakness

In some patients, diaphragm dysfunction occurred without complete paralysis *i.e.* diaphragm weakness. Diaphragm weakness can be detected using normal values of excursions and thickening previously determined from the study of healthy controls[32,33]. First, no criteria for complete paralysis should be recorded by ultrasound: No paradoxical movement should be observed during the various maneuvers and the TF should be greater than 20%. Secondly, excursions during deep inspiration should be below the lower limit of normal (LLN) depending on the side and gender according to the reference values[32].

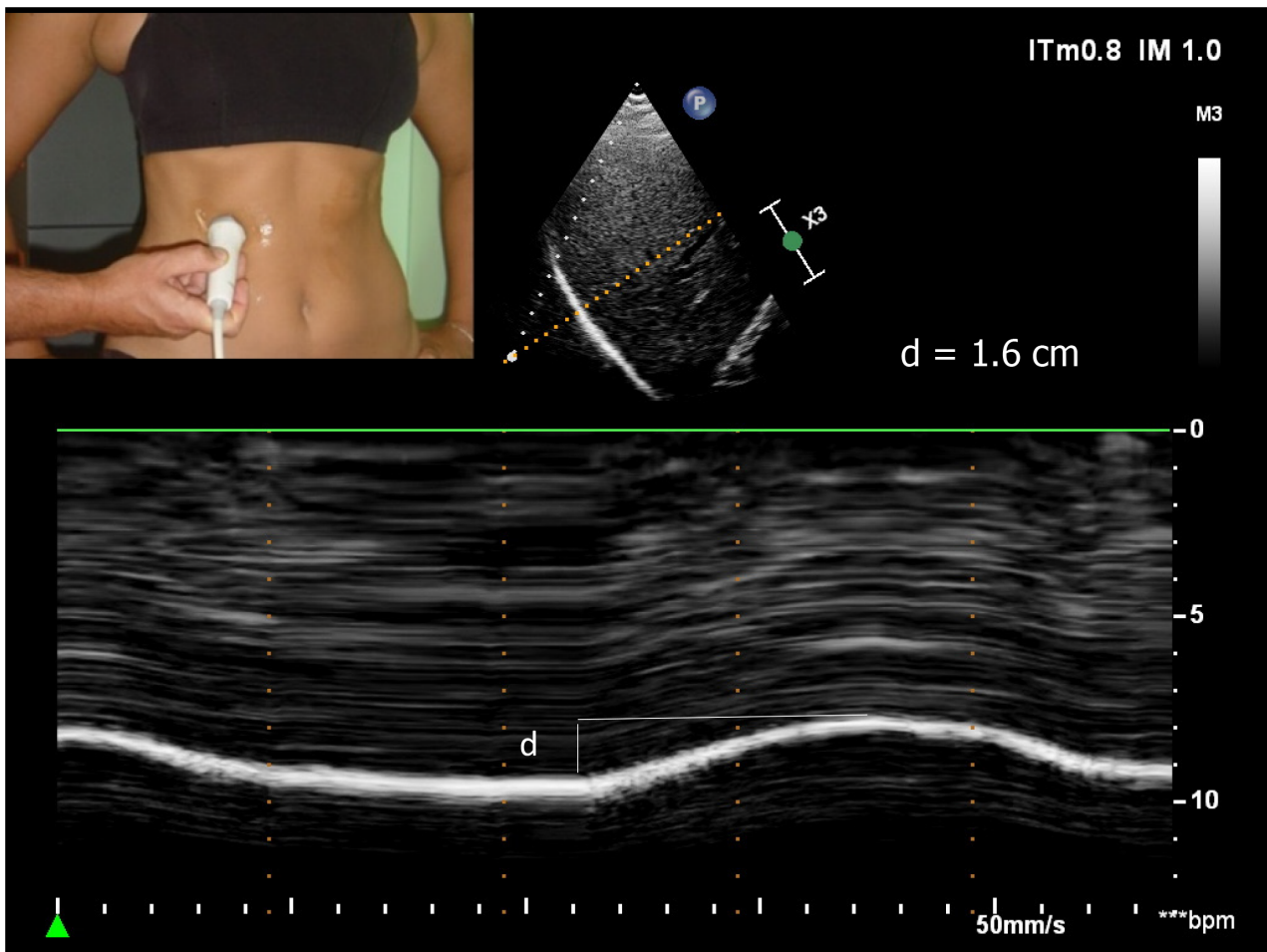


Figure 1 Diaphragmatic motion recorded by M-mode ultrasonography during quiet breathing d: Measurement of diaphragm excursion = 1.6 cm.

Severity of the weakness may be based on the decrease of the excursion from the lower limit of the normal and the measurement of the thickening fraction[34].

Patients can be classified as follows: (1) Mild hemidiaphragm dysfunction when the excursion is slightly below the lower limit of normal during deep inspiration (excursion > LLN - 1 cm) and a normal or slightly decreased thickening fraction (> 40%); (2) Severe hemidiaphragm dysfunction in patients with a marked decrease in hemidiaphragm excursion (< LLN - 1 cm) associated with a marked decrease in thickening fraction (< 40%).

CLINICAL CONSEQUENCES OF DIAPHRAGM DYSFUNCTION

The complete loss of function of one hemidiaphragm leads to a restrictive syndrome with a decrease in vital capacity of about 25%. After unilateral diaphragm paralysis, a compensatory increase in neural drive to the functioning hemidiaphragm was demonstrated[35], leading to large excursions to the healthy side[36]. The activity of accessory inspiratory muscles is also increased[37].

Disorders induced by diaphragm paralysis can take a wide variety of clinical pictures[38]. Bilateral diaphragm paralysis leads to respiratory failure most often requiring ventilatory support. In case of unilateral hemidiaphragm dysfunction, the compensatory mechanism is effective in patients without severe comorbidities and clinical disorders remain weak. Most often, dyspnea is mild and appears during exercise or in supine position. In contrast, in patients with obesity or with severe pre-existing cardiac or respiratory disease, the impairment in respiratory function leads to clinical disorders that can reach respiratory failure. After cardiac surgery, diaphragm dysfunction is associated with a risk of postoperative pneumonia, mechanical ventilation (non-invasive and invasive ventilation) and increased length of stay in the intensive care unit[39].

Diagnosis may be delayed, indeed, respiratory disorders induced by diaphragm dysfunction are frequently attributed to pre-existing heart disease or pulmonary complications secondary to the procedure. Furthermore, elevated hemidiaphragm secondary to diaphragm dysfunction is sometimes not seen on chest X-ray performed in supine position in the intensive care unit. Diagnosis is sometimes made later, for exemple when admitted to a cardiac rehabilitation center[40]. It remains important because persistent diaphragm dysfunction is associated with late respiratory complications[39].

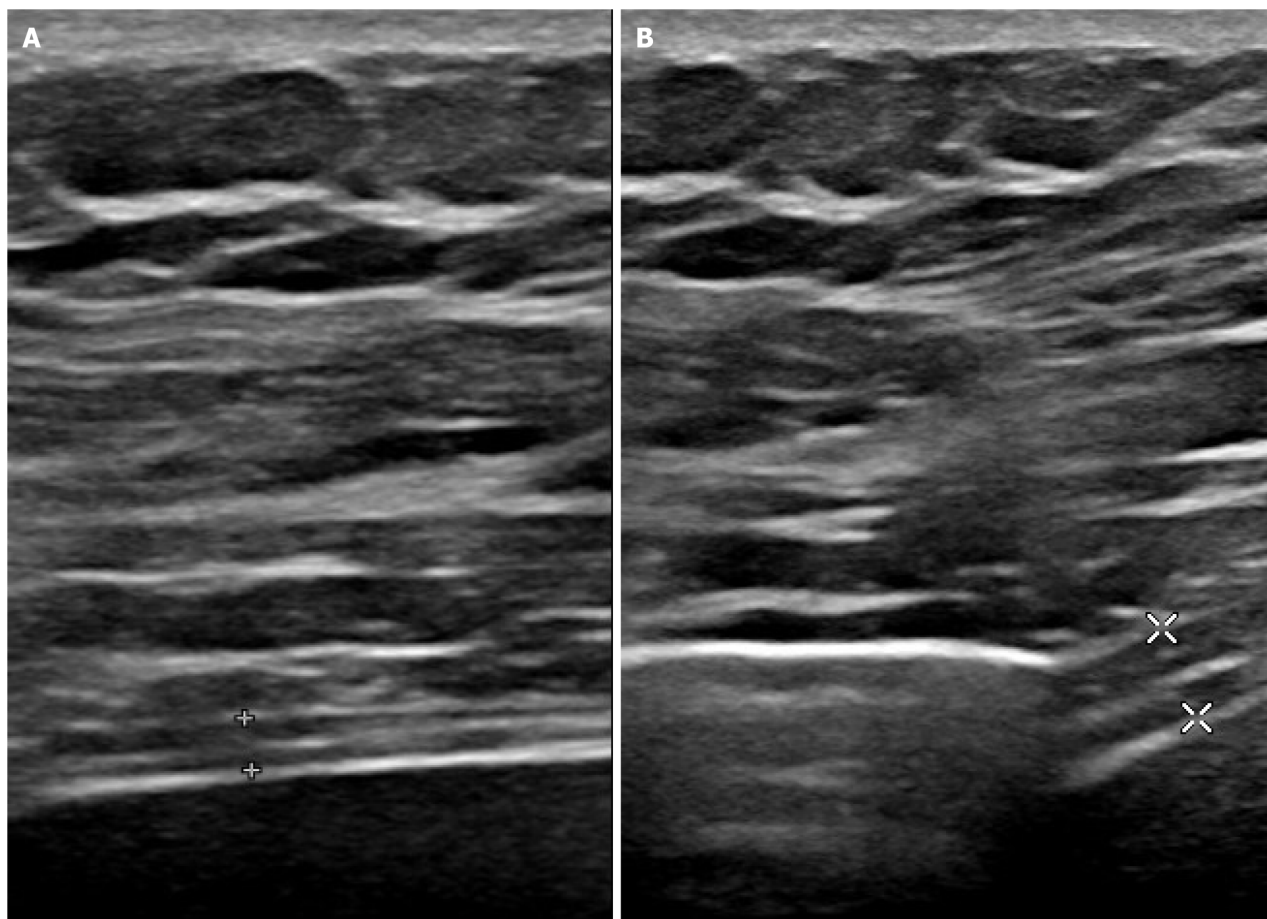


Figure 2 Measurement of thickening fraction using B mode ultrasonography. A: End of expiration (1.7 mm); B: End of maximal inspiration (3.8 mm). Measurement of diaphragm thickness at expiration (1.7 mm), and at deep inspiration (3.8 mm) – here thickening fraction = $(3.8 - 1.7) / 1.7 = 123\%$.

In addition, high frequency of obstructive sleep apnea (OSA) has been reported in patients with diaphragm dysfunction[41]. It is therefore important to seek sleep apnea in these patients because it is recognized that OSA is a risk factor for cardiovascular disease[42].

Less frequently, right-to-left shunt was associated with right hemidiaphragm paralysis[43,44]. The mechanism was a redirection of blood flow from the inferior vena cava directly through the patent foramen ovale secondary to a distortion of cardiac anatomy induced by hemidiaphragmatic paralysis. In patients with hypoxemia, closure of the patent foramen ovale may be necessary[45].

TREATMENT

Treatment of diaphragm dysfunction is mainly based on respiratory physiotherapy. In unilateral diaphragm paralysis, inspiratory muscle training improves clinical condition through strengthening of healthy hemidiaphragm and accessory inspiratory muscles[46,47]. The long-term prognosis of hemidiaphragm paralysis is usually favorable with a decrease in respiratory disorders due either to the adaptation of healthy inspiratory muscles, or to the spontaneous improvement of diaphragmatic function.

In a population of patients with diaphragm paralysis of various etiologies, Gayan-Ramirez *et al*[48] reported functional recovery in the first year after diagnosis in 43% of cases and in two years in 52% of cases. After pediatric cardiac surgery complicated by phrenic nerve injury, recovery was documented in about 55% of children over a median follow-up period of 353 d[49]. In patients with hemidiaphragm paralysis secondary to atrial fibrillation ablation, after a mean follow-up of 3 years, 66% of the study population had complete recovery, 17% had partial recovery, and 17% had no recovery[5]. The average recovery time was 4 months after injury. In cases of poor tolerance of diaphragm paralysis, mechanical ventilatory support such as non-invasive ventilation may be required[50]. In patients with hemidiaphragm paralysis having no recovery and suffering from disabling respiratory disorders, diaphragm plication can be proposed. Surgery is performed through open thoracotomy or video-assisted thoracoscopy[51]. Plication of hemidiaphragm reduces dyspnea, and increases both lung function test and exercise capacity[52,53]. The improvement in quality of life persists for a long time. It is therefore recommended to consider diaphragm plication in patients with unilateral diaphragm paralysis who have an impairment of quality of life secondary to chronic dyspnea.

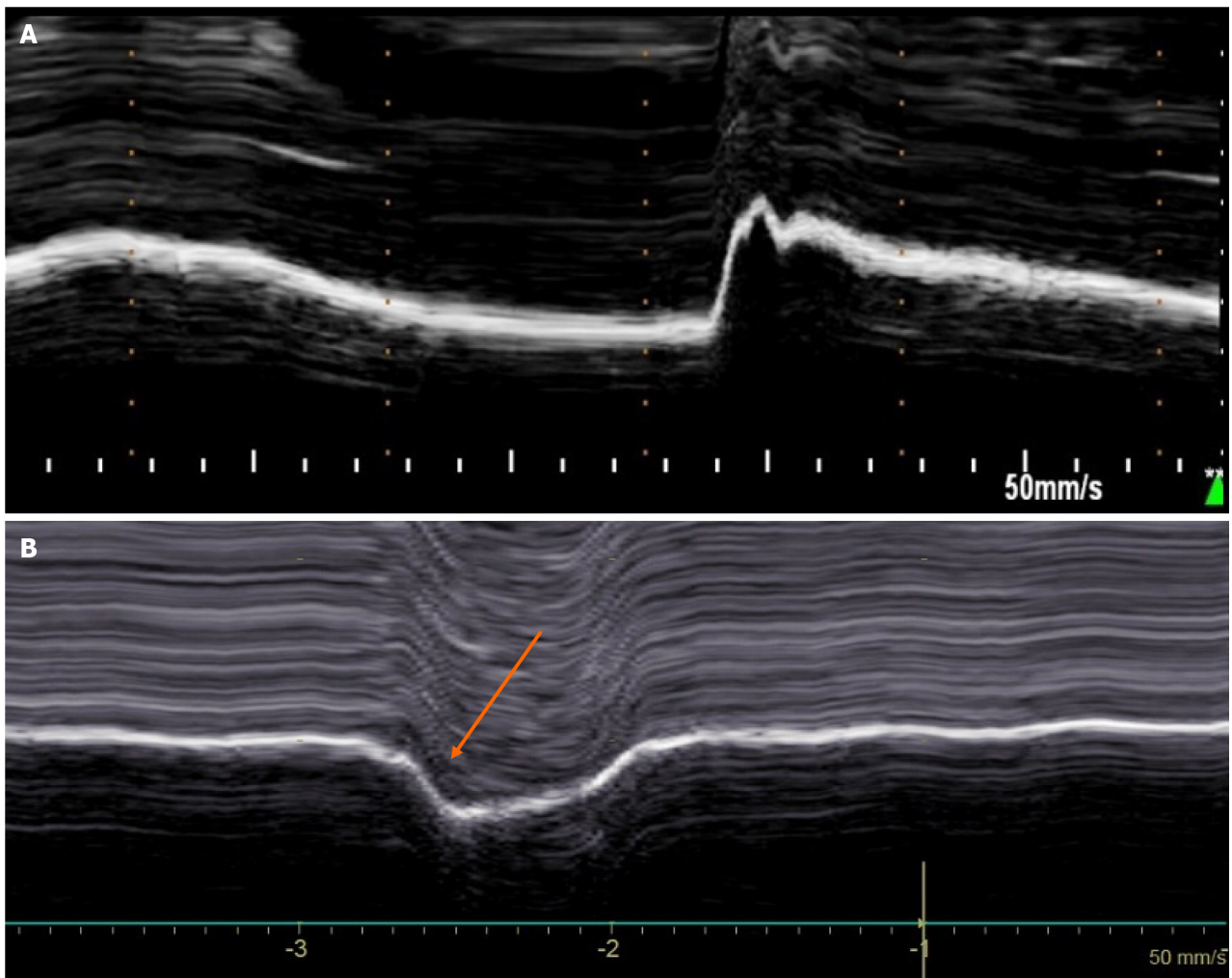


Figure 3 Diaphragmatic motion recorded by M-mode ultrasonography during voluntary sniffing. A: Normal motion; B: Paradoxical movement (arrow) in patient with hemidiaphragm paralysis.

CONCLUSION

Cardiac surgery and atrial fibrillation ablation can damage the phrenic nerve causing diaphragm dysfunction. Clinical disorders can be wrongly attributed to pre-existing heart or respiratory diseases, so systematic evaluation of diaphragm function by ultrasound after a procedure at risk of phrenic nerve injury is particularly useful. In such patients, respiratory physiotherapy is able to improve respiratory function through the strengthening of inspiratory muscles. Repeated ultrasound examinations should be performed to monitor potential recovery of diaphragm function. In case of lack of recovery and persistent disabling respiratory disorders, diaphragm plication can be proposed.

FOOTNOTES

Author contributions: The article project was designed by Boussuges A; Boussuges M, Blanc P, Bregeon F, and Boussuges A contributed equally to the article by conducting a literature review, drafting the article, making critical revisions and approving the final version.

Conflict-of-interest statement: All authors have no conflicts of interest to disclose.

Open-Access: This article is an open-access article that was selected by an in-house editor and fully peer-reviewed by external reviewers. It is distributed in accordance with the Creative Commons Attribution NonCommercial (CC BY-NC 4.0) license, which permits others to distribute, remix, adapt, build upon this work non-commercially, and license their derivative works on different terms, provided the original work is properly cited and the use is non-commercial. See: <https://creativecommons.org/licenses/by-nc/4.0/>

Country/Territory of origin: France

ORCID number: Martin Boussuges 0009-0004-6253-4929; Philippe Blanc 0009-0005-2219-7881; Fabienne Bregeon 0000-0002-9244-5474; Alain Boussuges 0000-0001-6176-6200.

S-Editor: Liu JH

L-Editor: A

P-Editor: Zhao S

REFERENCES

- 1 **Benditt JO.** Esophageal and gastric pressure measurements. *Respir Care* 2005; **50**: 68-75; discussion 75 [PMID: 15636646]
- 2 **Shawyer A,** Chippington S, Quayam S, Schulze-Neick I, Roebuck D. Phrenic nerve injury after image-guided insertion of a tunnelled right internal jugular central venous catheter. *Pediatr Radiol* 2012; **42**: 875-877 [PMID: 22057361 DOI: 10.1007/s00247-011-2269-y]
- 3 **Harris K,** Maniatis G, Siddiqui F, Maniatis T. Phrenic nerve injury and diaphragmatic paralysis following pacemaker pulse generator replacement. *Heart Lung* 2013; **42**: 65-66 [PMID: 23083538 DOI: 10.1016/j.hrtlng.2012.09.002]
- 4 **Aguiere VJ,** Sinha P, Zimmet A, Lee GA, Kwa L, Rosenfeldt F. Phrenic nerve injury during cardiac surgery: mechanisms, management and prevention. *Heart Lung Circ* 2013; **22**: 895-902 [PMID: 23948287 DOI: 10.1016/j.hlc.2013.06.010]
- 5 **Sacher F,** Monahan KH, Thomas SP, Davidson N, Adragao P, Sanders P, Hocini M, Takahashi Y, Rotter M, Rostock T, Hsu LF, Clémenty J, Haïssaguerre M, Ross DL, Packer DL, Jaïs P. Phrenic nerve injury after atrial fibrillation catheter ablation: characterization and outcome in a multicenter study. *J Am Coll Cardiol* 2006; **47**: 2498-2503 [PMID: 16781380 DOI: 10.1016/j.jacc.2006.02.050]
- 6 **Dimopoulou I,** Daganou M, Dafni U, Karakatsani A, Khoury M, Geroulanos S, Jordanoglou J. Phrenic nerve dysfunction after cardiac operations: electrophysiologic evaluation of risk factors. *Chest* 1998; **113**: 8-14 [PMID: 9440560 DOI: 10.1378/chest.113.1.8]
- 7 **Bruni A,** Garofalo E, Pasin L, Serraino GF, Cammarota G, Longhini F, Landoni G, Lembo R, Mastroroberto P, Navalesi P; MaGIC (Magna Graecia Intensive care and Cardiac surgery) Group. Diaphragmatic Dysfunction After Elective Cardiac Surgery: A Prospective Observational Study. *J Cardiothorac Vasc Anesth* 2020; **34**: 3336-3344 [PMID: 32653270 DOI: 10.1053/j.jvca.2020.06.038]
- 8 **DeVita MA,** Robinson LR, Rehder J, Hattler B, Cohen C. Incidence and natural history of phrenic neuropathy occurring during open heart surgery. *Chest* 1993; **103**: 850-856 [PMID: 8449080 DOI: 10.1378/chest.103.3.850]
- 9 **Moury PH,** Cuisinier A, Durand M, Bosson JL, Chavanon O, Payen JF, Jaber S, Albaladejo P. Diaphragm thickening in cardiac surgery: A perioperative prospective ultrasound study. *Ann Intensive Care* 2019; **9**: 50 [PMID: 31016412 DOI: 10.1186/s13613-019-0521-z]
- 10 **Laghlam D,** Lê MP, Srouf A, Monsonego R, Estagnasié P, Brusset A, Squara P. Diaphragm Dysfunction After Cardiac Surgery: Reappraisal. *J Cardiothorac Vasc Anesth* 2021; **35**: 3241-3247 [PMID: 33736912 DOI: 10.1053/j.jvca.2021.02.023]
- 11 **Mali S,** Haghaninejad H. Pulmonary complications following cardiac surgery. *Arch Med Sci Atheroscler Dis* 2019; **4**: e280-e285 [PMID: 32368683 DOI: 10.5114/amsad.2019.91432]
- 12 **Esposito RA,** Spencer FC. The effect of pericardial insulation on hypothermic phrenic nerve injury during open-heart surgery. *Ann Thorac Surg* 1987; **43**: 303-308 [PMID: 3827375 DOI: 10.1016/s0003-4975(10)60619-4]
- 13 **Wheeler WE,** Rubis LJ, Jones CW, Harrah JD. Etiology and prevention of topical cardiac hypothermia-induced phrenic nerve injury and left lower lobe atelectasis during cardiac surgery. *Chest* 1985; **88**: 680-683 [PMID: 4053709 DOI: 10.1378/chest.88.5.680]
- 14 **Maccherini M,** Davoli G, Sani G, Rossi P, Giani S, Lisi G, Mazzesi G, Toscano M. Warm heart surgery eliminates diaphragmatic paralysis. *J Card Surg* 1995; **10**: 257-261 [PMID: 7626876]
- 15 **Lerolle N,** Guérot E, Dimassi S, Zegdi R, Faisy C, Fagon JY, Diehl JL. Ultrasonographic diagnostic criterion for severe diaphragmatic dysfunction after cardiac surgery. *Chest* 2009; **135**: 401-407 [PMID: 18753469 DOI: 10.1378/chest.08-1531]
- 16 **Tripp HF,** Sees DW, Lisagor PG, Cohen DJ. Is phrenic nerve dysfunction after cardiac surgery related to internal mammary harvesting? *J Card Surg* 2001; **16**: 228-231 [PMID: 11824668 DOI: 10.1111/j.1540-8191.2001.tb00512.x]
- 17 **Zakkar M,** Guida G, Suleiman MS, Angelini GD. Cardiopulmonary bypass and oxidative stress. *Oxid Med Cell Longev* 2015; **2015**: 189863 [PMID: 25722792 DOI: 10.1155/2015/189863]
- 18 **Lakhani M,** Saiful F, Parikh V, Goyal N, Bekheit S, Kowalski M. Recordings of diaphragmatic electromyograms during cryoballoon ablation for atrial fibrillation accurately predict phrenic nerve injury. *Heart Rhythm* 2014; **11**: 369-374 [PMID: 24252287 DOI: 10.1016/j.hrthm.2013.11.015]
- 19 **Miyazaki S,** Ichihara N, Nakamura H, Taniguchi H, Hachiya H, Araki M, Takagi T, Iwasawa J, Kuroi A, Hirao K, Iesaka Y. Prospective Evaluation of Electromyography-Guided Phrenic Nerve Monitoring During Superior Vena Cava Isolation to Anticipate Phrenic Nerve Injury. *J Cardiovasc Electrophysiol* 2016; **27**: 390-395 [PMID: 27074774 DOI: 10.1111/jce.12912]
- 20 **Mol D,** Renskers L, Balt JC, Bhagwandien RE, Blaauw Y, van Driel VJHM, Driessen AHG, Elvan A, Folkeringa R, Hassink RJ, Hooft van Huysduynen B, Luermans JGLM, Stevenhagen JY, van der Voort PH, Westra SW, de Groot JR, de Jong JSSG; Netherlands Heart Registration Ablation Committee. Persistent phrenic nerve palsy after atrial fibrillation ablation: Follow-up data from The Netherlands Heart Registration. *J Cardiovasc Electrophysiol* 2022; **33**: 559-564 [PMID: 35040534 DOI: 10.1111/jce.15368]
- 21 **Almorad A,** Del Monte A, Della Rocca DG, Pannone L, Ramak R, Overeinder I, Bala G, Ströcker E, Seira J, Dubois A, Sorgente A, El Haddad M, Iacopino S, Boveda S, de Asmundis C, Chierchia GB. Outcomes of pulmonary vein isolation with radiofrequency balloon vs. cryoballoon ablation: a multi-centric study. *Europace* 2023; **25** [PMID: 37671682 DOI: 10.1093/europace/euad252]
- 22 **Urbanek L,** Bordignon S, Schaack D, Chen S, Tohoku S, Efe TH, Ebrahimi R, Panse F, Hirokami J, Plank K, Koch A, Schulte-Hahn B, Schmidt B, Chun KJ. Pulsed Field Versus Cryoballoon Pulmonary Vein Isolation for Atrial Fibrillation: Efficacy, Safety, and Long-Term Follow-Up in a 400-Patient Cohort. *Circ Arrhythm Electrophysiol* 2023; **16**: 389-398 [PMID: 37254781 DOI: 10.1161/CIRCEP.123.011920]
- 23 **Trovato GM.** Thoracic ultrasound: A complementary diagnostic tool in cardiology. *World J Cardiol* 2016; **8**: 566-574 [PMID: 27847557 DOI: 10.4330/wjcv.v8.i10.566]
- 24 **Targhetta R,** Chavagneux R, Ayoub J, Lemerre C, Préfaut C, Bourgeois JM, Balmes P. [Right diaphragmatic kinetics measured by TM-mode ultrasonography with concomitant spirometry in normal subjects and asthmatic patients. Preliminary results]. *Rev Med Interne* 1995; **16**: 819-826 [PMID: 8570938 DOI: 10.1016/0248-8663(96)80796-x]
- 25 **Kantarci F,** Mihmanli I, Demirel MK, Harmanci K, Akman C, Aydogan F, Mihmanli A, Uysal O. Normal diaphragmatic motion and the effects of body composition: determination with M-mode sonography. *J Ultrasound Med* 2004; **23**: 255-260 [PMID: 14992363 DOI: 10.7863/jum.2004.23.2.255]

- 26 **Epelman M**, Navarro OM, Daneman A, Miller SF. M-mode sonography of diaphragmatic motion: description of technique and experience in 278 pediatric patients. *Pediatr Radiol* 2005; **35**: 661-667 [PMID: 15776227 DOI: 10.1007/s00247-005-1433-7]
- 27 **Boon AJ**, Harper CJ, Ghahfarokhi LS, Strommen JA, Watson JC, Sorenson EJ. Two-dimensional ultrasound imaging of the diaphragm: quantitative values in normal subjects. *Muscle Nerve* 2013; **47**: 884-889 [PMID: 23625789 DOI: 10.1002/mus.23702]
- 28 **Summerhill EM**, Angov N, Garber C, McCool FD. Respiratory muscle strength in the physically active elderly. *Lung* 2007; **185**: 315-320 [PMID: 17917778 DOI: 10.1007/s00408-007-9027-9]
- 29 **Lloyd T**, Tang YM, Benson MD, King S. Diaphragmatic paralysis: the use of M mode ultrasound for diagnosis in adults. *Spinal Cord* 2006; **44**: 505-508 [PMID: 16331304 DOI: 10.1038/sj.sc.3101889]
- 30 **Boussuges A**, Brégeon F, Blanc P, Gil JM, Poirrette L. Characteristics of the paralysed diaphragm studied by M-mode ultrasonography. *Clin Physiol Funct Imaging* 2019; **39**: 143-149 [PMID: 30325572 DOI: 10.1111/cpf.12549]
- 31 **Gottesman E**, McCool FD. Ultrasound evaluation of the paralyzed diaphragm. *Am J Respir Crit Care Med* 1997; **155**: 1570-1574 [PMID: 9154859 DOI: 10.1164/ajrcrm.155.5.9154859]
- 32 **Boussuges A**, Finance J, Chaumet G, Brégeon F. Diaphragmatic motion recorded by M-mode ultrasonography: limits of normality. *ERJ Open Res* 2021; **7** [PMID: 33778044 DOI: 10.1183/23120541.00714-2020]
- 33 **Boussuges A**, Rives S, Finance J, Chaumet G, Vallée N, Risso JJ, Brégeon F. Ultrasound Assessment of Diaphragm Thickness and Thickening: Reference Values and Limits of Normality When in a Seated Position. *Front Med (Lausanne)* 2021; **8**: 742703 [PMID: 34778304 DOI: 10.3389/fmed.2021.742703]
- 34 **Boussuges A**, Habert P, Chaumet G, Rouibah R, Delorme L, Menard A, Million M, Bartoli A, Guedj E, Gouitaa M, Zieleskiewicz L, Finance J, Coiffard B, Delliaux S, Brégeon F. Diaphragm dysfunction after severe COVID-19: An ultrasound study. *Front Med (Lausanne)* 2022; **9**: 949281 [PMID: 36091672 DOI: 10.3389/fmed.2022.949281]
- 35 **Katagiri M**, Young RN, Platt RS, Kieser TM, Easton PA. Respiratory muscle compensation for unilateral or bilateral hemidiaphragm paralysis in awake canines. *J Appl Physiol* (1985) 1994; **77**: 1972-1982 [PMID: 7836225 DOI: 10.1152/jappl.1994.77.4.1972]
- 36 **Houston JG**, Fleet M, Cowan MD, McMillan NC. Comparison of ultrasound with fluoroscopy in the assessment of suspected hemidiaphragmatic movement abnormality. *Clin Radiol* 1995; **50**: 95-98 [PMID: 7867276 DOI: 10.1016/s0009-9260(05)82987-3]
- 37 **LoMauro A**, Aliverti A, Perchiazzi G, Frykholm P. Physiological changes and compensatory mechanisms by the action of respiratory muscles in a porcine model of phrenic nerve injury. *J Appl Physiol* (1985) 2021; **130**: 813-826 [PMID: 33444121 DOI: 10.1152/japplphysiol.00781.2020]
- 38 **Ben-Dov I**, Kaminski N, Reichert N, Rosenman J, Shulimzon T. Diaphragmatic paralysis: a clinical imitator of cardiorespiratory diseases. *Isr Med Assoc J* 2008; **10**: 579-583 [PMID: 18847154]
- 39 **Laghlam D**, Naudin C, Srour A, Monsonogo R, Malvy J, Rahoual G, Squara P, Nguyen LS, Estagnasié P. Persistent diaphragm dysfunction after cardiac surgery is associated with adverse respiratory outcomes: a prospective observational ultrasound study. *Can J Anaesth* 2023; **70**: 228-236 [PMID: 36513852 DOI: 10.1007/s12630-022-02360-8]
- 40 **Boussuges A**, Chaumet G, Poirrette L. Interest of ultrasonographic assessment of diaphragmatic function in cardiac rehabilitation center: a case report. *Medicine (Baltimore)* 2015; **94**: e801 [PMID: 25984664 DOI: 10.1097/MD.0000000000000801]
- 41 **Sarac S**, Salturk C, Oruc O, Metin SK, Bayram S, Karakurt Z, Yalcinkaya I. Sleep-related breathing disorders in diaphragmatic pathologies. *Sleep Breath* 2022; **26**: 959-963 [PMID: 34191224 DOI: 10.1007/s11325-021-02422-z]
- 42 **Javaheri S**, Barbe F, Campos-Rodriguez F, Dempsey JA, Khayat R, Javaheri S, Malhotra A, Martinez-Garcia MA, Mehra R, Pack AI, Polotsky VY, Redline S, Somers VK. Sleep Apnea: Types, Mechanisms, and Clinical Cardiovascular Consequences. *J Am Coll Cardiol* 2017; **69**: 841-858 [PMID: 28209226 DOI: 10.1016/j.jacc.2016.11.069]
- 43 **Darchis JS**, Ennezat PV, Charbonnel C, Aubert JM, Gonin X, Auffray JL, Bauchart JJ, Le Tourneau T, Rey C, Godart F, Goldstein P, Asseman P. Hemidiaphragmatic paralysis: an underestimated etiology of right-to-left shunt through patent foramen ovale? *Eur J Echocardiogr* 2007; **8**: 259-264 [PMID: 16824802 DOI: 10.1016/j.euje.2006.05.003]
- 44 **Wiertsema MH**, Dickinson MG, Hoendermis ES, Geluk CA. Platypnea orthodeoxia syndrome after recent stroke: a case report of a sandwiched right atrium. *Eur Heart J Case Rep* 2022; **6**: ytac275 [PMID: 35854888 DOI: 10.1093/ehjcr/ytac275]
- 45 **Fabris T**, Buja P, Cucchini U, D'Amico G, Cazzuffi R, Balestro E, Tarantini G. Right-to-left interatrial shunt secondary to right hemidiaphragmatic paralysis: an unusual scenario for urgent percutaneous closure of patent foramen ovale. *Heart Lung Circ* 2015; **24**: e56-e59 [PMID: 25499594 DOI: 10.1016/j.hlc.2014.11.003]
- 46 **Kodric M**, Trevisan R, Torregiani C, Cifaldi R, Longo C, Cantarutti F, Confalonieri M. Inspiratory muscle training for diaphragm dysfunction after cardiac surgery. *J Thorac Cardiovasc Surg* 2013; **145**: 819-823 [PMID: 22938776 DOI: 10.1016/j.jtcvs.2012.07.087]
- 47 **Schaeffer MR**, Louvaris Z, Rodrigues A, Poddighe D, Gayan-Ramirez G, Gojovic T, Geerts L, Heyndrickx E, Van Hollebeke M, Janssens L, Gosselink R, Testelmans D, Langer D. Effects of inspiratory muscle training on exertional breathlessness in patients with unilateral diaphragm dysfunction: a randomised trial. *ERJ Open Res* 2023; **9** [PMID: 37868146 DOI: 10.1183/23120541.00300-2023]
- 48 **Gayan-Ramirez G**, Gosselin N, Troosters T, Bruyninckx F, Gosselink R, Decramer M. Functional recovery of diaphragm paralysis: a long-term follow-up study. *Respir Med* 2008; **102**: 690-698 [PMID: 18276128 DOI: 10.1016/j.rmed.2008.01.001]
- 49 **Smith BM**, Ezeokoli NJ, Kipps AK, Azakie A, Meadows JJ. Course, predictors of diaphragm recovery after phrenic nerve injury during pediatric cardiac surgery. *Ann Thorac Surg* 2013; **96**: 938-942 [PMID: 23932321 DOI: 10.1016/j.athoracsur.2013.05.057]
- 50 **Carlson CS**, Brown SR, Wilson MW, Choi PJ. Noninvasive ventilation: An important option in the management of hemidiaphragm paralysis. *J Card Surg* 2021; **36**: 3921-3923 [PMID: 34260766 DOI: 10.1111/jocs.15824]
- 51 **Beshay M**, Abdel Bary M, Kösek V, Vordemvenne T, Mertzluff F, Schulte Am Esch J. Minimally-Invasive Diaphragmatic Plication in Patients with Unilateral Diaphragmatic Paralysis. *J Clin Med* 2023; **12** [PMID: 37629343 DOI: 10.3390/jcm12165301]
- 52 **Freeman RK**, Van Woerkom J, Vyverberg A, Ascoti AJ. Long-term follow-up of the functional and physiologic results of diaphragm plication in adults with unilateral diaphragm paralysis. *Ann Thorac Surg* 2009; **88**: 1112-1117 [PMID: 19766791 DOI: 10.1016/j.athoracsur.2009.05.027]
- 53 **Hunt AR**, Stuart CM, Gergen AK, Bang TJ, Reihman AE, Helmkamp LJ, Lin Y, Mitchell JD, Meguid RA, Scott CD, Wojcik BM. Long-Term Patient-Reported Symptom Improvement and Quality of Life after Transthoracic Diaphragm Plication in Adults. *J Am Coll Surg* 2023; **237**: 533-544 [PMID: 37194947 DOI: 10.1097/XCS.0000000000000762]



Published by **Baishideng Publishing Group Inc**
7041 Koll Center Parkway, Suite 160, Pleasanton, CA 94566, USA

Telephone: +1-925-3991568

E-mail: office@baishideng.com

Help Desk: <https://www.f6publishing.com/helpdesk>

<https://www.wjgnet.com>

