



Hirschsprung's disease associated enterocolitis: A comprehensive review

Eric M Gershon, Leonel Rodriguez, Ricardo A Arbizu

Specialty type: Pediatrics

Provenance and peer review:

Invited article; Externally peer reviewed.

Peer-review model: Single blind

Peer-review report's scientific quality classification

Grade A (Excellent): A

Grade B (Very good): B

Grade C (Good): 0

Grade D (Fair): 0

Grade E (Poor): 0

P-Reviewer: Lourencao P, Brazil; Sergi CM, Canada

Received: December 29, 2022

Peer-review started: December 29, 2022

First decision: January 31, 2023

Revised: February 9, 2023

Accepted: March 21, 2023

Article in press: March 21, 2023

Published online: June 9, 2023



Eric M Gershon, Leonel Rodriguez, Ricardo A Arbizu, Section of Pediatric Gastroenterology, Yale University School of Medicine, New Haven, CT 06520, United States

Corresponding author: Ricardo A Arbizu, MD, MS, Assistant Professor, Section of Pediatric Gastroenterology, Yale University School of Medicine, 333 Cedar St, New Haven, CT 06520, United States. ricardo.arbizu@yale.edu

Abstract

Hirschsprung's disease (HSCR) is a congenital disorder characterized by failure of the neural crest cells to migrate and populate the distal bowel during gestation affecting different lengths of intestine leading to a distal functional obstruction. Surgical treatment is needed to correct HSCR once the diagnosis is confirmed by demonstrating the absence of ganglion cells or aganglionosis of the affected bowel segment. Hirschsprung's disease associated enterocolitis (HAEC) is an inflammatory complication associated with HSCR that can present either in the pre- or postoperative period and associated with increased morbidity and mortality. The pathogenesis of HAEC remains poorly understood, but intestinal dysmotility, dysbiosis and impaired mucosal defense and intestinal barrier function appear to play a significant role. There is no clear definition for HAEC, but the diagnosis is primarily clinical, and treatment is guided based on severity. Here, we aim to provide a comprehensive review of the clinical presentation, etiology, pathophysiology, and current therapeutic options for HAEC.

Key Words: Hirschsprung's; Enterocolitis; Pathogenesis; Microbiome; Dysbiosis; Dysmotility; Treatment

©The Author(s) 2023. Published by Baishideng Publishing Group Inc. All rights reserved.

Core Tip: Hirschsprung's disease associated enterocolitis (HAEC) is an inflammatory complication of Hirschsprung's disease (HSCR) with variable degrees of severity. It is important for pediatric providers to be aware of the signs and symptoms of HAEC as it can affect patients before or after corrective surgery. The pathogenesis of HAEC is multifactorial and previous and ongoing studies continue to improve our knowledge of this potentially fatal complication of HSCR and will ultimately allow clinicians to provide personalized care for these patients. In the meantime, current preventive measures and treatment guidelines have helped decrease the morbidity and mortality associated with HAEC.

Citation: Gershon EM, Rodriguez L, Arbizu RA. Hirschsprung's disease associated enterocolitis: A comprehensive review. *World J Clin Pediatr* 2023; 12(3): 68-76

URL: <https://www.wjgnet.com/2219-2808/full/v12/i3/68.htm>

DOI: <https://dx.doi.org/10.5409/wjcp.v12.i3.68>

INTRODUCTION

Hirschsprung's Disease (HSCR) is an intestinal motor disorder caused by failure of neural crest cells (precursors of intestinal ganglion cells) to migrate completely during intestinal development. The aganglionic segment of bowel with impaired relaxation leads to a functional obstruction and symptoms [1]. In healthy children, craniocaudal migration of neural crest cells commence at 4 wk gestation and finishes at 7 wk, but the true etiology of this failure of migration in HSCR is unknown. However, theories include premature differentiation of neural crest cells leading to lack of further migration and local ganglion cell destruction [1].

The incidence of HSCR ranges from 1 in 3500 to 5000 live births [2] and has a male predominance with a male to female ratio of 4:1 [3]. The extent of aganglionosis varies from short-segment disease comprising the recto-sigmoid (75%-80% of cases), to total colonic aganglionosis (5%-7% of cases). Ten to 15% of cases, referred to as long-segment disease, display aganglionosis proximal to the sigmoid colon [4]. Common presentations of HSCR vary depending on several factors, mainly the length of the affected colonic segment. These include symptoms and signs of neonatal distal intestinal obstruction: Abdominal distension, bilious vomiting, failure to pass meconium and explosive stools [4]. Screening modalities for HSCR include contrast enema (demonstrating a dilated colon, transition zone, or abnormal recto-sigmoid ratio), and anorectal manometry (to assess for the presence of a recto-anal inhibitory reflex) and when abnormal, a suction or full thickness rectal biopsy confirms the diagnosis by demonstrating absence of ganglion cells (aganglionosis) [4]. Treatment for HSCR is primarily limited to surgical resection of affected segment, or pull-through procedure, where innervated bowel is reconnected to the anus while attempting to preserve anal sphincter function [4]. Although most patients have normal quality of life and bowel function after surgery, some will have ongoing obstructive symptoms [5] like abdominal distension, chronic constipation, and intestinal inflammation or Hirschsprung's disease associated enterocolitis (HAEC) which is considered one of the most fatal complications in patients with HSCR. In this review, we will discuss the clinical presentation, etiology, pathophysiology, and current therapeutic options for HAEC (Figure 1) and discuss the future directions for the evaluation and management of this condition that is still encountered in patients with HSCR.

HIRSCHSPRUNG'S DISEASE ASSOCIATED ENTEROCOLITIS

HAEC is a severe and potentially lethal complication of HSCR. HAEC can have a variable clinical presentation but is classically manifested as fever, lethargy, abdominal distention, foul-smelling and explosive diarrhea [6]. This condition can occur both pre- and postoperatively with varying reported incidence. Preoperative incidence is estimated between 6%-60% while the postoperative incidence is estimated between 25-42% [6]. Mortality associated with HAEC ranges between 5%-50%, with higher prevalence in the neonatal period prior to definitive surgical correction [7]. Nevertheless, mortality rates have continued to decline to less than 1% due to advances in surgical technique and medical care [3]. HAEC has also been reported as the presenting symptom of HSCR in up to 25% of infants [8]. HAEC can also present with bowel perforation in the neonatal period documented as occurring in 3%-6% of HSCR patients [9-11]. In a retrospective analysis of complications in patients awaiting definitive surgical correction for HSCR, bowel perforation was noted as the most common complication (7% of total patients analyzed) [12]. Theories for perforation as a presentation in HSCR include increased luminal pressure, transmural inflammation and vascular accidents leading to ischemia and subsequently perforation. Zhu *et al* [13] performed a retrospective review looking at risk factors for perforated HSCR in neonates. They noted that most perforations occurred at the proximal ganglionic bowel (71%) as opposed to the transition zone or aganglionic bowel and that perforation was more common with

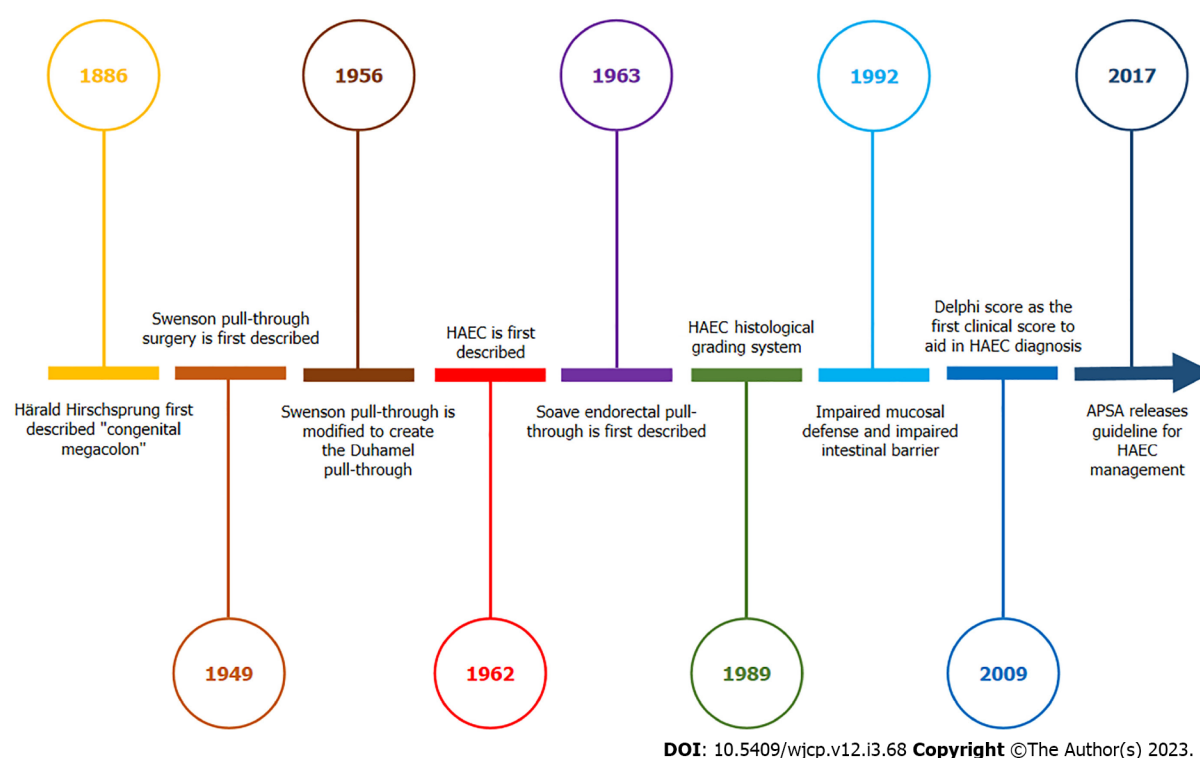


Figure 1 Timeline graphic illustrating pivotal definitions, surgical treatment, and management guideline for Hirschsprung's disease associated enterocolitis. HAEC: Hirschsprung's disease associated enterocolitis.

higher grade inflammation of the bowel wall. They demonstrated that laboratory studies and bowel histopathologic changes in patients with perforated HSCR were similar to those found in HAEC, thus illustrating a potential association between the two.

The variety of presenting symptomatology of HAEC leads to difficulty in making the diagnosis and there is no standardized definition of HAEC. However, several groups have tried to establish a scoring system to standardize the diagnosis. Notably in 2009, an expert panel used the Delphi method to achieve a consensus of 18 items present in patient history, physical exam, laboratory and imaging findings to aid in the diagnosis of HAEC[14]. A score of 10 or more indicated a diagnosis of HAEC, with equal weight given to all factors other than diarrhea with explosive stool, diarrhea with foul-smelling stool, explosive discharge of stool on rectal exam, and distended abdomen which were weighted more heavily in support of the diagnosis. These criteria, while expansive, had limited validation and have been used more in research studies rather than in clinical practice[15]. In 2018, Frykman *et al*[16] performed a multicenter retrospective review to optimize the sensitivity and specificity of the Delphi score. In this study, they found that lowering the score threshold for diagnosis from 10 to 4 optimized sensitivity and specificity (83.7% and 98.6%, respectively). Most recently, Lewit *et al*[15] performed a multicenter data collection and used multivariate analysis to create a new scoring system limited to fever, bloody diarrhea, leukocytosis, obstipation, distention, and dilated loops of bowel in x-ray. This score seemed to outperform both the Delphi and Frykman scores due to its higher sensitivity. Finally, while not including a scoring system, the American Pediatric Surgery Association (APSA) released its guidelines in 2017 to aid in the diagnosis of this variably presenting complication of HSCR. This system places patient presentations into three categories (possible, definite, and severe) based off patient history, physical exam, and imaging studies. The goal of this system was to create an easily used yet clinically relevant grade to help provide consistency in therapy[17].

Histopathology

In 1989, Teitelbaum *et al*[18] described a grading system based on the histological intestinal mucosal changes found in HAEC. They included factors such as intestinal crypt dilation, cryptitis, mucin retention, crypt abscess, mucosal ulceration, and necrosis and proposed a classification system of 5 grades with increasing severity of disease, with grade 0 being normal mucosa and grade 5 being the most severe. They reported a significant correlation between clinically apparent HAEC and histopathologic scores of grade 3 and above. This grading system has persisted and is still used for both clinical and research purposes.

Predisposing risk factors for HAEC

There are several known risk factors for developing HAEC and can be subdivided into preoperative and postoperative. Commonly reported preoperative risk factors include a family history of HSCR, long-segment disease, trisomy 21, presence of associated congenital anomalies, and delay in diagnosis of HSCR[19]. Engum *et al*[20] reported a series of 20 infants and children with history of HSCR and found that the incidence of HAEC was more than double in patients with family history of HSCR (35% *vs* 16%). The reason for this increased risk is thought to be secondary to heritable factors. Trisomy 21 is one of the best-established clinical risk factors conveying a risk as high as 54% of HAEC[19,21] and hypothesized to be due to an intrinsically decreased humoral and cytotoxic T-cell function present in infants with this syndrome[22]. Long-segment disease has also shown to confer larger risk of HAEC, thought to be secondary to increased stasis of luminal contents[19]. Several reports have demonstrated an increased rate of HAEC, as high as 56%, in patients with long-segment disease[23,24]. Finally, delay in diagnosis in the newborn period also seems to be a significant risk factor for HAEC. Lee *et al*[25] performed a retrospective review of 51 newborns diagnosed with HSCR and found a preoperative incidence of 63% of HAEC in patients diagnosed after 7 days of life compared to 12% in those diagnosed before 7 days. They also noted a significant increase in morbidity after HAEC in the late diagnosis group including increased risk of developing postoperative adhesive bowel obstruction and failure to thrive.

Postoperative risk factors for HAEC can be subdivided into histopathologic and mechanical. Histologically, the presence of a segment of aganglionic bowel after definitive surgery is a risk factor for HAEC. This can be seen if there is residual disease after surgery, if an area of bowel becomes aganglionic due to degenerative changes in the bowel after surgery, if a skip area was present where an unknown proximal portion of bowel was also aganglionic, or if the transition zone between normal and aganglionic bowel is not entirely resected[26]. Mechanical predisposing risk factors include bowel torsion proximal to the anastomosis site and formation of an anastomotic stricture or cuff stenosis on the pulled-through segment of normal bowel. Overall, the common premise uniting these risk factors for postoperative HAEC are mechanisms that affect the motility or produce a functional obstruction of the pulled-through bowel. Other clinical risk factors that have been investigated during the postoperative period include a history of preoperative episodes of HAEC and definitive surgery before age of 6 mo[27,28]. Additionally, socioeconomic risk factors for the development of HAEC have been identified. In a study of 100 children awaiting surgical correction for HSCR, the authors found that patients that used public transportation for clinic visits, had one or more missed appointments, had any reported safety concerns, had parents or guardians who were not married, lived with people other than their immediate family, or had mothers who reported drug use or lack of prenatal care were found to have a higher likelihood of developing HAEC[29].

Pathophysiology

The exact mechanism underlying HAEC remains unknown. However, there has been significant progress in our understanding of the pathogenesis of this disorder and studies underscore the potential role of the following pathways:

Intestinal dysmotility: Impaired intestinal motility affecting the aganglionic segment was one of the earliest described mechanisms causing HAEC. However, ongoing dilation of the proximal ganglionated bowel leading to fecal stasis, bacterial translocation and ischemia was later proposed as a cause for HAEC. Nevertheless, HAEC still develops after surgical correction or in the presence of a diverting ostomy in some patients suggestive of an intrinsic defect at the level of the enteric nervous system leading to dysmotility. Several HSCR mouse model studies have demonstrated a decrease in neuronal cell density at the level of the proximal ganglionated bowel[30] and alteration in the balance of local cholinergic and nitrergic neurons[31], with overrepresentation of the latter which are involved in intestinal relaxation. These findings were later corroborated in a human study and most importantly, demonstrated a possible correlation with clinical outcomes[32]. In contrary, a retrospective study in humans concluded that in HSCR patients with a low mucosal nerve fiber innervation grade in the distal aganglionic bowel have a higher risk of developing HAEC[33]. Similarly, a prospective study also demonstrated that lack of cholinergic innervation in the distal colon of HSCR patients was associated with increased risk of postoperative HAEC[34].

Impaired mucosal defense and intestinal barrier function: One of the initial studies implicating impaired mucosal defense in HSCR evaluated the role of secretory immunoglobulin A (sIgA). The authors found that the transfer of sIgA across the gastrointestinal wall is impaired in patients with HSCR (despite increased sIgA levels in the lamina propria plasma cells) and decreased in those with HAEC[35]. Other studies have suggested that the production and transport of intestinal mucins may be abnormal in HSCR and may have a potential role in the pathogenesis of HAEC[36,37]. Of these, MUC-2 is the predominant mucin expressed in humans and *in vitro* studies have demonstrated that it can prevent bacterial translocation across the intestinal wall[38]. A study that analyzed stool samples in humans found that the protein expression of MUC-2 was significantly decreased in patients with HSCR when compared to controls and absent in those with clinical features of HAEC[39]. Interestingly, studies

in a HSCR mouse model demonstrated an increase in goblet cell proliferation and differentiation in areas of aganglionosis, and subsequent altered surface mucus properties prior to the development of inflammation in the distal colon epithelium in HAEC[40]. Other studies of the caudal type homeobox gene-1 and -2 (CDX-1 and CDX-2) that control proliferation and differentiation of intestinal mucosal cells[41], intracellular adhesion molecule-1 (ICAM-1) a cell surface adhesion glycoprotein involved in leukocyte recruitment[42], and caveolin-1 involved in inflammation and intestinal epithelial barrier function[43], have shown altered gene expression in the colonic mucosal epithelium of patients with HAEC.

Dysbiosis: Emerging techniques, like next generation sequencing, have provided novel insight of the human intestinal microbiota, both in health and disease. Animal and human studies have demonstrated that the microbiota composition and diversity are different between controls, HSCR and HAEC. However, most are limited to a small number of samples or differences in technique that demonstrate variation in results. Nevertheless, it seems evident that dysbiosis is part of the pathogenesis in HAEC. A study by Frykman *et al*[44] evaluated the intestinal microbiota in fecal samples of HSCR patients with and without HAEC. By using DNA sequencing they demonstrated that not only the bacterial, but also the fungal composition was different in children with HAEC compared to those without HAEC. The authors found modest reductions in Firmicutes and Verrucomicrobia and increases in Bacteroidetes and Proteobacteria. Varieties of fungi were also observed. Specifically, *Candida* was increased and *Malassezia* and *Saccharomyces* were reduced[44]. Li *et al*[45] collected fecal samples from the proximal and distal colon during routine or emergency surgery in patients with HSCR, prior history of HAEC, and active HAEC and found a predominance of Bacteroidetes in the first group and of Proteobacteria the latter groups. Interestingly, these changes persisted in patients with HAEC and the microbiota composition was different between the proximal and distal colon sites in HSCR patients, but not in those with a prior history or active HAEC. More recently, Parker *et al*[46] demonstrated longitudinal changes in the intestinal microbiota from fecal samples of HSCR patients with active enterocolitis and demonstrated composition similarity in patients that achieved remission (also enrichment with *Blautia*), while patients with recurrent HAEC demonstrated ongoing substantial variability in their microbiota composition. We have demonstrated that the microbiota composition and diversity is different between patients with and without a history of postoperative HAEC by 16S rDNA sequencing of colon tissue samples. Specifically, we reported an increased relative abundance of the phyla Bacteroidetes, Firmicutes and Cyanobacteria in HAEC patients and Fusobacteria, Actinobacteria and Proteobacteria in HSCR patients and an increased relative abundance of the genera *Dolosigranulum*, *Roseouria* and *Streptococcus* in HAEC patients and *Propionibacterium* and *Delftia* in HSCR patients[47]. These findings highlight that changes in the intestinal microbiota composition and diversity can be seen both in the intestinal lumen and the bowel wall in HSCR patients with and without HAEC.

Treatment

There are several treatment modalities utilized in the care of patients with HAEC. The HAEC severity grading system described by the APSA provides recommendations for management based on grade of severity (Table 1)[17]. Grade 1, or possible HAEC, can be managed in the outpatient setting with oral antibiotics (metronidazole), oral hydration and potential use of rectal irrigations. Rectal irrigations are meant to wash out retained stool to help relieve any obstruction that is present. They are typically given 2-4 times per day using large bore rubber catheters until the effluent is clear[19]. Grade 2 (definite HAEC) requires inpatient management where the patient is usually kept Nil Per Os (NPO) and treated with intravenous (IV) antibiotics (metronidazole) with consideration of broad-spectrum antibiotic coverage, and rectal irrigations. Patients should have stool tests to rule out potential infections that could be involved and cause a similar presenting symptomatology (*Clostridioides difficile*, *Salmonella*, *Shigella*, *Rotavirus*)[19]. Grade 3 management is largely similar to grade 2. However, these patients are quite ill, often requiring intensive care unit level care, nasogastric decompression, and may need surgical management such as proximal bowel diversion. Several studies have shown that use of this standardized algorithm or other similar tools to guide management decreases length of stay, use of IV antibiotics, and readmission[48,49].

Another treatment option for HAEC is the use of Botulinum toxin injection (BTI) to the internal anal sphincter (IAS). In patients with HSCR, due to the absence of the recto-anal inhibitory reflex, the IAS does not relax upon rectal distension with stool or gas leading to continued distal bowel obstruction after surgical correction and potentially increasing the risk of HAEC. Botulinum toxin prevents the presynaptic release of acetylcholine producing a state of temporary local denervation with subsequent decrease of the resting anal pressure, potentially relieving the distal functional obstruction. In 2021, Svetanoff *et al*[50] performed a retrospective study looking at BTI in the setting of HAEC and found a statistically significant increase in the time between readmission in patients with recurrent HAEC. BTI has also been shown to decrease the duration of IV antibiotics and length of stay in patients with HAEC [51]. However, most studies assessing the utility of BTI in HAEC are retrospective and underpowered. Roorda *et al*[52] performed a meta-analysis of the evidence for BTI in HSCR and specifically looked at effectiveness in HAEC. They included 3 studies involving 52 patients which showed reduction of

Table 1 Hirschsprung's disease associated enterocolitis severity score and management[17]

APSA category	Symptom	Radiography	Treatment	Additional measures
Grade 1 (Possible HAEC)	Anorexia, diarrhea, mild abdominal distension	Normal, or mild signs of ileus	Oral hydration; Oral metronidazole	Rectal irrigations
Grade 2 (Definite HAEC)	One or more of the following: Explosive diarrhea; Fever, tachycardia, or lethargy; Moderate abdominal distension and/or tenderness; Explosive gas/stool on rectal examination;	May include: Signs of ileus (air fluid levels, dilated bowel loops); Distension of the proximal colon w/rectosigmoid cutoff	Clear liquids or NPO; IV hydration; Metronidazole (PO or IV); Broad spectrum antibiotic coverage; Rectal irrigations	NGT decompression
Grade 3 (Severe HAEC)	Grade II symptoms plus: Obstipation; Poor perfusion; Hypotension; Altered mental status; Marked abdominal distension; Signs of peritonitis	Signs of Grade II PLUS possible: Pneumatosis intestinalis; Pneumoperitoneum (rare)	NPO; Metronidazole (IV) + broad spectrum antibiotics (IV ampicillin + gentamicin, IV piperacillin/tazobactam); Rectal irrigations	NGT decompression; Possible surgical intervention

APSA: American Pediatric Surgery Association; HAEC: Hirschsprung's disease associated enterocolitis; IV: Intravenous; NGT: Nasogastric tube; NPO: Nothing by mouth; PO: Per oral.

enterocolitis in an average of 58% of patients, however the effect was not statistically significant. Further studies are needed to truly evaluate the use of BTI for active HAEC. Additionally, others have evaluated the use of BTI as a preventative measure for postoperative obstructive symptoms and HAEC. After other causes of obstruction are ruled out, BTI into the internal and external sphincter can serve as a therapeutic intervention and may reduce the incidence of obstructive symptoms and HAEC[51]. Other studies have suggested there may be a decrease in hospitalizations for patients with recurrent HAEC. Chumpitazi *et al*[53] performed a retrospective review looking at BTI use in patients with surgically repaired HSCR and IAS achalasia. They demonstrated a potential decrease in hospitalizations per year in their HAEC subgroup; however, the long-term response to the injections varied and children with IAS achalasia seemed to respond better than HAEC patients. They also noted that initial short-term improvement in symptoms after first BTI was useful in predicting favorable long-term outcomes.

Other postoperative preventive measures include the daily use of rectal irrigations, anal dilations, and rectal tube placement. A systematic review and meta-analysis demonstrated that the use of rectal irrigations after pull-through surgery significantly reduced the incidence of postoperative HAEC[54]. However, this same study concluded that the potential role of routine anal dilations in preventing postoperative HAEC remains unclear. A randomized trial demonstrated that the temporary use of a rectal catheter for 5 days after surgery reduced the postoperative incidence of HAEC in the first 30 days [55].

In terms of operative management for HAEC, there does appear to be a role for intestinal diverting ostomy in severe cases. Several features which may warrant consideration of diversion include delayed presentation for HSCR, presence of multiple risk factors for HAEC, or multiple concomitant comorbid conditions including sepsis, trisomy 21, and Bardet- Biedl Syndrome[19]. Prior to corrective pull-through, diversion can be considered in the decompensating neonate with long-segment disease given that they have higher failure rates of rectal washouts[56]. In these rare cases, a leveling colostomy is performed with intraoperative frozen section histology which is essential to ensure the colostomy is created just proximal to the transition zone[57]. While diversion may not entirely resolve HAEC, it does improve the patient's clinical status and quality of life.

CONCLUSION

There are several aspects of HAEC care that still require further study. Notably, improvement in both diagnostic strategies and standardization of care is needed across institutions. Promising areas of research include intestinal microbiota analysis which may help to personalize therapy, stem cell administration to restore the motor function to the remaining portions of bowel, and therapies aimed at altering colonic mucus barrier properties could be explored towards preventing the onset of enterocolitis in HSCR. This along with advances in our understanding of the pathophysiology itself will allow us to better care for HSCR patients suffering from recurrent HAEC.

FOOTNOTES

Author contributions: Gerson EM, Rodriguez L and Arbizu RA contributed equally with initial manuscript draft and final approval; Arbizu RA performed concept design, revisions, and final approval.

Conflict-of-interest statement: The authors have nothing to disclose and have no potential conflict of interest.

Open-Access: This article is an open-access article that was selected by an in-house editor and fully peer-reviewed by external reviewers. It is distributed in accordance with the Creative Commons Attribution NonCommercial (CC BY-NC 4.0) license, which permits others to distribute, remix, adapt, build upon this work non-commercially, and license their derivative works on different terms, provided the original work is properly cited and the use is non-commercial. See: <https://creativecommons.org/licenses/by-nc/4.0/>

Country/Territory of origin: United States

ORCID number: Eric M Gershon 0000-0002-4268-6456; Leonel Rodriguez 0000-0002-7128-6048; Ricardo A Arbizu 0000-0003-1118-5066.

S-Editor: Ma YJ

L-Editor: A

P-Editor: Ma YJ

REFERENCES

- 1 Langer JC. Hirschsprung disease. *Curr Opin Pediatr* 2013; **25**: 368-374 [PMID: 23615177 DOI: 10.1097/MOP.0b013e328360c2a0]
- 2 Karim A, Tang CS, Tam PK. The Emerging Genetic Landscape of Hirschsprung Disease and Its Potential Clinical Applications. *Front Pediatr* 2021; **9**: 638093 [PMID: 34422713 DOI: 10.3389/fped.2021.638093]
- 3 Suita S, Taguchi T, Ieiri S, Nakatsuji T. Hirschsprung's disease in Japan: analysis of 3852 patients based on a nationwide survey in 30 years. *J Pediatr Surg* 2005; **40**: 197-201; discussion 201 [PMID: 15868585 DOI: 10.1016/j.jpedsurg.2004.09.052]
- 4 Das K, Mohanty S. Hirschsprung Disease - Current Diagnosis and Management. *Indian J Pediatr* 2017; **84**: 618-623 [PMID: 28600660 DOI: 10.1007/s12098-017-2371-8]
- 5 Oltean I, Hayawi L, Larocca V, Bijelić V, Beveridge E, Kaur M, Grandpierre V, Kanyinda J, Nasr A. Quality of life outcomes in children after surgery for Hirschsprung disease and anorectal malformations: a systematic review and meta-analysis. *World J Pediatr Surg* 2022; **5**: e000447 [PMID: 36474732 DOI: 10.1136/wjps-2022-000447]
- 6 Puri P, SpringerLink (Online service). Hirschsprung's Disease and Allied Disorders. Available from: <https://yale.idm.oclc.org/Login?URL=https://doi.org/10.1007/978-3-030-15647-3>
- 7 Pini Prato A, Rossi V, Avanzini S, Mattioli G, Disma N, Jasonni V. Hirschsprung's disease: what about mortality? *Pediatr Surg Int* 2011; **27**: 473-478 [PMID: 21253751 DOI: 10.1007/s00383-010-2848-2]
- 8 Gosain A. Established and emerging concepts in Hirschsprung's-associated enterocolitis. *Pediatr Surg Int* 2016; **32**: 313-320 [PMID: 26783087 DOI: 10.1007/s00383-016-3862-9]
- 9 Swenson O, Sherman JO, Fisher JH. Diagnosis of congenital megacolon: an analysis of 501 patients. *J Pediatr Surg* 1973; **8**: 587-594 [PMID: 4752993 DOI: 10.1016/0022-3468(73)90395-3]
- 10 Newman B, Nussbaum A, Kirkpatrick JA Jr. Bowel perforation in Hirschsprung's disease. *AJR Am J Roentgenol* 1987; **148**: 1195-1197 [PMID: 3495146 DOI: 10.2214/ajr.148.6.1195]
- 11 Singh S, Rawat J, Wakhlu A, Kureel SN, Pandey A. Six-year retrospective analysis of colonic perforation in neonates and infants: single centre experience. *Afr J Paediatr Surg* 2012; **9**: 102-105 [PMID: 22878755 DOI: 10.4103/0189-6725.99391]
- 12 Beltman L, Labib H, Oosterlaan J, van Heurn E, Derikx J. Risk factors for complications in patients with Hirschsprung disease while awaiting surgery: Beware of bowel perforation. *J Pediatr Surg* 2022; **57**: 561-568 [PMID: 35354528 DOI: 10.1016/j.jpedsurg.2022.02.022]
- 13 Zhu T, Zhang G, Meng X, Yang J, Niu Y, He Y, Yang H, Xiong X, Feng J. Enterocolitis Is a Risk Factor for Bowel Perforation in Neonates With Hirschsprung's Disease: A Retrospective Multicenter Study. *Front Pediatr* 2022; **10**: 807607 [PMID: 35198516 DOI: 10.3389/fped.2022.807607]
- 14 Pastor AC, Osman F, Teitelbaum DH, Caty MG, Langer JC. Development of a standardized definition for Hirschsprung's-associated enterocolitis: a Delphi analysis. *J Pediatr Surg* 2009; **44**: 251-256 [PMID: 19159752 DOI: 10.1016/j.jpedsurg.2008.10.052]
- 15 Lewit RA, Veras LV, Cowles RA, Fowler K, King S, Lapidus-Krol E, Langer JC, Park CJ, Youssef F, Vavilov S, Gosain A. Reducing Underdiagnosis of Hirschsprung-Associated Enterocolitis: A Novel Scoring System. *J Surg Res* 2021; **261**: 253-260 [PMID: 33460971 DOI: 10.1016/j.jss.2020.12.030]
- 16 Frykman PK, Kim S, Wester T, Nordenskjöld A, Kawaguchi A, Hui TT, Teitelbaum DH, Granström AL, Rogatko A; HAEC Collaborative Research Group (HCRG). Critical evaluation of the Hirschsprung-associated enterocolitis (HAEC) score: A multicenter study of 116 children with Hirschsprung disease. *J Pediatr Surg* 2018; **53**: 708-717 [PMID: 28760457 DOI: 10.1016/j.jpedsurg.2017.07.009]
- 17 Gosain A, Frykman PK, Cowles RA, Horton J, Levitt M, Rothstein DH, Langer JC, Goldstein AM; American Pediatric Surgical Association Hirschsprung Disease Interest Group. Guidelines for the diagnosis and management of Hirschsprung-

- associated enterocolitis. *Pediatr Surg Int* 2017; **33**: 517-521 [PMID: 28154902 DOI: 10.1007/s00383-017-4065-8]
- 18 **Teitelbaum DH**, Caniano DA, Qualman SJ. The pathophysiology of Hirschsprung's-associated enterocolitis: importance of histologic correlates. *J Pediatr Surg* 1989; **24**: 1271-1277 [PMID: 2593059 DOI: 10.1016/s0022-3468(89)80566-4]
 - 19 **Frykman PK**, Short SS. Hirschsprung-associated enterocolitis: prevention and therapy. *Semin Pediatr Surg* 2012; **21**: 328-335 [PMID: 22985838 DOI: 10.1053/j.sempedsurg.2012.07.007]
 - 20 **Engum SA**, Petrites M, Rescorla FJ, Grosfeld JL, Morrison AM, Engles D. Familial Hirschsprung's disease: 20 cases in 12 kindreds. *J Pediatr Surg* 1993; **28**: 1286-1290 [PMID: 8263688 DOI: 10.1016/s0022-3468(05)80314-8]
 - 21 **Morabito A**, Lall A, Gull S, Mohee A, Bianchi A. The impact of Down's syndrome on the immediate and long-term outcomes of children with Hirschsprung's disease. *Pediatr Surg Int* 2006; **22**: 179-181 [PMID: 16362310 DOI: 10.1007/s00383-005-1617-0]
 - 22 **Nair MP**, Schwartz SA. Association of decreased T-cell-mediated natural cytotoxicity and interferon production in Down's syndrome. *Clin Immunol Immunopathol* 1984; **33**: 412-424 [PMID: 6209046 DOI: 10.1016/0090-1229(84)90312-x]
 - 23 **Elhalaby EA**, Coran AG, Blane CE, Hirschl RB, Teitelbaum DH. Enterocolitis associated with Hirschsprung's disease: a clinical-radiological characterization based on 168 patients. *J Pediatr Surg* 1995; **30**: 76-83 [PMID: 7722836 DOI: 10.1016/0022-3468(95)90615-0]
 - 24 **Reding R**, de Ville de Goyet J, Gosseye S, Clapuyt P, Sokal E, Buts JP, Gibbs P, Otte JB. Hirschsprung's disease: a 20-year experience. *J Pediatr Surg* 1997; **32**: 1221-1225 [PMID: 9269974 DOI: 10.1016/s0022-3468(97)90686-2]
 - 25 **Lee CC**, Lien R, Chiang MC, Yang PH, Chu SM, Fu JH, Lai JY. Clinical impacts of delayed diagnosis of Hirschsprung's disease in newborn infants. *Pediatr Neonatol* 2012; **53**: 133-137 [PMID: 22503261 DOI: 10.1016/j.pedneo.2012.01.011]
 - 26 **Kapur RP**, Smith C, Ambartsumyan L. Postoperative Pullthrough Obstruction in Hirschsprung Disease: Etiologies and Diagnosis. *Pediatr Dev Pathol* 2020; **23**: 40-59 [PMID: 31752599 DOI: 10.1177/1093526619890735]
 - 27 **Taylor MA**, Bucher BT, Reeder RW, Avansino JR, Durham M, Calkins CM, Wood RJ, Levitt MA, Drake K, Rollins MD. Comparison of Hirschsprung Disease Characteristics between Those with a History of Postoperative Enterocolitis and Those without: Results from the Pediatric Colorectal and Pelvic Learning Consortium. *Eur J Pediatr Surg* 2021; **31**: 207-213 [PMID: 32947626 DOI: 10.1055/s-0040-1716876]
 - 28 **Hagens J**, Reinshagen K, Tomuschat C. Prevalence of Hirschsprung-associated enterocolitis in patients with Hirschsprung disease. *Pediatr Surg Int* 2022; **38**: 3-24 [PMID: 34595554 DOI: 10.1007/s00383-021-05020-y]
 - 29 **Knaus ME**, Pendola G, Srinivas S, Wood RJ, Halaweish I. Social determinants of health and Hirschsprung-associated enterocolitis. *J Pediatr Surg* 2022 [PMID: 36371352 DOI: 10.1016/j.jpedsurg.2022.09.039]
 - 30 **Zaitoun I**, Erickson CS, Barlow AJ, Klein TR, Heneghan AF, Pierre JF, Epstein ML, Gosain A. Altered neuronal density and neurotransmitter expression in the ganglionated region of Ednr^b null mice: implications for Hirschsprung's disease. *Neurogastroenterol Motil* 2013; **25**: e233-e244 [PMID: 23360229 DOI: 10.1111/nmo.12083]
 - 31 **Cheng LS**, Schwartz DM, Hotta R, Graham HK, Goldstein AM. Bowel dysfunction following pullthrough surgery is associated with an overabundance of nitergic neurons in Hirschsprung disease. *J Pediatr Surg* 2016; **51**: 1834-1838 [PMID: 27570241 DOI: 10.1016/j.jpedsurg.2016.08.001]
 - 32 **Brooks LA**, Fowler KL, Veras LV, Fu M, Gosain A. Resection margin histology may predict intermediate-term outcomes in children with rectosigmoid Hirschsprung disease. *Pediatr Surg Int* 2020; **36**: 875-882 [PMID: 32504125 DOI: 10.1007/s00383-020-04689-x]
 - 33 **Moesch M**, Usemann J, Bruder E, Romero P, Schwab C, Niesler B, Tapia-Laliena MA, Khasanov R, Nisar T; Study Group NIG Retro, Holland-Cunz S, Keck S. Associations of Mucosal Nerve Fiber Innervation Density with Hirschsprung-Associated Enterocolitis: A Retrospective Three-Center Cohort Study. *Eur J Pediatr Surg* 2022 [PMID: 35777734 DOI: 10.1055/a-1889-6355]
 - 34 **Keck S**, Galati-Fournier V, Kym U, Moesch M, Usemann J, Müller I, Subotic U, Tharakan SJ, Krebs T, Stathopoulos E, Schmittenbecher P, Cholewa D, Romero P, Reingruber B, Bruder E; Group NS, Holland-Cunz S. Lack of Mucosal Cholinergic Innervation Is Associated With Increased Risk of Enterocolitis in Hirschsprung's Disease. *Cell Mol Gastroenterol Hepatol* 2021; **12**: 507-545 [PMID: 33741501 DOI: 10.1016/j.jcmgh.2021.03.004]
 - 35 **Imamura A**, Puri P, O'Briain DS, Reen DJ. Mucosal immune defence mechanisms in enterocolitis complicating Hirschsprung's disease. *Gut* 1992; **33**: 801-806 [PMID: 1624163]
 - 36 **Aslam A**, Spicer RD, Corfield AP. Children with Hirschsprung's disease have an abnormal colonic mucus defensive barrier independent of the bowel innervation status. *J Pediatr Surg* 1997; **32**: 1206-1210 [PMID: 9269971 DOI: 10.1016/s0022-3468(97)90683-7]
 - 37 **Yildiz HM**, Carlson TL, Goldstein AM, Carrier RL. Mucus Barriers to Microparticles and Microbes are Altered in Hirschsprung's Disease. *Macromol Biosci* 2015; **15**: 712-718 [PMID: 25644515 DOI: 10.1002/mabi.201400473]
 - 38 **Gork AS**, Usui N, Ceriati E, Drongowski RA, Epstein MD, Coran AG, Harmon CM. The effect of mucin on bacterial translocation in I-407 fetal and Caco-2 adult enterocyte cultured cell lines. *Pediatr Surg Int* 1999; **15**: 155-159 [PMID: 10370012 DOI: 10.1007/s003830050544]
 - 39 **Mattar AF**, Coran AG, Teitelbaum DH. MUC-2 mucin production in Hirschsprung's disease: possible association with enterocolitis development. *J Pediatr Surg* 2003; **38**: 417-21; discussion 417 [PMID: 12632359 DOI: 10.1053/jpsu.2003.50071]
 - 40 **Thiagarajah JR**, Yildiz H, Carlson T, Thomas AR, Steiger C, Pieretti A, Zukerberg LR, Carrier RL, Goldstein AM. Altered goblet cell differentiation and surface mucus properties in Hirschsprung disease. *PLoS One* 2014; **9**: e99944 [PMID: 24945437 DOI: 10.1371/journal.pone.0099944]
 - 41 **Lui VC**, Li L, Sham MH, Tam PK. CDX-1 and CDX-2 are expressed in human colonic mucosa and are down-regulated in patients with Hirschsprung's disease associated enterocolitis. *Biochim Biophys Acta* 2001; **1537**: 89-100 [PMID: 11566252 DOI: 10.1016/s0925-4439(01)00056-4]
 - 42 **Kobayashi H**, Hirakawa H, Puri P. Overexpression of intercellular adhesion molecule-1 (ICAM-1) and MHC class II antigen on hypertrophic nerve trunks suggests an immunopathologic response in Hirschsprung's disease. *J Pediatr Surg* 1995; **30**: 1680-1683 [PMID: 8749923 DOI: 10.1016/0022-3468(95)90451-4]

- 43 Nakamura H, O'Donnell AM, Tomuschat C, Coyle D, Puri P. Altered expression of caveolin-1 in the colon of patients with Hirschsprung's disease. *Pediatr Surg Int* 2019; **35**: 929-934 [PMID: 31256294 DOI: 10.1007/s00383-019-04505-1]
- 44 Frykman PK, Nordenskjöld A, Kawaguchi A, Hui TT, Granström AL, Cheng Z, Tang J, Underhill DM, Iliev I, Funari VA, Wester T; HAEC Collaborative Research Group (HCRG). Characterization of Bacterial and Fungal Microbiome in Children with Hirschsprung Disease with and without a History of Enterocolitis: A Multicenter Study. *PLoS One* 2015; **10**: e0124172 [PMID: 25909773 DOI: 10.1371/journal.pone.0124172]
- 45 Li Y, Poroyko V, Yan Z, Pan L, Feng Y, Zhao P, Xie Z, Hong L. Characterization of Intestinal Microbiomes of Hirschsprung's Disease Patients with or without Enterocolitis Using Illumina-MiSeq High-Throughput Sequencing. *PLoS One* 2016; **11**: e0162079 [PMID: 27603009 DOI: 10.1371/journal.pone.0162079]
- 46 Parker KD, Mueller JL, Westfal M, Goldstein AM, Ward NL. A pilot study characterizing longitudinal changes in fecal microbiota of patients with Hirschsprung-associated enterocolitis. *Pediatr Surg Int* 2022; **38**: 1541-1553 [PMID: 35951092 DOI: 10.1007/s00383-022-05191-2]
- 47 Arbizu RA, Collins D, Wilson RC, Alekseyenko AV. Evidence for Differentiation of Colon Tissue Microbiota in Patients with and without Postoperative Hirschsprung's Associated Enterocolitis: A Pilot Study. *Pediatr Gastroenterol Hepatol Nutr* 2021; **24**: 30-37 [PMID: 33505891 DOI: 10.5223/pghn.2021.24.1.30]
- 48 Wall N, Kastenber Z, Zobell S, Mammen L, Rollins MD. Use of an enterocolitis triage and treatment protocol in children with Hirschsprung disease reduces hospital admissions. *J Pediatr Surg* 2020; **55**: 2371-2374 [PMID: 32553451 DOI: 10.1016/j.jpedsurg.2020.05.004]
- 49 Svetanoff WJ, Dekonenko C, Osuchukwu O, Oyetunji TA, Aguayo P, Fraser JD, Juang D, Snyder CL, Hendrickson R, Peter SS, Rentea RM. Inpatient management of Hirschsprung's associated enterocolitis treatment: the benefits of standardized care. *Pediatr Surg Int* 2020; **36**: 1413-1421 [PMID: 33001257 DOI: 10.1007/s00383-020-04747-4]
- 50 Svetanoff WJ, Lopez J, Aguayo P, Hendrickson RJ, Oyetunji TA, Rentea RM. The impact of botulinum injection for hospitalized children with Hirschsprung-associated enterocolitis. *Pediatr Surg Int* 2021; **37**: 1467-1472 [PMID: 34309717 DOI: 10.1007/s00383-021-04966-3]
- 51 Svetanoff WJ, Lim-Beutal IIP, Wood RJ, Levitt MA, Rentea RM. The utilization of botulinum toxin for Hirschsprung disease. *Semin Pediatr Surg* 2022; **31**: 151161 [PMID: 35690464 DOI: 10.1016/j.sempedsurg.2022.151161]
- 52 Roorda D, Abeln ZA, Oosterlaan J, van Heurn LW, Derikx JP. Botulinum toxin injections after surgery for Hirschsprung disease: Systematic review and meta-analysis. *World J Gastroenterol* 2019; **25**: 3268-3280 [PMID: 31333317 DOI: 10.3748/wjg.v25.i25.3268]
- 53 Chumpitazi BP, Fishman SJ, Nurko S. Long-term clinical outcome after botulinum toxin injection in children with nonrelaxing internal anal sphincter. *Am J Gastroenterol* 2009; **104**: 976-983 [PMID: 19259081 DOI: 10.1038/ajg.2008.110]
- 54 Soh HJ, Nataraja RM, Pacilli M. Prevention and management of recurrent postoperative Hirschsprung's disease obstructive symptoms and enterocolitis: Systematic review and meta-analysis. *J Pediatr Surg* 2018; **53**: 2423-2429 [PMID: 30236605 DOI: 10.1016/j.jpedsurg.2018.08.024]
- 55 Zhang X, Li L, Li SL, Li SX, Wang XY, Tang ST. Primary laparoscopic endorectal pull-through procedure with or without a postoperative rectal tube for hirschsprung disease: a multicenter perspective study. *J Pediatr Surg* 2020; **55**: 381-386 [PMID: 31296328 DOI: 10.1016/j.jpedsurg.2019.06.013]
- 56 Lewit RA, Kuruvilla KP, Fu M, Gosain A. Current understanding of Hirschsprung-associated enterocolitis: Pathogenesis, diagnosis and treatment. *Semin Pediatr Surg* 2022; **31**: 151162 [PMID: 35690459 DOI: 10.1016/j.sempedsurg.2022.151162]
- 57 Demehri FR, Halaweish IF, Coran AG, Teitelbaum DH. Hirschsprung-associated enterocolitis: pathogenesis, treatment and prevention. *Pediatr Surg Int* 2013; **29**: 873-881 [PMID: 23913261 DOI: 10.1007/s00383-013-3353-1]



Published by **Baishideng Publishing Group Inc**
7041 Koll Center Parkway, Suite 160, Pleasanton, CA 94566, USA

Telephone: +1-925-3991568

E-mail: bpgoffice@wjgnet.com

Help Desk: <https://www.f6publishing.com/helpdesk>

<https://www.wjgnet.com>

