

The authors described a case of patient with traumatic pancreatic lesion, including diagnostic and work-up details. The case presentation is quite long with an excessive description of the patient recovery. Please summarize the most important data. Radiological description is not adequate in particular CT findings should be reported as direct and/or indirect signs (see 10.1148/rg.2021200077). Furthermore, the authors should explain why Magnetic resonance cholangiopancreatography was not performed as prior examination after Ct for the evaluation of the pancreatic duct integrity.

Dear reviewer

1. According to your suggestion, the patient diagnosis, treatment and follow-up data have been simplified and summarized.
2. In this case, complete rupture of pancreatic neck was well established CT(Fig 2A), so we did not perform MRCP.

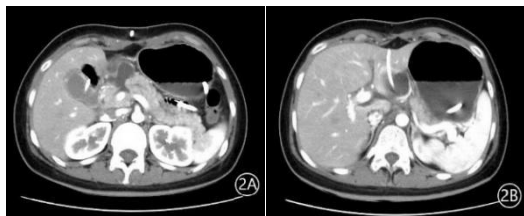


Figure 2: Abdominal CT showing A. localized rupture of the pancreatic head/neck; and B. a pseudocyst, drained with a catheter