

Dear Editor,

On behalf of my co-authors, we thank you again for giving us an opportunity to revise our manuscript, we appreciate editor and reviewers very much for their positive and constructive comments and suggestions on our manuscript entitled “Severe thrombocytopenia after anti-pulmonary infection by Latamoxef: A case report (World Journal of Clinical Cases, Manuscript NO: 70854)”..

We sincerely thank the reviewers for their valuable comments, which not only help us improve our present manuscript but also provide some new ideas for our future studies. Revised parts are marked in red in the revised manuscript. Our manuscript has been reviewed and re-edited by a professional English editor to minimize grammatical mistakes. The misleading information had been removed. We hope that the revisions in the manuscript and our accompanying responses will be sufficient to make our manuscript suitable for publication in “World Journal of Clinical Cases”.

The main corrections in the paper and the responds to the reviewer’s comments are as follows:

Reviewer #1:

1. The manuscript is not using the WJCC official template.

Response: Thanks very much for your advice. We have made a correction according to the WJCC official template.

2. Why did you define thrombocytopenia as $PLT < 100\ 000/mm^3$ and not $< 150\ 000/mm^3$ as usual?

Response: Thanks very much for your advice. The range of platelet counts in normal population varies by age, sex, and race. At present, the normal range of platelet count widely recognized and applied in China is $(100-300) \times 10^9/L$. Although the $PLT < 150 \times 10^9/L$ is usually defined as absolute thrombocytopenia in European and American countries, healthy people with a platelet count of $(100-150) \times 10^9/L$ did not show significant bleeding tendency^[1, 2]. Therefore, combining with clinical practice, $PLT < 100 \times 10^9/L$ was used as the standard of thrombocytopenia in Chinese population.

Reference:

- [1]. Internal medicine branch of Chinese Medical Association. Expert consensus for diagnosis and treatment of thrombocytopenia in China. *Chin J Intern Med* 2020; 59(7): 498-510.
- [2]. Stasi R, Amadori S, Osborn J, et al. Long-term outcome of otherwise healthy individuals with incidentally discovered borderline thrombocytopenia. *PLoS Med* 2006, 3(3): e24.

3. Why did the patient receive antitussive and expectorant treatment for pneumonia? It makes no sense to me? How can one expectorate if he cannot cough?

Response: Thanks very much for your advice. We have revised the misunderstanding parts and made a correction according to your advice. This treatment indeed may unreasonable.

According to the Guidelines for the primary care of adult community-acquired pneumonia (2018) ^[3], P122 recommends: Cough and expectoration treatment: too severe cough may lead to cough syncope, airway spasm and other complications. For early pneumonia and some atypical pneumonia, if the patient's symptoms are mainly dry cough, antitussive drugs can be used as appropriate. When the sputum volume is too much or there is purulent sputum, the patient may have difficulty in expectoration. Expectorant drugs and atomization can be given to reduce the viscosity of sputum and promote expectoration. Physical therapy such as postural drainage, turning over and patting back can promote sputum drainage.

Reference:

- [3]. Chinese medical association. Guidelines for the primary care of adult community acquired pneumonia (2018). *Chin J Gen Pract* 2019,18(2): 117-126.

4. Why did you prescribe leucogen? Isn't it reserved for chemotherapy-induced neutropenia (not leukopenia)?

Response: Thanks very much for your advice. We have made a correction in line 118. This is the treatment plan from the outside hospital, and we assume the reason for the use of leucogen was as follow:

Half a year ago, the patient stopped mesalazine and changed to Adamuzumab (40

mg, every 2 weeks) for the treatment of Crohn's disease. Before admission, the white blood cell count of the patient was $2.6 \times 10^9/L$, lower than the normal value. According to the literature^[4]: The incidence of granulocytopenia caused by adamuzumab was 0.6-0.9%, which was occurred between 2-56 weeks of exposure. Since the cause of adamuzumab could not be ruled out, the prescription of previous hospital was continued and leucogen was used for the treatment of leukopenia.

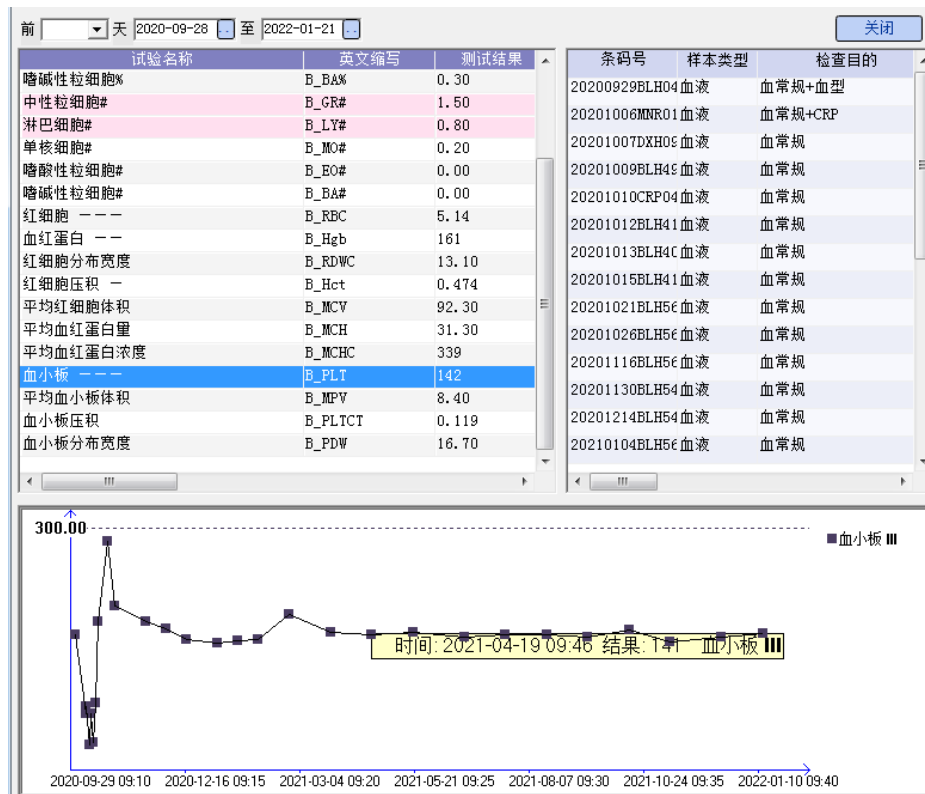
Reference:

[4]. Bessissow T, Renard M, Hoffman I, et al. Review article: non-malignant haematological complications of anti-tumour necrosis factor alpha therapy. *Aliment Pharmacol Ther* 2012 Aug; 36(4): 312-23.

5. Lines 171-176: how did you exclude all these causes? Please provide details.
How can you exclude ITP if the patient was only followed-up for 5 weeks? Infections are a common cause of secondary ITP.

Response: Thanks very much for your advice. We have revised the misunderstanding parts and made a correction according to your advice.

The patient was actually followed up for a long time. Monthly outpatient follow-up results after discharge showed that platelet counts remained stable and in the normal range, and thrombocytopenia did not occur again, which was shown in the follow figure:



Moreover, we exclude all these causes in lines171-176 (new manuscript: line 192-202) by the following ways:

(1) **Tuberculosis of spleen:** Firstly, tuberculosis infection often leads to splenic tissue damage and decline of splenic function, but generally does not cause thrombocytopenia. Secondly, dynamic observation of the medical history suggested that the patient's body temperature was basically normal at admission, and fluctuated around 37°C until the 9th day of the treatment. Results of auxiliary examination on admission showed: Hypersensitive CRP: 12.38mg/L, white blood cell count: 2600/uL, neutrophil (%): 67.6%, PLT: 140000/uL. By day 9 (8:00 am) after treatment, hypersensitive CRP: 10.04mg/L, white blood cell count: 2800/uL, neutrophil (%): 68.8%, PLT: 44,000/uL, no sepsis. Thrombocytopenia occurred after 9days after treatment, and the progress rate was fast, which was not consistent with the course of thrombocytopenia caused by splenic tuberculosis. Again, the upper abdominal CT of the patient suggested an enlarged spleen, multiple small round low-density shadows in the spleen, and unclear lesion boundary. The enhancement examination showed clear lesion boundary, and the internal enhancement was not obvious, and finally no

pathological diagnosis of the spleen tissue was found. Therefore, the possibility of thrombocytopenia caused by splenic tuberculosis was excluded.

(2) **Pseudothrombocytopenia:** Pseudothrombocytopenia generally does not show bleeding symptoms, but this patient's thrombocytopenia also showed scattered purpura and ecchymosis on the skin of the limbs and trunk, so it was excluded.

(3) **Primary immune thrombocytopenia:** According to the literature^[5] "Guidelines for the Treatment of Adult Primary Immune thrombocytopenia in China", the diagnosis of primary immune thrombocytopenia was a clinical exclusion diagnosis. The patient did have at least two routine blood tests showing reduced platelet count, and no blood cell morphology examination was performed, but the patient had splenomegasis, and drug-induced thrombocytopenia could not be excluded. The patient used recombinant human thrombopoietin (15,000units/day), human immunoglobulin (20.0g/day), 15 units platelets and 5 mg dexamethasone, but the platelet count increased and then decreased. However, on the third day after the withdrawal of Latamoxef, platelet returned to normal, and did not drop below 100000/uL in the follow-up for more than 1 year. Therefore, the possibility of primary immune thrombocytopenia was not considered.

Reference:

[5]. Liu XG, Bai XC, Chen FP, et al. Chinese guidelines for treatment of adult primary immune thrombocytopenia. *Int J Hematol* 2018 Jun; 107(6): 615-623.

(4) Other drug-induced immune thrombocytopenia:

According to the literature^[1, 6] (Pathophysiology and Diagnosis of drug-induced Immune Thrombocytopenia), Common drugs that can cause thrombocytopenia are Abximab, carbamazepine, ceftriaxone, cyclotibatide, heparin, ibuprofen, mirtazapine, oxaliplatin, penicillin, quinine, quinidine, rifampin, suramin, tirofiban, trimethoprim-sulfamethoxazole, and vancomycin et al. The exclusion of immune thrombocytopenia caused by rifampicin was showed in the manuscript line 172-185. Other drugs, isoniazid, ethambutol and pyrazinamide, were used until discharge, and without thrombocytopenia occurred during use, so other drug-induced immune

thrombocytopenia were excluded.

Reference:

- [6]. Wayne C, Guery EA, Rollin J, et al. Pathophysiology and Diagnosis of Drug-Induced Immune Thrombocytopenia. *J Clin Med* 2020; 9.

(5) **Food and beverages:** The patient had no special food or drink during treatment.

(6) **Infections:** First of all, the endotoxin test, novel coronavirus nucleic acid test, *Helicobacter pylori* (Hp) antibody, AIDS antibody (1+2) and hepatitis A, C, D, E and G antibodies were all negative. The core antibody of hepatitis B was weakly positive, the surface antibody of hepatitis B was positive, and the lymphocyte subsets were all within the normal range. Secondly, the patient's body temperature was basically normal at admission, and fluctuated around 37°C until the 9th day of thrombocytopenia. Results of auxiliary examination on admission: Hypersensitive CRP 12.38mg/L, white blood cell count 2600/uL, neutrophil % 67.6%, PLT 140000/uL. When thrombocytopenia occurred after 9 days' treatment, hypersensitive CRP: 10.04mg/L, white blood cell count: 2800/uL, neutrophil (%): 68.8%, PLT: 44000/uL. Blood pressure was stable. Respiratory rate and heart rate were normal, and no sepsis was found. Therefore, the possibility of platelet destruction caused by infection was basically ruled out.

(7) **Hypersplenism due to chronic liver disease:** The patient's hepatitis A, C, D, E and G antibodies were all negative, and the hepatitis B tests indicated that the core antibody of hepatitis B was weak positive, and the surface antibody of hepatitis B was positive. There was no history of chronic liver disease, and the liver function indexes were in the normal range. Therefore, the possibility of hypersplenism caused by chronic liver disease was excluded.

(8) **Alcohol excess:** The patient had no history of alcohol consumption and did not consume alcohol during hospitalization. Therefore, the possibility of thrombocytopenia caused by excessive alcohol was excluded.

(9) **Nutrient deficiencies:** Firstly, the patient weighed 59 kg, was 170 cm tall

and had a BMI of 20.4 kg/m², within normal range. Secondly, albumin level fluctuated between 39.0-42.5 g/L (reference range: 40.0-55.0 g/L) and pre-albumin level between 187.0-251.0 mg/L (reference range: 170.0-400.0 mg/L) from admission to discharge. In addition, the detection of folic acid + ferritin +VB12 were in the normal range (ferritin 167.0 ug/L (reference value: 21.8-374.0ug/L), folic acid 6.5μg/L (6.0-20.0 ug/L), VB12 220 pmol/L (reference value: 133.0-675.0 pmol/L)). The above data suggest that there is no malnutrition and large fluctuations in indicators. Therefore, thrombocytopenia caused by nutritional deficiency was excluded.

(10) **Rheumatologic:** The rheumatoid factor of this patient was less than 20.0 IU/mL (0.0-200.0 IU/mL) and anti-O factor was 74.5 IU/mL (0.0-20.0 IU/mL). Anti-granulocyte antibody (cytoplasmic type) (ANCA) was negative, and no comprehensive inflammatory manifestations such as arthropathy, redness, swelling, heat and pain, and impaired joint function were observed. Lymphocyte subsets were all in the normal range. So the thrombocytopenia caused by rheumatism is excluded basically.

(11) **Thrombotic microangiopathy:** The patient, male, 28 years old, had no history of coronary heart disease, chest tightness, shortness of breath and other uncomfortable symptoms. Multiple D-dimer tests from admission to discharge were negative (within the normal range), and the DVT Well score was 0. Therefore, the possibility of thrombocytopenia caused by thrombotic microangiopathy was excluded [7].

Reference:

[7]. Expert committee of Guidelines for prevention and treatment of Thrombotic Diseases in China. Guidelines for the Prevention and treatment of thrombotic diseases in China. *Chinese medical journal* 2018; 98 (36) : 2861-2888.

(12) **Myelodysplasia:** Physical examination on admission showed normal spine, no tenderness, no percussion pain, normal range of motion and normal limbs.

(13) **Cancer with disseminated intravascular:** All tumor markers were

negative, and no malignant cells were found in bronchoscopic brush and alveolar lavage fluid pathological reports. Lymphocyte subsets were all in the normal range.

(14) **Coagulation:** From admission to discharge, the coagulation routine indexes of the patients were normal.

(15) **Cancer with bone marrow infiltration or suppression:** All tumor markers were negative. Lymphocyte subsets were all in the normal range.

(16) **Post-transfusion purpura:** Scattered purpura and ecchymosis were seen on the skin of the limbs and trunk (day 12) before transfusion.

6. The references need to be revised to match the style of WJCC.

Response: Thanks very much for your advice. We have revised the misunderstanding parts and made a correction according to your advice.

7. The English language of the paper can be improved and polished.

Response: Thanks very much for your advice. We have revised the misunderstanding parts and made a correction according to your advice.

8. The paper is not formatted according to the CARE guidelines.

Response: Thanks very much for your advice. We have revised the misunderstanding parts and made a correction according to your advice.

9. There are also other reports of thrombocytopenia induced by latamoxef (moxalactam). Please discuss them and also check the Chinese databases of medical literature to identify other reports.

Response: Thanks very much for your advice. We have made a correction in line 212-223 according to your advice , as described below:

We searched PubMed, Embase, CNKI, Wan-fang, and VIP and located four articles related to thrombocytopenia caused by latamoxef^[5, 6, 7, 16]. Although several studies reported that latamoxef could cause thrombocytopenia, thrombocytopenia induced by latamoxef in the Chinese population has never been reported previously.

The literature suggests that one should use latamoxef cautiously in elderly patients with hepatic and renal dysfunction, history of ulcers, long-term use of broad-spectrum antibiotics, poor coagulation function, bleeding tendency, or use of anticoagulant and antiplatelet drugs^[5, 6, 16]. The patient in our case had none of these risk factors; however, he had recurrent fevers for more than one month. Fever leads to high metabolic rates, and disseminated tuberculosis is a consumptive disease that reduces immunity. He also had Crohn's disease for more than five years and was treated with adalimumab as immunosuppressive therapy. Overall, the patient's tolerance to drug-induced thrombocytopenia was lower than that of healthy adults.

Reviewer #2:

Include some indications for splenectomy in thrombocytopenia. Include the following reference: Socea B, Diaconu C, Bratu OG, Pantea Stoian A, Constantin VD. Splenectomy in Immune Thrombocytopenia: When, Why and How? Journal of palliative care, 2019, 12(1): 16-19.

Response: Thanks very much for your advice. We have made a correction according to your advice, the reference was cited in line 68-69.