

Response to Review Comments

(Manuscript Number: 78877)

I am very much thankful to the reviewers for their deep and thorough review. I have revised my present case report in the light of their useful suggestions and comments. I hope my revision has improved the paper to a level of their satisfaction. Number wise answers to their specific comments/suggestions/queries are as follows.

Response to Reviewer #1 Comments

Comment 1: I think more details needs to be adressed about the past history of the patient addressing on description of syncope and the cause of rupture of electrode.

Response: Respected reviewer thank you for your comments. According to your suggestion, We added the patient's past history, The patient had a history of hypertension for 10years. She took amlodipine besylate 5 mg QD regularly to control her blood pressure, noting that the blood pressure level was controlled well. She did not take any other medications. The patient denied history of coronary heart disease, cerebral infarction, diabetes. (Page 4 line8-12)

Comment 2: i think it needs reordering in paragraphs, content quite good

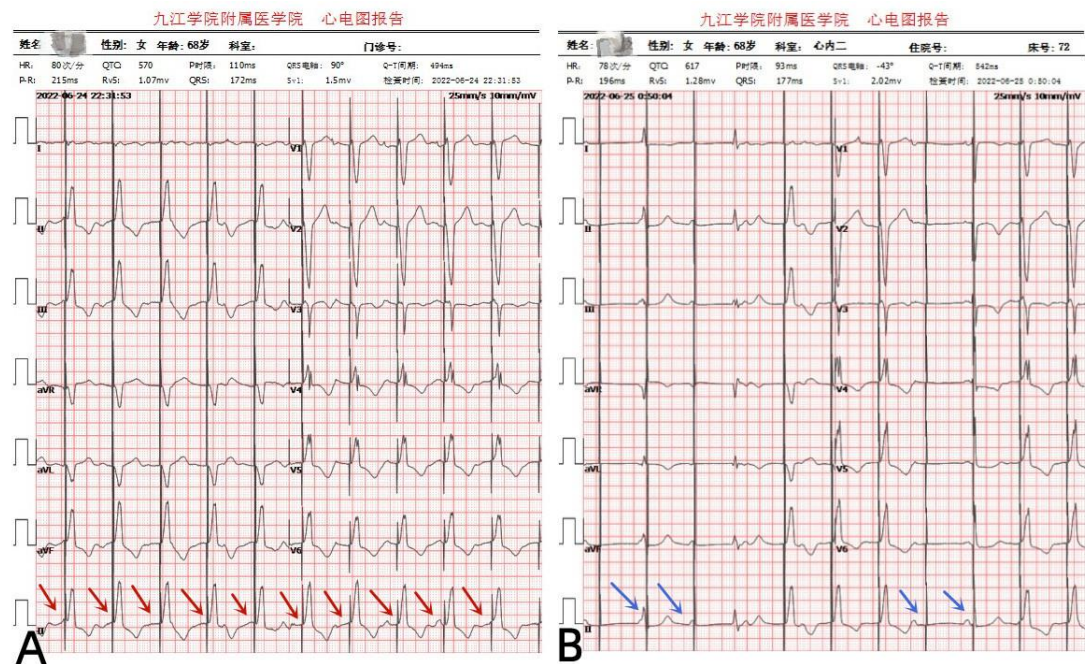
Response: According to your suggestion, We adjusted the order of some contents in the discussion section

Comment 3: References. Does the manuscript cite appropriately the latest, important and authoritative references in the introduction and discussion sections? Does the author self-cite, omit, incorrectly cite and/or over-cite references? no references in introduction section, reference 2,3,4 old,otherwise no self citation or overcitation

Response: ①The introduction quotes a document; ②2. 3 References have been replaced with the latest ones, 4 references are meaningful and continue to be retained,③no self citation or overcitation

Comment 4: xrays are good but ECG need to be arrowed

Response: Arrows added to ECG



Comment 5: The ARRIVE Guidelines - Basic study. Did the author prepare the manuscript according to the appropriate research methods and reporting? no, few items missed (CARE checklist)

Response: The manuscript has been modified according to the requirements of CARE checklist 2016

Comments 6: Ethics statements. For all manuscripts involving human studies and/or animal experiments, author(s) must submit the related formal ethics documents that were reviewed and approved by their local ethical review committee. Did the manuscript meet the requirements of ethics? only consent from patients and efforts will be done to conceal patients identity

Response: Manuscripts meet ethical requirements, The consent of the patient and family members has been obtained

Comments 7: First, what are the original findings of this manuscript? What are the new hypotheses that this study proposed? What are the new phenomena that were

found through experiments in this study? What are the hypotheses that were confirmed through experiments in this study? rupture of pacemaker electrode causing syncope, the same.

Response: The case reported here is the repeated loss of consciousness caused by the rupture of pacemaker

Comments 8: Second, what are the quality and importance of this manuscript? What are the new findings of this study? What are the new concepts that this study proposes? What are the new methods that this study proposed? Do the conclusions appropriately summarize the data that this study provided? What are the unique insights that this study presented? What are the key problems in this field that this study has solved? yes , the prevention of electrode rupture

Response: Avoid being close to the clavicle at the pacemaker electrode implantation site to reduce electrode wear

Comments 9: Third, what are the limitations of the study and its findings? What are the future directions of the topic described in this manuscript? What are the questions/issues that remain to be solved? What are the questions that this study prompts for the authors to do next? How might this publication impact basic science and/or clinical practice? i think no limitations needed

Response: The axillary vein approach should be selected as far as possible to reduce the probability of pacemaker electrode wear

Response to Reviewer #2 Comments

Comment 1: The presented basal images do not show evident macroscopic lead fracture (only mild angulation of the lead at the subclavian space). The extracted lead is completely broken and exposed of internal material likely due to the extraction procedure itself.

Response: Respected reviewer thank you very much for your valuable suggestions. Your suggestions made a huge improvement in our research paper. During the operation, the very obvious electrode fracture image can be seen by pulling the electrode, but unfortunately, the image has not been saved, but according to the patient's chest X-ray, intermittent poor pacing and low impedance of the electrode, the electrode fracture can also be proved laterally

Comment 2: The patient seems in sinus rhythm, any explanation for the VVI choice instead of DDD pacing?

Response: The patient chose a single chamber permanent pacemaker because of family economic problems (page 2 line 10-14)

Comment 3: Minor comments: specify if the first implant was done 6 or 7 years ago (there is discrepancy in the Text).

Response: It was six years ago, a clerical error

Comment 4: The English language needs serious editing through the text.

Response: We retouched the manuscript

Response to Reviewer #3 Comments

No modification

Response to Reviewer #4 Comment

No modification

Kind regards,
Xiao-Yong Zhu