

Name of Journal: *World Journal of Clinical Cases*

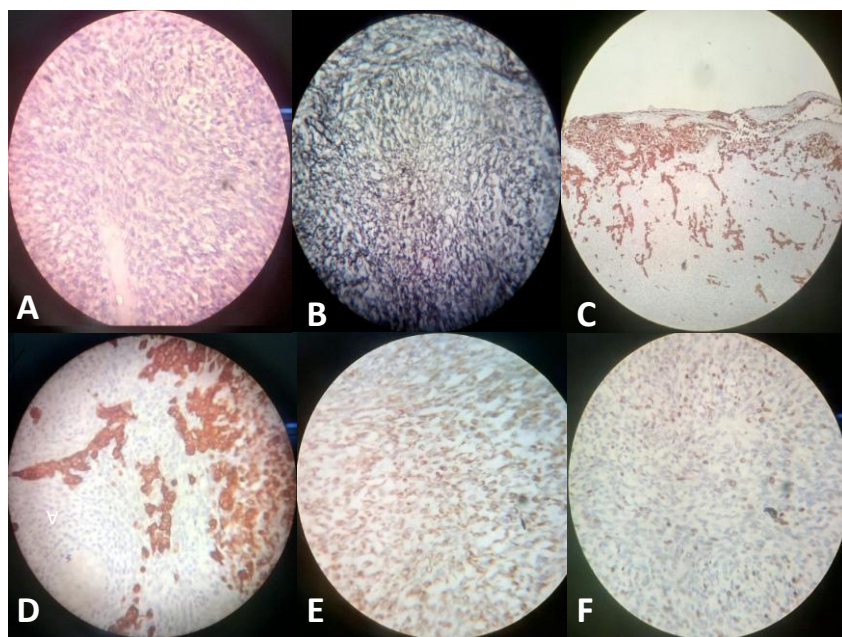
ESPS Manuscript NO: 24438

Manuscript Type: Case Report

ANSWER LETTER

1.

1)



(A) Spindle shape tumour cells (H&E,X400)

(B) Foci of reticulin-rich tumor cells suggest sarcomatous

Component

(C) Glial cell positive for glial fibrillary acidic protein(GFAP,X100)

(D) Glial cell positive for glial fibrillary acidic protein (GFAP,X400)

(E) Spindle shape tumor cell positive for vimentin (vimentin,X400)

(F) Spindle shape tumor cell shows high MIB labelling index (MIB,X400)

2) other differential diagnosis was ruled out by negative staining for LCA, EMA,CK7,CK20

2. No evidence of metastasis in other body area. CECT chest and abdomen was done. Patient was referred to radiotherapy department for radiotherapy and chemotherapy after histopathology report and she was enrolled for radiotherapy. Prognosis explained to her father.

3. Median survival is slightly higher in paediatric cases as compared to adult

Cases. rest I could not find any other difference b/w adult and paediatric cases

4. Sir Previous publications were searched on pubmed and Google scholar data base. Case report by Martin J et al in Case Rep Med 2014 is included in manuscript.