

Dear Editors:

Thank you very much for your letter and advice on our manuscript. We have resubmitted new version of manuscript in accordance with recommendations of the technical editor. We have addressed the comments raised by the reviewers, and the amendments are highlighted in red in the revised manuscript. We hope that the revision is acceptable and look forward to hearing from you soon.

Point-by-point responses to the reviewers are listed below this letter.

Sincerely yours,

Xun-Ze Shen.

2021/05/01

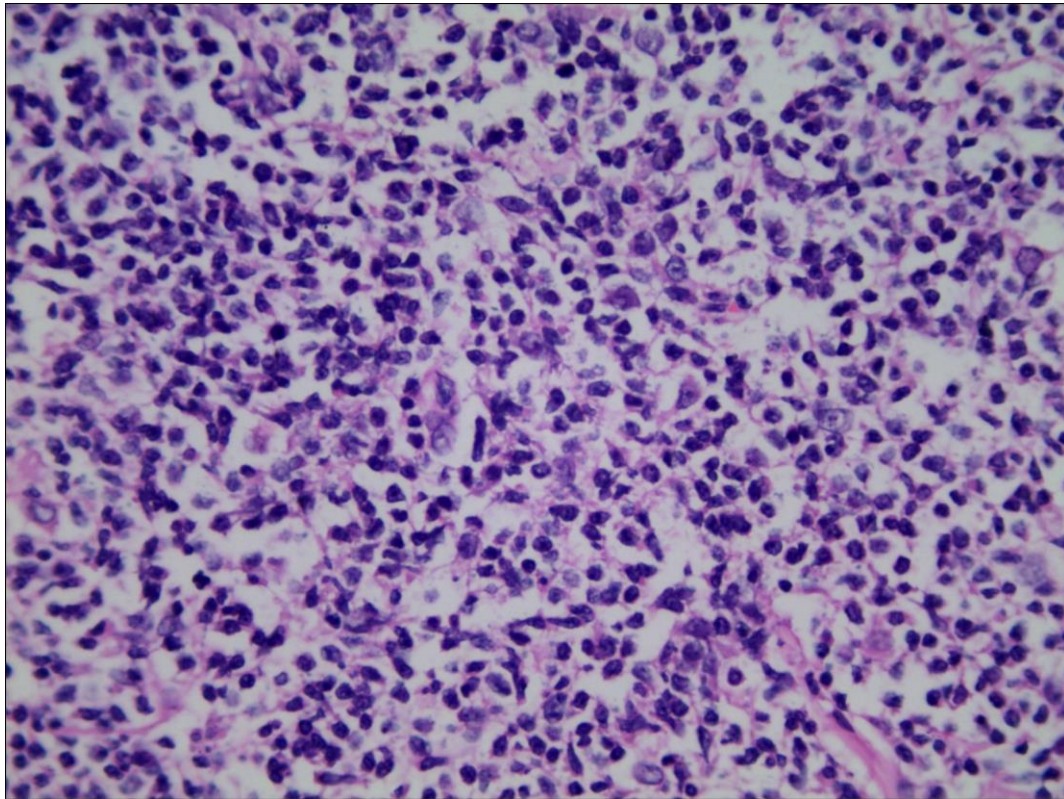
Major concern:

1. Please discuss how to exclude the possibility of a metastatic lesion in the discussion section based upon the clinical survey for the patient.

Primary pelvis and ureteral lymphoma must be differentiated from metastatic tumor in diagnosis. Metastatic tumors usually have the presence or history of the primary malignancy, and metastatic tumors are often multiple. Solitary metastasis may occasionally occur in renal parenchyma, but rarely only in the pelvis and ureter^[7].

7 Haddad FS. Metastases to the ureter. Review of the world literature, and three new case reports. J Med Liban. 1999;47:265-271. [PMID: [21558843](#)] (New reference)

2. A higher HE magnification (Fig. 3A) would be needed to demonstrate the dysplastic features of the tumor cells more clearly to the readers.



Minor concerns:

1. In the first paragraph of the discussion section, the authors state "Primary renal pelvis and ureteral lymphomas are extremely rare, and only a few cases have been reported in the literature." This sentence needs adequate citations.

Primary renal pelvis and ureteral lymphomas are extremely rare, and only a few cases have been reported in the literature^[1-6].

1 Naik N, Lin M, Lin P. Genitourinary involvement of lymphomas on FDG-PET. Br J Radiol. 2018; 91:20170273. [PMID: 29322833 DOI:10.1259/bjr.20170273] (New reference)

2. For the first sentence (line 114) of the fourth paragraph of the discussion section, 'Follicular lymphoma (FL)' has already been defined before. It appears not necessary to repeat the writing as 'Follicular lymphoma (FL)'.

FL is a malignant proliferative disease of germinal center B cell origin.