

## **Response to Reviewers**

Manuscript NO: 76723: The alfapump® implantable device in the management of refractory ascites: an update

We would like to thank the Reviewers for their comments. Please find below our point-by-point responses to all the Reviewers' comments, and a modified version of our manuscript (please see below). All the changes and additions are highlighted in red text.

Dr Guido Stirnimann has provided new informations regarding his personal conflict of interest that have been inserted in the "Disclosures".

### **Responses to reviewer #1**

**Scientific Quality:** Grade B (Very good)

**Language Quality:** Grade C (A great deal of language polishing)

**Conclusion:** Minor revision

**Specific Comments to Authors:** This is a very interesting article

Thank you for your positive appreciation. We appreciate the Reviewer's understanding of the relevance of our work.

### **Responses to reviewer #2**

**Scientific Quality:** Grade C (Good)

**Language Quality:** Grade B (Minor language polishing)

**Conclusion:** Major revision

Thank you for the quality of the remarks and critiques, which have helped us to improve our manuscript. We provide our point-by-point responses to all the comments below. We hope that our modifications will be found satisfactory.

I thank the editor and the authors to have the chance to review this material. Weil-Verhoeven et al refer in their work entitled, The alfapump® implantable device in the management of refractory ascites: an update, to an innovative device to threat refractory

ascites. Even very interesting this device, the writing manner is, overall, in my opinion, too commercial. There are some issues that should be addressed.

**1. Please provide after introduction, your Data collection strategy: how and where did you look for your documentation? How many articles did you use for your material?**

Thank you for this useful suggestion. We acknowledge that the information about the data collection strategy was insufficient. We have added a paragraph after the introduction (page 4 of the manuscript):

“In this review, we describe the practical aspects of the alfapump® device implantation and discuss its effectiveness and safety as a treatment of RA, according to the current literature.

#### **Data collection strategy**

A search of PubMed and Embase was performed by two independent investigators (D.W.V. and T.T), since inception. The search terms used were “alfapump” AND “ascites”. Additionally, reference lists were manually searched for relevant literature. The articles identified by the initial search were considered for further analysis if they contained original data relating to alfapump use in patients with non-malignant ascites related to cirrhosis.”

**2. Please specify (also in this chapter) the number of the articles by type: case reports, reviews, original articles etc.**

We have also added the following sentences (page 4 in the manuscript): « The search for the terms “alfapump” AND “ascites” retrieved a total of 72 articles. Of these 72 publications, we excluded papers that were not in English (N=2), articles not published in full (N= 23), articles that were off-topic (N=7), as well as letters to the editor (N=7), editorials (N=2), errata/corrigenda (N=2), reviews (N=11), and guidelines (N=1). Thus, a final total of 17

original articles reporting data on the use of the alfapump in patients with refractory ascites related to cirrhosis were included in the review (see Supplementary figure 1).”

**3. Please provide a flow-chart with the articles found and articles included in you work?**

Thank you for this useful proposal. A flow-chart has now been added that describes the study selection process (Supplementary Figure 1).

**4. Please consider to mention the reasons for excluding some papers from you review (exclusion criteria for adequate documentation).**

We thank the Reviewer for this useful comment. The reasons for exclusion are now mentioned in the text (see response to comment 2 above, and Supplementary Figure 1).

**5. Please provide consistent data from the literature with regard to the subchapter Implantation procedure, use and follow-up of the alfapump®. Are there any recommendation of the manufacturer?**

The Reviewer is right to underline this point. We have added the following paragraph on **page 5**:

Consistent data are available in the literature and detailed procedures have been published in expert consensus statements <sup>[10]</sup> and in the article by Dembinsky et al <sup>[11]</sup>. The manufacturer provides technical instructions regarding the surgical procedure and advice regarding pre- and post-implantation care, that are consistent with expert recommendations. In accordance with these recommendations <sup>[10,11]</sup>, the patient is hospitalized 24-48 hours before implantation...”

In addition, on **Page 6**, we have changed the following sentence together and inserted the appropriate reference <sup>[10]</sup>:

“A detailed description of the surgical procedure has been published elsewhere <sup>[9, 10,11]</sup>. Briefly, it consists in the following steps: 1) skin incision, 2) bladder catheter insertion, 3) peritoneal catheter placement, 4) pump pocket creation and catheter tunnelling, 5) catheter attachment to the pump, 6) closure of the surgical incisions <sup>[11]</sup>. ”

**6. By enabling an improvement in nutritional status and a return to physical activity, the alfapump® device could limit sarcopenia and frailty- over said- please reconsider the sentence.**

We acknowledge that our phrasing may have been over-optimistic. This hypothesis is purely speculative, since the potential benefit of alfapump on sarcopenia and frailty has not been convincingly demonstrated to date. Accordingly, we have tempered the sentence as follows (**page 14**):

“By enabling an improvement in nutritional status and a return to physical activity, **we may speculate that** the alfapump® device could limit sarcopenia and frailty, **but data regarding this potential benefit are scarce and this point warrants specific evaluation in dedicated studies.**”

**7. Please state if there are any studies concerning the evaluation of the quality of life in these patients, because, so far, its should be its only benefit.**

Thank you for this relevant comment. As mentioned in the manuscript, there have been two specific analyses evaluating quality of life in patients, namely one randomized controlled trial, and one observational study. These data show that quality of life improves in patients receiving an alfapump as compared to those who do not. To emphasize this crucial point, we have modified the sentence (**pages 8-9**) as follows:

“..... after alfapump® placement compared to the control group <sup>[16]</sup>. The effect of the alfapump® on quality of life has been specifically studied in the RCT by Bureau et al <sup>[16]</sup> and in the MOSAIC study <sup>[12,23]</sup>, and it was shown that quality of life, assessed by the Chronic Liver Disease Questionnaire, was significantly improved in patients with “alfapump” compared to patients who underwent iterative paracentesis, in particular due to a reduction of ascites-related symptoms <sup>[12,16,23]</sup>. This benefit may be of interest in patients not eligible for LT”.

**8. Financial issues regarding this device vs standard of care from the light of very few to no benefits reduces very much the clinical impact of this material. Please consider to state the final conclusions focusing on this aspect.**

The Reviewer raises an important point. However, we have chosen not to further discuss the clinical benefits here. Regarding the economic repercussions, the alfapump must be compared to repeated hospitalizations for paracentesis. To date, no medico-economic study has concluded that the alfapump is superior to standard of care. However, studies are scarce and may have been hampered by too short a follow-up. We agree with the fact that the cost-effectiveness ratio of the device must be evaluated in greater depth before issuing any recommendations for its use in the general setting. We hope that the ongoing medico-economic “ARIAPUMP” study will provide answers to this key question.

In line with the Reviewer’s suggestion, we have modified the conclusion of the manuscript by adding the following sentence, **page 15**:

“.....careful selection of these frail patients is essential. The concerns related to the cost of the device, the surgical procedure of implantation, as well as the potential complications that can occur are not fully resolved yet, but the implantation....”.

We have also completed the sentence: “...liver and kidney function, age or forms of albumin compensation, cost-effectiveness.”

### **Responses to reviewer #3**

**Scientific Quality:** Grade B (Very good)

**Language Quality:** Grade B (Minor language polishing)

**Conclusion:** Accept (General priority)

**Specific Comments to Authors:** Very interesting paper with novel information

Thank you for your positive appreciation. We appreciate the Reviewer's understanding of the relevance of our work.

### **Responses to reviewer #4**

**Scientific Quality:** Grade A (Excellent)

**Language Quality:** Grade A (Priority publishing)

**Conclusion:** Accept (High priority)

**Specific Comments to Authors:** This is an excellent and thorough review on the use of alphapump in treatment for refractory ascites. The authors described clearing the working principles, indications, technical aspects and complications for the device in terms of scientific and language quality. However, as it is a proprietary device, the authors must make sure there is no conflict of interests to the commercial company selling the device.

Thank you for your positive appreciation. We appreciate the Reviewer's understanding of the relevance of our work. The question raised regarding potential conflict of interests among the authors is legitimate. The authors who designed the research, analyzed the data and wrote the paper have no conflict of interest with the commercial company selling the device.

## **The alfapump® implantable device in the management of refractory ascites: an update**

**Delphine Weil-Verhoeven, Vincent Di Martino, Guido Stirnimann, Jean-Paul Cervoni, Eric Nguyen-Khac, Thierry Thévenot.**

### Institutions

**Delphine Weil-Verhoeven, Vincent Di Martino, Jean-Paul Cervoni, Thierry Thévenot**, Service d'Hépatologie et Soins intensifs digestifs, CHRU Jean Minjoz, Besançon, France

**Delphine Weil-Verhoeven, Vincent Di Martino, Thierry Thévenot**, EA 4266 EPILAB, Université de Bourgogne Franche-Comté, Besançon, France

**Guido Stirnimann**, Department of Visceral Surgery and Medicine, Inselspital Bern, Bern University Hospital and University of Bern, Bern, Switzerland.

**Eric Nguyen-Khac**, Service d'Hépatogastroentérologie, Centre Hospitalier Universitaire Amiens-Picardie, Amiens, France

Corresponding author: Delphine Weil-Verhoeven, MD, PhD, Service d'Hépatologie et de Soins Intensifs Digestifs, Hôpital Jean Minjoz, 25000 Besançon. Tél : 03 81 66 85 94, FAX : 03 81 66 84 17, E-mail : [dweil@chu-besancon.fr](mailto:dweil@chu-besancon.fr)

Author contributions: Delphine Weil-Verhoeven designed the research; Delphine Weil-Verhoeven and Thierry Thévenot analyzed the data; Delphine Weil-Verhoeven wrote the paper; Thierry Thévenot, Vincent Di Martino, Guido Stirnimann, Jean-Paul Cervoni and Eric Nguyen-Khac made critical revisions related to important content of the revised manuscript; Delphine Weil-Verhoeven, Thierry Thévenot, Vincent Di Martino, Guido Stirnimann, Jean-Paul Cervoni and Eric Nguyen-Khac provided the final approval of the version to be published.

Disclosures: GS has received support for travel and meeting attendance, served as a speaker and participated in Advisory Boards for Sequana Medical.

Writing assistance: Fiona Ecartot revised the English for payment.

### **Abstract**

Refractory ascites (RA) is a frequent and life-threatening complication of cirrhosis. In selected patients with RA, transjugular intrahepatic portosystemic shunt (TIPS) placement and liver transplantation (LT) are currently considered as the best therapeutic alternatives to repeated large volume paracentesis. In patients with a contraindication to TIPS or LT, the alfapump® system (Sequana Medical, Ghent, Belgium) has been developed to reduce the need for iterative paracentesis, and consequently to improve the quality of life and nutritional status. We report here recent data on technical progress made since the first implantation, the efficacy and tolerance of the device, the position of the pump in the therapeutic arsenal for refractory ascites, and the grey areas that remain to be clarified regarding the optimal selection of patients who are potential candidates for this treatment.

**Keywords:** alfapump, refractory ascites, automated low flow ascites pump; cirrhosis; liver

**Core tip:** The alfapump® system (Sequana Medical laboratory, Ghent, Belgium) is a subcutaneous implantable device that enables the transfer of ascites from the peritoneal cavity to the bladder. In this review, we describe the practical aspects of alfapump® device implantation, we discuss its effectiveness and safety as a treatment of refractory ascites in cirrhotic patients, based on the most recent published data.

**Abbreviations:** AKI, acute kidney injury; LVP, large volume paracentesis; LT, liver transplantation; MELD, Model for End-stage Liver Disease; RA, refractory ascites; RCT, randomized controlled study; TFS, transplant-free survival; TIPS, transjugular portosystemic shunt.



## Introduction

Cirrhotic patients may develop a wide range of complications secondary to portal hypertension and/or liver insufficiency. Among them, ascites occurs in nearly 60% of patients with compensated cirrhosis within 10 years, during the course of their disease [1]. Approximately 10% of patients with ascites develop refractory ascites (RA), defined as ascites that cannot be mobilized by appropriate medical therapy (i.e., a low salt diet combined with diuretic therapy) [2], or whose early recurrence cannot satisfactorily be prevented. The prognosis of RA is poor, with a transplant-free survival (TFS) rate of only 50% at 6 months, notably because of an increased risk of type 2 hepatorenal syndrome (recently renamed HRS-non-AKI by the European Association for the Study of the Liver [3,4]). RA generally leads to severe malnutrition, deteriorated quality of life and uncomfortable symptoms or complications (in particular anorexia, abdominal hernia, and dyspnea). Liver transplantation (LT) is the ultimate solution for RA and should be considered systematically. In patients who are not eligible for LT because of advanced age and/or comorbidities, or for whom access to LT remains limited (low or intermediate MELD scores), alternative or “bridging” therapies should be proposed. The first-line treatment of RA consists of large volume paracentesis (LVP). This procedure, although easy to perform, is not risk-free (a risk of major complications of around 1%, especially in case of severe liver failure [5]) and LVP does not improve the patient's quality of life because of the repeated hospitalizations. Furthermore, albumin infusions, administered for the prevention of post-paracentesis circulatory dysfunction after each LVP, also contribute to a heavy healthcare burden. Transjugular portosystemic shunt (TIPS) placement reduces portal pressure and improves effective blood volume and renal function within 4 to 6 weeks, making this procedure an effective treatment for RA. In the most recent series including patients with recurrent ascites, covered TIPS was associated not only with better control of ascites, but also with a significant improvement in one-year TFS compared to patients treated with iterative paracentesis (93% vs 52%;  $p=0.003$ ) without increasing the incidence of hepatic encephalopathy [6]. However, careful selection of candidates for TIPS placement is

necessary to prevent the occurrence of short- and medium-term complications, and TIPS can ultimately be implanted in only 40% of cirrhotic patients with ascites [7]. The Automated Low-Flow Ascites Pump (alfapump®) system is a therapeutic alternative to TIPS and LT for the treatment of RA [2,8]. In this review, we describe the practical aspects of the alfapump® device implantation and discuss its effectiveness and safety as a treatment of RA, according to the current literature.

### **Data collection strategy**

A search of PubMed and Embase was performed by two independent investigators (D.W.V. and T.T), since inception. The search terms used were “alfapump” AND “ascites”. Additionally, reference lists were manually searched for relevant literature. The articles identified by the initial search were considered for further analysis if they contained original data relating to alfapump® use in patients with non-malignant ascites related to cirrhosis. The search for the terms “alfapump” AND “ascites” retrieved a total of 72 articles. Of these 72 publications, we excluded papers that were not in English (N=2), articles not published in full (N= 23), articles that were off-topic (N=7), as well as letters to the editor (N=7), editorials (N=2), errata/corrigenda (N=2), reviews (N=11), and guidelines (N=1). Thus, a final total of 17 original articles reporting data on the use of the alfapump® in patients with refractory ascites related to cirrhosis were included in the review (see flowchart of study selection in Supplementary Figure 1).

### **Technical aspects**

#### **Working principle of the alfapump®**

The basic working principle and surgical aspects of the implantation of the alfapump® have been described elsewhere [9]. Briefly, the device is manufactured by Sequana Medical (Ghent, Belgium) and obtained the CE mark in July, 2011. It comprises a battery-powered pump implanted subcutaneously in the abdominal wall, connected to a first catheter placed in the peritoneal cavity, and to a second catheter that is tunneled under the skin and connected to the bladder, thereby enabling the

transfer of ascites to the bladder for elimination via urination (Figure 1). Sensors are used to adjust the pumping cycles according to the peritoneal and bladder pressures: the cycle is interrupted if the pressure becomes too low in the peritoneal cavity or too high in the bladder.

A consensus statement has recently been published by hepatologists and surgeons experienced in using the alfapump®, which provides practical recommendations regarding patients selection, implantation procedure and post-implantation care <sup>[10]</sup>.

The absolute contraindications for the implantation of the alfapump® device are loculated ascites, untreatable obstructive uropathy, the presence of an active bacterial infection at the time of implantation (spontaneous bacterial peritonitis, urinary infection, or abdominal skin infection in particular), and an expected survival of less than 3 months. Special caution is advised regarding frail patients, and nutritional status should be considered and optimized before implantation <sup>[10]</sup>. Once implanted, the patient must charge the pump battery by transcutaneous induction, twice a day for about 20 minutes, using a user-friendly charging device (Smart Charger) that is placed over the area of the pump. While charging, the charger also collects data from the pump, which are then transmitted anonymously to a central databank of Sequana Medical. The data are transferred to the treating physician by e-mail on a weekly basis and in the event of acute dysfunction. This makes it possible not only to provide an early warning in case of pump dysfunction, but also to adjust the operating time, the frequency of cycles, the daily volume of ascites to be evacuated, and to check the correct charging of the device <sup>[9]</sup>.

#### Implantation procedure, use and follow-up of the alfapump®

Consistent data are available in the literature and detailed procedures have been published in expert consensus statements <sup>[10]</sup> and in the article by Dembinsky et al <sup>[11]</sup>. The manufacturer provides technical instructions regarding the surgical procedure and advice regarding pre- and post-implantation care, that are consistent with expert

recommendations. In accordance with these recommendations [10,11], the patient is hospitalized 24-48 hours before implantation. Paracentesis is performed to ensure that there is no ongoing spontaneous bacterial peritonitis, and to drain the abdomen. It is mandatory to leave 1–2 liters of ascites prior to implantation in order to check that the pump is functioning adequately before surgical closure and to minimize the risk of ascitic fluid leakage. Intravenous antibiotic prophylaxis is started on the day of the implantation and continued for 48 to 72 hours. Prior to the procedure, the daily volume, operating time and frequency of the pumping cycles are determined and programmed (FlowControl™ software) by the clinician according to the volume and frequency of paracentesis required in the weeks prior to implantation. A target should be set that is 20% higher than the pre-implant rate, because a post-operative increase in ascites production is frequent. The alfapump® works in cycles of very small volumes (5–10 ml) that are pumped every 5–10 min into the bladder, enabling the removal of 500 mL to 4 L of ascites per day. Some inactive periods can be determined for the patient's comfort (for example to avoid nocturnal urination [9]). A detailed description of the surgical procedure has been published elsewhere [9,10,11]. Briefly, it consists in the following steps: 1) skin incision, 2) bladder catheter insertion, 3) peritoneal catheter placement, 4) pump pocket creation and catheter tunnelling, 5) catheter attachment to the pump, 6) closure of the surgical incisions [11].

As with any new surgical technology, there is an unavoidable learning curve before achieving an acceptable level of success. In Europe, implantation is usually performed surgically under general anesthesia and takes an average of sixty minutes [9]. In the United States and Canada, a less invasive method for implantation has been developed, using an interventional radiology technique. In the recently published North American multicenter MOSAIC study, most procedures (29 out of 30) were performed by interventional radiology, and 11 patients were implanted under conscious sedation or local anesthetic [12,13]. Briefly, the peritoneal catheter was inserted under ultrasound guidance into the right lower quadrant, and excess ascites was removed to prevent leakage and catheter migration. The bladder catheter was inserted above the pubis symphysis and correct placement was confirmed by

aspiration of urine or dyed saline or contrast-enhanced fluoroscopy. A subcutaneous pocket was then created by an incision 5 cm in length at the midclavicular line, 5-6 cm below the costal border, mostly on the right quadrant (76% of patients). Both catheters were then tunneled to the pump pocket, connected to the pump, and fixed in place with sutures; the alfapump® was finally housed in the pocket before multilayer closure [13]. In this study, technical success was obtained in all patients. The median duration of hospitalization was 4 days (range: 2-69 days). After a 3-month follow-up period, three serious adverse events were classified as “procedure-related” (one bleeding at the site of bladder catheter insertion, one fluid leakage at the implant site of the pump, and one bacterial peritonitis 26 days after implantation). At 3 months, two pumps had been explanted for infectious complications (cellulitis and pump pocket infection). Four re-interventions were performed, mostly because of peritoneal catheter dysfunction (three cases). This minimally invasive approach remains infrequent in European centers but a series of three cases reported by a team from Birmingham provided encouraging results [14]. Whatever the method used for implantation, a Sequana Medical implant specialist must be present during the procedure, to check that the pump is working properly, and in the event of a dysfunction, to have a back-up alfapump® available. During the hospitalization, which lasts approximately 4 to 7 days in the absence of complications, the patient must receive appropriate therapeutic education and training in the use of the pump. In particular, the patient must be able to alert the physician immediately if symptoms occur, such as suture loosening, an inflammatory aspect at the surgical site, abdominal pain, reconstitution of abundant ascites, fever, or urinary symptoms. Notably, the presence of the alfapump® contraindicates the subsequent use of magnetic resonance imaging (risk of displacement of the pump and catheters, and damage to the system). Explantation of the pump may be necessary in some cases (death, LT, local complication or pump dysfunction); this decision must be made on a case-by-case basis and in a multidisciplinary manner. The median life span of the device is around two years.

## Efficacy and tolerance of the device

### Control of ascites

Most studies evaluating the efficacy of the alfapump® device included relatively small numbers of selected patients, generally not very old, with preserved liver function (Table 1). The international landmark PIONEER study performed in 40 patients showed a significant decrease in the number of monthly paracenteses in the “alfapump®” group compared to the “conventional treatment” group (0.2 vs 3.4;  $p < 0.01$ ) [15]. More recently, a large prospective, multicenter, open-label, randomized, controlled study (RCT) was conducted in five European countries and aimed to evaluate the safety and efficacy of the alfapump® system in cirrhotic patients with RA in comparison with LVP [16]. This study included 60 patients (29 in the “alfapump®” group and 31 in the “SoC” (standard of care) group). Time to first LVP (the primary endpoint) was significantly longer in the “alfapump®” group compared with “SoC” (HR: 0.13,  $p < 0.001$ ). A total of 10/29 patients (37%) required LVP after pump implantation, mostly due to insufficient pumped volumes (4 patients) or device issues (5 patients). A recent meta-analysis of nine studies, including the European RCT [16] and 8 observational studies [12,14,15,17-21], evaluated the efficacy of the alfapump® in a total of 196 patients [22]. Despite significant heterogeneity between the studies (some of which were retrospective [17,21]), the proportion of patients receiving an alfapump® who no longer required paracentesis after pump implantation was 62%. This significant reduction in the need for paracentesis after pump implantation persisted over time (average follow-up time ranging from 6 to 24 months) [22]. Interestingly, the reduced use of paracentesis is accompanied by an early and prolonged improvement in nutritional status [12,16]. In the study by Bureau et al, there was a significant improvement in brachial circumference, tricipital skinfold thickness and hand grip strength in the first three months after alfapump® placement compared to the control group [16].

The effect of the alfapump® on quality of life was specifically studied in the RCT by Bureau et al [16] and in the MOSAIC study [12,23], and it was shown that quality of life,

assessed by the Chronic Liver Disease Questionnaire, was significantly improved in patients with “alfapump” compared to patients who underwent iterative paracentesis, in particular due to a reduction in ascites-related symptoms [12,16,23]. This benefit may be of interest in patients not eligible for LT.

#### Survival data

It is noteworthy that no prognostic impact of alfapump® has been demonstrated so far. In the European RCT, the overall survival at six months was not different in the “alfapump®” group compared to the “iterative paracentesis” group (77% vs 87%,  $p=0.35$ ) [16]. In the series reported by Stirnimann et al [18], the median TFS of patients with alfapump® was only 9.8 months, and the TFS rate was only 40% at 12 months. The better TFS rate at 12 months (57%) observed in the North American series could be explained, at least partially, by the lower severity of patients at inclusion. More insights should be provided by a European clinical trial that is currently recruiting (NCT04326946), in which the primary endpoint is 6-month post-implant survival.

A retrospective, single-centre, observational study compared the outcome of patients with RA treated with TIPS ( $n=19$ ) versus alfapump® ( $n=40$ ) [24]. As expected, patients receiving alfapump® had more impaired liver function (MELD-Na 16 vs 12;  $p=0.04$ ) and more frequently had encephalopathy (47% vs 16%;  $p=0.02$ ). Within the 6 months following the procedure, the proportion of patients who did not require further paracentesis was 58% in the “TIPS” group vs 43% in the “alfapump®” group ( $p=NS$ ). Two patients (10%) were transplanted in the “TIPS” group during the follow-up, versus 11 (27%) in the “alfapump®” group. In the subgroup of patients with a MELD-Na score below 15, 12-month TFS was significantly higher in the “TIPS” group (65% vs 23% in the “alfapump®” group,  $p=0.02$ ), but the retrospective design of this study makes the results questionable. Two hypotheses can be proposed to explain the high mortality rate in patients from the “alfapump®” group who did not undergo LT. The first and major explanation is that, although alfapump® is an effective treatment to control ascites, it does not protect the patient against the other complications of persistent portal hypertension. The second hypothesis is related to



the specific complications of the device, which are not rare (Tables 2, 3) and may impact on prognosis *per se* or indirectly, if explantation of the pump is required.

### Safety profile

Assessing the safety of the device remains challenging since most of the reported series do not include a control group. The heterogeneity of inclusion and non-inclusion criteria across studies (Table 1) hinders the interpretation of the results.

### Device-related complications

Complications directly related to the device are frequent. Among 100 patients with available data, Lepida et al reported a pooled estimate rate of overall pump-related adverse events of 0.77 (95%CI: 0.64-0.87) with low heterogeneity [22]. Some of these events may require re-intervention, or even pump removal, which is not an uncommon event during follow-up (Table 2). We note, amongst others, the following events: dysfunction of the peritoneal catheter due to blockage (debris, fibrin clots or peritoneal aspiration) or displacement, more rarely dysfunction of the bladder catheter (occlusion, disconnection), migration or dysfunction of the pump, and infection of the pump pocket (Figure 3).

### Concerns regarding renal function

Among the frequently reported adverse events of the pump, acute kidney injury (AKI) may occur in up to 30% of patients during follow-up [22]. However, the heterogeneous definitions used for AKI and the widely varying timeframe between pump implantation and assessment of renal function must be taken into consideration in the interpretation of this finding. It should be noted that the existence of chronic renal failure (based on serum creatinine values > 133 to 176  $\mu\text{mol/L}$  or glomerular filtration rate < 30 to 50 mL/min depending on the series) was an ineligibility criterion for alfapump® in most studies (Table 1). An association between alfapump® and renal function deterioration at 6 months was suggested in a series of 10 patients followed for one year [19], but these results were not confirmed in the MOSAIC cohort [12]. In the European RCT, almost half of the patients experienced



AKI, which was observed during the first week after implantation in 41% of them, but 75% of patients recovered their previous renal function [16]. In the meta-analysis, the mean increase in serum creatinine after implantation was 23  $\mu\text{mol/L}$  (95% CI: 10-35) [22]. Several distinct and interrelated mechanisms may contribute to the deterioration of renal function in the postoperative period, such as changes in intra-abdominal pressure, systemic inflammation and hemodynamic changes. In the medium term, it has been suggested that the continuous removal of ascites could cause circulatory dysfunction [19], thus favoring a deterioration of renal function. However, data regarding the impact of alfapump® implantation on the hemodynamic parameters are limited and conflicting [12,16,19] and this hypothesis has not been confirmed so far [25]. The issue of long-term albumin administration to prevent post-paracentesis circulatory dysfunction in these patients is not clear-cut, due to a lack of published data, and is therefore left at the discretion of the clinician in charge of the patient [26]. The ANSWER study provides some evidence that the benefits of long-term albumin administration in decompensated cirrhosis could be due to improved circulatory function and reduced proinflammatory cytokines [27]. However, the dosage, duration and frequency of administration remain open to debate. Consequently, expert recommendations [10] advise following current guidelines regarding the use of albumin infusion after implantation, i.e. whenever AKI occurs [2,8]; experts also considered albumin infusion whenever total daily volume of ascites removed exceeds 1 liter [10].

### Bacterial infections

The second common adverse effect of pump implantation is the occurrence of bacterial infection. In the meta-analysis by Lepida et al, the incidence rates of ascites fluid infection and urinary tract infection were 27% and 20%, respectively [22]. In the North American study, 15 bacterial infections occurred in 13 patients during the 12-month follow-up, of whom 12 were considered to be related to the alfapump® [12]. Again, the absence of a control group limits the interpretation of these data. In the European RCT, the incidence of infectious events was similar in both the “alfapump®” and “standard treatment” groups [16]. Although the risk of developing

multidrug-resistant infections related to long-term antibiotic prophylaxis remains a concern [7], patients receiving alfapump® have a particularly high risk of infection, and consequently long-term antibiotic prophylaxis should be maintained unless the patient's condition improves significantly (which occurs rarely). Norfloxacin 400 mg/day remains the antibiotic of choice but, in the future, other molecules (such as rifaximin) with lower bacterial resistance and a better safety profile may be an alternative approach for long-term antibiotic prophylaxis [28]. Whatever the choice of antibiotic used for long-term prophylaxis, regular screening for multidrug-resistant organisms in these cirrhotic patients should be considered during antibiotic prophylaxis, in order to re-evaluate this strategy whenever multidrug-resistant gram-negative bacteria or quinolone-resistant gram-negative bacteria emerge [29]. However, two recent studies have provided more optimistic results regarding the long-term use of quinolones. The first observed that the incidence of infections caused by multidrug-resistant bacteria did not differ between the norfloxacin and placebo groups in patients with decompensated cirrhosis [30], while in the Global Study, no association was found between quinolone prophylaxis and multidrug-resistant bacterial infections, even when analysis was performed within different geographical areas [31].

### **Unresolved issues and Perspectives**

According to data on the efficacy and safety of the alfapump® device, it appears that the selection of candidates for insertion of an alfapump® as well as their pre-therapeutic evaluation must be rigorous (Figure 4). Multidisciplinary evaluation involving surgeons, anesthetists and hepatologists is recommended. In fact, relative contraindications are frequent in these frail patients with RA (for example pre-existing kidney injury, severe malnutrition or sarcopenia, cognitive impairment due to hepatic encephalopathy, significant peripheral oedema, bed confinement [10]) and the risk-benefit ratio should be carefully considered. When LT is not possible, alfapump® implantation may be a satisfactory solution to improve the patient's quality of life, provided there are no severe comorbidities that could threaten the

short-term prognosis or compromise the success of the implantation procedure and/or the use of the device.

#### Patients awaiting a liver transplant

In patients who are candidates for LT, but with a long estimated waiting time until transplantation, (notably when there is no possibility of prioritizing LT), alfapump® implantation may be discussed whenever TIPS is contraindicated. Few reports are available about the use of alfapump® in patients awaiting LT. A recent single-centre retrospective study among 22 patients listed for LT in Switzerland aimed to demonstrate the feasibility of LT in patients with an alfapump® [32]. In this cohort, the median (range) MELD score at alfapump® implantation was 15 (8-25), and only 14/22 patients underwent LT within an average of 6 months after the pump implantation. The pump was removed before LT and at the end of the LT procedure in 3 and 8 patients respectively, and left in place in 3 patients for a limited period of time. No technical issues were attributed to the alfapump® during the LT procedure. The authors reported that 8 patients died before LT, 7 while on the waiting list and one after being delisted due to progressive liver disease. The causes of death among the patients on the waiting list were progressive liver disease in 4 (of whom one had a bacterial infection of unknown focus and another suffered from peritonitis), and multi-organ failure in 3 patients (who respectively developed pump pocket empyema, an abdominal wall phlegmon with communication into the abdominal cavity, and septic shock associated with probable infected abdominal focus). A last patient died after small bowel perforation not directly related to the pump catheter. The lack of a control group of patients listed for LT with RA and treated by iterative LVP, precludes any firm conclusions. However, while these results suggest that alfapump® does not technically compromise LT, they also emphasize the high risk of severe infection in these patients carrying intra-abdominal foreign material.

#### Unproven benefits

The alfapump® offers interesting perspectives that warrant further evaluation.

a. Frailty

Frailty is recognized as a determining factor in the overall prognosis of cirrhotic patients and contributes to mortality on the LT waiting list [33,34]. By enabling an improvement in nutritional status and a return to physical activity, **we may speculate that the alfapump® device could limit sarcopenia and frailty, but data regarding this potential benefit are scarce and this point warrants specific evaluation in dedicated studies.**

b. Percutaneous treatment of hepatocellular carcinoma

By reducing the quantity of ascites, alfapump® renders the percutaneous treatment of hepatocellular carcinoma possible. To date, this was reported in only one case-report [35], but this therapeutic approach warrants further study.

c. Cure of hernia

A retrospective study of European multicenter data recently showed that patients who had concomitant umbilical or inguinal hernia repair and alfapump® placement had a shorter hospital stay, fewer complications, and better survival without paracentesis than patients undergoing emergency hernia surgery [36]. Hernia surgery concomitant with the implantation of the alfapump® enables the patient to undergo programmed surgery and to avoid the usual postoperative drainage, since the pump performs the ascites control. However, these data must be confirmed prospectively before this “concomitant” approach can be recommended. In the current state of knowledge, experts discourage concomitant repair of hernias [10].

d. Prevention of multidrug-resistant bacterial infections

Due to the decrease in hospitalizations for paracentesis, patients with alfapump® may be less exposed to nosocomial bacterial infections, which mainly involve multi-drug resistant bacteria. This may be of interest for patients who are candidates for LT. However, this potential benefit has not yet been evaluated in the long-term, and must be balanced against the risk of infections related to the procedure.

## Cost-effectiveness

The overall cost of the procedure (implantation and patient follow-up), compared with that of standard treatment (iterative paracentesis), is a crucial point for the routine use of the alfapump®. This cost in the first six months after implantation is higher than the standard of care treatment, mainly due to the cost of the device and the surgical intervention (about 30,000 Euros), but tends to stabilize thereafter [16]. The ongoing French multicenter randomized medico-economic study (ARIAPUMP protocol, NCT03506893) comparing two management approaches for RA, namely alfapump® implantation and iterative paracentesis, will make it possible to compare the costs of the long-term care for both these strategies, taking into account whether or not there is programmed LT. The radiological approach offers interesting perspectives in reducing the peri-operative risk of morbidity in frail patients. Whether this mini-invasive technique can significantly reduce the duration of the post-procedure hospital stay, or the rate of local complications, has not yet been demonstrated, due to insufficient data and a lack of head-to-head studies.

## Conclusion

The alfapump® is a device that has proven its effectiveness in reducing the need for iterative paracentesis and in improving the quality of life of cirrhotic patients with refractory ascites. It should be considered in particular for patients contraindicated for a TIPS, regardless of the patient's eligibility for LT. To minimize the risk of complications after implantation, careful selection of these frail patients is essential. The concerns related to the cost of the device, the surgical procedure of implantation, as well as the potential complications that can occur are not fully resolved yet, but the implantation technique could evolve towards a "minimally invasive" approach, with a view to reducing the risks and improving the cost-effectiveness of the implantation. Patient information and active participation of the patient are two prerequisites for successful management. Additional studies, particularly real-world data from large heterogeneous populations with long-term follow-up, are required to clarify some unresolved issues, notably concerning the acceptable limits of liver and kidney function, age, forms of albumin compensation, or cost-effectiveness. There are

currently several ongoing observational studies (NCT04326946, NCT03973866, NCT03506893) that will hopefully provide a more complete picture of the advantages and disadvantages of this innovative device.

## References

1. Ginés P, Quintero E, Arroyo V, Terés J, Bruguera M, Rimola A, Caballería J, Rodés J, Rozman C. Compensated cirrhosis: natural history and prognostic factors. *Hepatology* 1987;7:122-8. [PMID: 3804191 DOI: 10.1002/hep.1840070124]
2. European Association for the Study of the Liver. EASL Clinical Practice Guidelines for the management of patients with decompensated cirrhosis. *J Hepatol* 2018;69:406-460. [PMID: 29653741 DOI: 10.1016/j.jhep.2018.03.024]
3. Moreau R, Delègue P, Pessione F, Hillaire S, Durand F, Lebrech D, Valla DC. Clinical characteristics and outcome of patients with cirrhosis and refractory ascites. *Liver Int* 2004;24:457-64. [PMID: 15482343 DOI: 10.1111/j.1478-3231.2004.0991.x]
4. Angeli P, Garcia-Tsao G, Nadim MK, Parikh CR. News in pathophysiology, definition and classification of hepatorenal syndrome: A step beyond the International Club of Ascites (ICA) consensus document. *J Hepatol* 2019;71:811-822. [PMID: 31302175 DOI: 10.1016/j.jhep.2019.07.002]
5. De Gottardi A, Thévenot T, Spahr L, Morard I, Bresson-Hadni S, Torres F, Giostra E, Hadengue A. Risk of Complications After Abdominal Paracentesis in Cirrhotic Patients: A Prospective Study. *Clin Gastroenterol Hepatol* 2009;7:906-9. [PMID: 19447197 DOI: 10.1016/j.cgh.2009.05.004]
6. Bureau C, Thabut D, Oberti F, Dharancy S, Carbonell N, Bouvier A, Mathurin P, Otal P, Cabarro P, Péron JM, Vinel JP. Transjugular Intrahepatic Portosystemic Shunts With Covered Stents Increase Transplant-Free Survival of Patients With Cirrhosis and Recurrent Ascites. *Gastroenterology* 2017;152:157-63. [PMID:27663604 DOI: 10.1053/j.gastro.2016.09.016]
7. Piano S, Tonon M, Angeli P. Management of ascites and hepatorenal syndrome. *Hepatol Int* 2018;12:122-34. [PMID: 28836115 DOI: 10.1007/s12072-017-9815-0]

8. Biggins SW, Angeli P, Garcia-Tsao G, Ginès P, Ling SC, Nadim MK, Wong F, Kim WR. Diagnosis, Evaluation, and Management of Ascites, Spontaneous Bacterial Peritonitis and Hepatorenal Syndrome: 2021 Practice Guidance by the American Association for the Study of Liver Diseases. *Hepatology*. 2021;74:1014-1048.[PMID:33942342 DOI: 10.1002/hep.31884]
9. Stirnimann G, Banz V, Storni F, De Gottardi A. Automated low-flow ascites pump for the treatment of cirrhotic patients with refractory ascites. *Ther Adv Gastroenterol* 2017; 10:283-92. [PMID: 28203285 DOI: 10.1177/1756283X16684688]
10. Aagaard NK, Malago M, De Gottardi A, Thomas M, Sauter G, Engelmann C, Aranovich D, Cohen M, Thévenot T, Ehmann T, Capel J, Angeli P, Jalan R, Stirnimann G. Consensus care recommendations for alfapump® in cirrhotic patients with refractory or recurrent ascites. *BMC Gastroenterol*. 2022;22:111. [PMID: 35260086 DOI: 10.1186/s12876-022-02173-5]
11. Dembinski J, Aranovich D, Banz V, Ehmann T, Klein I, Malago M, Richter N, Schnitzbauer AA, Staszewicz W, Tautenhahn HM, Capel J, Regimbeau JM. Surgical technique for placement of the automated low flow ascites pump (Alfapump). *Langenbecks Arch Surg* 2020;405: 117-23. [PMID: 31915920 DOI: 10.1007/s00423-019-01822-w]
12. Wong F, Bendel E, Sniderman K, Frederick T, Haskal ZJ, Sanyal A, Asrani SK, Capel J, Kamath PS. Improvement in Quality of Life and Decrease in Large-Volume Paracentesis Requirements With the Automated Low-Flow Ascites Pump. *Liver Transpl* 2020;26:651-61. [PMID: 31999044 DOI: 10.1002/lt.25724]
13. Bendel EC, Sniderman K, Shaw C, Frederick RT, Wong F, Sanyal A, Asrani SK, Kamath PS, Capel J, Haskal ZJ. Feasibility and Procedural Safety of alfapump System Implantation by IR: Experience from the MOSAIC Study, a Multicenter, Open-Label Prospective Study in Cirrhotic Patients with



Refractory Ascites. J Vasc Interv Radiol. 2020;31:1256-1262.[PMID: 32654961 DOI: 10.1016/j.jvir.2020.02.005]

14. Karkhanis S, Jones R, Willis A, McCarthy E , Zia Z, Mehrzad H , O'rourke J , Holt A, Tripathi D. Radiological insertion of automated low flow ascitic pump (alfapump®) system for management of medically refractory ascites. BJR Case Rep 2017;3:20170025.[ PMID: 30363221 DOI: 10.1259/bjrcr.20170025]
15. Bellot P, Welker M-W, Soriano G, von Schaewen M, Appenrodt B, Wiest R, Whittaker S, Tzonev R, Handshiev S, Verslype C, Moench C, Zeuzem S, Sauerbruch T, Guarner C, Schott E, Johnson N, Petrov A, Katzarov K, Nevens F, Zapater P, Such J. Automated low flow pump system for the treatment of refractory ascites: a multi-center safety and efficacy study. J Hepatol 2013;58:922-7. [PMID: 23318604 DOI: 10.1016/j.jhep.2012.12.020]
16. Bureau C, Adebayo D, Chalret de Rieu M, Elkrief L, Valla D, Peck-Radosavljevic M, McCune A, Vargas V, Simon-Talero M, Cordoba J, Angeli P, Rosi S, MacDonald S, Malago M, Stepanova M, Younossi ZM, Trepte C, Watson R, Borisenko O, Sun S, Inhaber N, Jalan R. Alfapump® system vs. large volume paracentesis for refractory ascites: A multicenter randomized controlled study. J Hepatol 2017;67:940-9.[PMID: 28645737 DOI: 10.1016/j.jhep.2017.06.010]
17. Solbach P, Höner Zu Siederdisen C, Wellhöner F, Richter N, Heidrich B, Lenzen H, Kerstin P, Hueper K, Manns MP, Wedemeyer H, Jaeckel E. Automated low-flow ascites pump in a real-world setting: complications and outcomes. Eur J Gastroenterol Hepatol 2018;30:1082-9. [PMID: 29738325 DOI: 10.1097/MEG.0000000000001149].
18. Stirnimann G, Berg T, Spahr L, Zeuzem S, McPherson S, Lammert F, Storni F, Banz V, Babatz J, Vargas V, Geier A, Stallmach A, Engelmann C, Trepte C, Capel J, De Gottardi A. Treatment of refractory ascites with an automated

low-flow ascites pump in patients with cirrhosis. *Aliment Pharmacol Ther* 2017;46 :981-91. [PMID: 28940225 DOI: 10.1111/apt.14331]

19. Solà E, Sanchez-Cabús S, Rodriguez E, Elia C, Cela R, Moreira R, Pose E, Sánchez-Delgado J, Cañete N, Morales-Ruiz M, Campos F, Balust J, Guevara M, García-Valdecasas JC, Ginès P. Effects of alfapump™ system on kidney and circulatory function in patients with cirrhosis and refractory ascites. *Liver Transplant* 2017;23:583-93. [PMID: 28318147 DOI: 10.1002/lt.24763]
20. Thomas MN, Sauter GH, Gerbes AL, Stangl M, Schiergens TS, Angele M, Werner J, Guba M. Automated low flow pump system for the treatment of refractory ascites: a single-center experience. *Langenbecks Arch Surg* 2015;400:979-83. [PMID: 26566989 DOI: 10.1007/s00423-015-1356-1]
21. Nair S, Robinson E, Fiona S, Macdonald S, Mergental H, Talbot D, Tripathi D, Griffiths B, Jalan R, McPherson S. PWE-141 Alfapump for the treatment of refractory ascites: a “real world” experience from the uk. *Gut* 2015;64:A274-5.
22. Lepida A, Marot A, Trépo E, Degré D, Moreno C, Deltenre P. Systematic review with meta-analysis: automated low-flow ascites pump therapy for refractory ascites. *Aliment Pharmacol Ther* 2019; 50:978-87. [PMID: 31583729 DOI: 10.1111/apt.15502]
23. Stepanova M, Nader F, Bureau C, Adebayo D, Elkrief L, Valla D, Peck-Radosavljevic M, McCune A, Vargas V, Simon-Talero M, Cordoba J, Angeli P, Rossi S, MacDonald S, Capel J, Jalan R, Younossi ZM. Patients with refractory ascites treated with alfapump® system have better health-related quality of life as compared to those treated with large volume paracentesis: the results of a multicenter randomized controlled study. *Qual Life Res* 2018; 27: 1513-20.[PMID: 29460201 DOI: 10.1007/s11136-018-1813-8]
24. Will V, Rodrigues SG, Stirnimann G, Gottardi A, Bosch J, Berzigotti A. Transjugular intrahepatic portosystemic shunt and alfapump® system for

refractory ascites in liver cirrhosis: Outcomes and complications. *United Eur Gastroenterol J* 2020;8:961-9. [PMID: 32588789 DOI: 10.1177/2050640620938525]

25. Kumar K, Pillai VB. Improvement in Quality of Life and Decrease in Large-Volume Paracentesis Requirements With the Automated Low-Flow Ascites Pump. *Liver Transplant* 2020;26 :1539-40. [PMID: 32578929 DOI: 10.1002/lt.25827]
26. Adebayo D, Neong SF, Wong F. Refractory Ascites in Liver Cirrhosis. *Am J Gastroenterol* 2019;114 : 40-7. [PMID: 29973706 DOI: 10.1038/s41395-018-0185-6]
27. Caraceni P, Riggio O, Angeli P, Alessandria C, Neri S, Foschi FG, Levantesi F, Airoldi A, Boccia S, Svegliati-Baroni G, Fagiuoli S, Romanelli RG, Cozzolongo R, Di Marco V, Sangiovanni V, Morisco F, Toniutto P, Tortora A, De Marco R, Angelico M, Cacciola I, Elia G, Federico A, Massironi S, Guarisco R, Galioto A, Ballardini G, Rendina M, Nardelli S, Piano S, Elia C, Prestianni L, Cappa FM, Cesarini L, Simone L, Pasquale C, Cavallin M, Andrealli A, Fidone F, Ruggeri M, Roncadori A, Baldassarre M, Tufoni M, Zaccherini G, Bernardi M; ANSWER Study Investigators. Long-term albumin administration in decompensated cirrhosis (ANSWER): an open-label randomised trial. *Lancet* 2018;391:2417-2429.[PMID: 29861076 DOI: 10.1016/S0140-6736(18)30840-7]
28. Shamsaddini A, Gillevet PM, Acharya C, Fagan A, Gavis E, Sikaroodi M, McGeorge S, Khoruts A, Albhaisi S, Fuchs M, Sterling RK, Bajaj JS. Impact of Antibiotic Resistance Genes in Gut Microbiome of Patients With Cirrhosis. *Gastroenterology* 2021;161:508-21.e7. [PMID: 33857456 DOI: 10.1053/j.gastro.2021.04.013]
29. Mücke MM, Mayer A, Kessel J, Mücke VT, Bon D, Schwarzkopf K, Rüschbaum S, Queck A, Göttig S, Vermehren A, Weiler N, Welker MW, Reinheimer C, Hogardt M, Vermehren J, Herrmann E, Kempf VAJ, Zeuzem S, Lange CM. Quinolone and Multidrug Resistance Predicts Failure of Antibiotic

Prophylaxis of Spontaneous Bacterial Peritonitis. Clin Infect Dis. 2020;70:1916-1924.[PMID: 31228250 DOI: 10.1093/cid/ciz540]

30. Moreau R, Elkrief L, Bureau C, Perarnau JM, Thévenot T, Saliba F, Louvet A, Nahon P, Lannes A, Anty R, Hillaire S, Pasquet B, Ozenne V, Rudler M, Ollivier-Hourmand I, Robic MA, d'Alteroche L, Di Martino V, Ripault MP, Pauwels A, Grangé JD, Carbonell N, Bronowicki JP, Payancé A, Rautou PE, Valla D, Gault N, Lebrech D; NORFLOCIR Trial Investigators. Effects of Long-term Norfloxacin Therapy in Patients With Advanced Cirrhosis. Gastroenterology. 2018;155:1816-1827.e9 [PMID: 30144431 DOI: 10.1053/j.gastro.2018.08.026]
31. Piano S, Singh V, Caraceni P, Maiwall R, Alessandria C, Fernandez J, Soares EC, Kim DJ, Kim SE, Marino M, Vorobioff J, Barea RCR, Merli M, Elkrief L, Vargas V, Krag A, Singh SP, Lesmana LA, Toledo C, Marciano S, Verhelst X, Wong F, Intagliata N, Rabinowich L, Colombato L, Kim SG, Gerbes A, Durand F, Roblero JP, Bhamidimarri KR, Boyer TD, Maevskaya M, Fassio E, Kim HS, Hwang JS, Gines P, Gadano A, Sarin SK, Angeli P; International Club of Ascites Global Study Group. Epidemiology and Effects of Bacterial Infections in Patients With Cirrhosis Worldwide. Gastroenterology. 2019;156:1368-1380.e10 [PMID: 30552895 DOI: 10.1053/j.gastro.2018.12.005]
32. Storni F, Stirnimann J, Banz V, De Gottardi A, Stirnimann G. Treatment of refractory ascites with an automated low flow ascites pump in patients awaiting liver transplantation. Journal of Liver Transplantation 2021;4:100037
33. Lai JC, Rahimi RS, Verna EC, Kappus MR, Dunn MA, McAdams-DeMarco M, Haugen CE, Volk ML, Duarte-Rojo A, Ganger DR, O'Leary JG, Dodge JL, Ladner D, Segev DL. Frailty Associated With Waitlist Mortality Independent of Ascites and Hepatic Encephalopathy in a Multicenter Study. Gastroenterology 2019;156:1675-82. [PMID: 30668935 DOI: 10.1053/j.gastro.2019.01.028]

34. Duarte-Rojo A, Ruiz-Margáin A, Montaña-Loza AJ, Macías-Rodríguez RU, Ferrando A, Kim WR. Exercise and physical activity for patients with end-stage liver disease: Improving functional status and sarcopenia while on the transplant waiting list. *Liver Transplant* 2018;24:122-39. [PMID: 29024353 DOI: 10.1002/lt.24958]
35. Weil D, Christmann PY, Sailley N, Thévenot T. Letter: innovative use of the alfapump system to treat a small hepatocellular carcinoma. *Aliment Pharmacol Ther* 2018;47:695-6. [PMID: 29417624 DOI: 10.1111/apt.14440]
36. Nguyen-Khac E, Sarba R, Spahr L, Staszewicz W, DeGottardi A, Storni F, Elkrief L, Dokmak S, Valla D, Pricope D, Sabbagh C, Regimbeau JM. Combined treatment of refractory ascites with an alfapump® plus hernia repair in the same surgical session: A retrospective, multicentre, European pilot study in cirrhotic patients. *J Visc Surg* 2021;158:27-37. [PMID: 32553558 DOI: 10.1016/j.jviscsurg.2020.06.003]

## Figure legends

### **Figure 1. Alfapump® device and principles of its implantation**

A: The system consists of 1) the pump, which contains a rechargeable battery and is connected to a peritoneal catheter and a bladder catheter, and 2) the charging accessories. The charger collects information and charges the pump through transduction; the docking station must be connected to the electrical network. B: The pump is positioned subcutaneously, under the costal margin (preferably on the right side), so that the patient is not hindered when sitting. The bladder must be full at the time of insertion of the bladder catheter; conversely, only a small amount of ascites is left in place for insertion of the peritoneal catheter, so that the pump can be tested before parietal closure. Images courtesy of Sequana medical.

### **Figure 2. Example of pump activity during the first 6 months after implantation of the alfapump**

Patient with refractory ascites, implanted with an alfapump®. The figure shows a progressive increase in the average daily volume of ascites evacuated (brown curve), resulting from adjustment of the pump by the clinician. The definitive rate is reached between the 1st and 2nd month. The bars (in blue) represent the total cumulative volume of ascites evacuated. (Personal communication, Prof. Eric Nguyen-Khac, CHU Amiens, France).

### **Figure 3. Example of an alfapump complication**

The alfapump® was implanted in July 2018, followed by omphalectomy in September 2018. A: October 2018: increase in ascites after omphalectomy, leading to modification of the alfapump® settings and enabling subsequent deferral of paracentesis. B: February 2020: the patient was hospitalized for sepsis related to infection of the pump pocket, complicated with peritonitis and requiring pump explantation. (Personal communication, Dr D. Weil-Verhoeven, CHU Besançon).

**Figure 4: Decision-making algorithm and key evaluation criteria for eligibility for alfapump® implantation.**

Abbreviation: MELD, Model for End-stage Liver Disease

**Supplementary Figure 1: Flow diagram of the study selection process.**

Studies were considered “off-topic” for example if they focused on ascites not related to cirrhosis.

**Table 1.** Characteristics and results of the main studies evaluating the alfapump®

Author, year	Study design	Main exclusion criteria	N patient s	Mean age (years)	MELD score §	Follow-up	Efficacy of the device	Mortality during follow-up N patients (%)	Liver transplantation after pump implantation
Bellot et al, 2013	Observational Prospective	Life expectancy < 6 months Creatinine > 176 µmol/L in the 7 days prior to inclusion Bilirubin > 85 µmol/L Malignancy (including HCC) HE and/or GI bleeding related to portal hypertension in the 2 weeks prior to inclusion	40	59	12	6 months	number of paracentesis/month/patient: 3.4 <i>vs</i> 0.24 ; p < 0.01	8 (25%)	5 (12%)
Thomas et al, 2015	Observational Prospective	NA	10	NA	16	median : 165 days (maximum : 379 days)	number of paracentesis/month/patient : 3.4 ± 0.8 <i>vs</i> 0.4 ± 1.0 P < 0.0001	3 (30%)	1 (10%)
Bureau et al, 2017	RCT : alfapump (G1) <i>vs</i> iterative paracentesis (G2)	Creatinine > 176 µmol/L HCC outside Milan criteria Inability to use the device	G1 : 27 G2 : 31	61	12	6 months	median number of paracentesis on day 28 G1 <i>vs</i> G2 : 0.3 <i>vs</i> 1.2 ; p <0.001	G1 <i>vs</i> G2 : 22% <i>vs</i> 13%, p=NS	3 (11%)



Stirnemann et al, 2017	Observational Prospective	Inability to use the device	56	62	13	median : 5.8 months (maximum : 26 months)	number of paracentesis/month/patient : 2.9 ± 1.8 vs 0.3 ± 0.3, p=NA	23 (41%)	9 (16%)
Solà et al, 2017	Observational Prospective	Creatinine > 176 µmol/L Bilirubin > 85 µmol/L ≥2 urinary tract infections or SBP in the 6 months prior to inclusion HCC outside Milan criteria	10	59	11	12 months	number of paracentesis/3 months/patient : 7.5 vs 2.4 ; p=NA	5 (50%)	NA
Solbach et al, 2018	Retrospective	NA	21	56	15	NA	number of paracentesis/week/patient : 2.3 ± 2.7 vs 0 ; p=NA	Median survival : 153 days	4 (19%)
Wong et al, 2020	Observational Prospective	MELD score > 21 HE stage >II in the 15 days prior to inclusion >2 systemic or local infections in the 6 months prior to inclusion Bilirubin > 85 µmol/L Creatinine > 132 µmol/L GFR <30 mL/minute/1.73 m <sup>2</sup>	30 *	60	11	12 months	number of paracentesis/month/patient : 2.4 ± 1.4 vs 0.2 ± 0.4 ; p < 0.05	4 (13.3%)	3 (10%)
Will et al, 2020	Retrospective TIPS vs alfapump	NA	40	59	16	median : 4.7 months (maximum : 24 months)	number of paracentesis : no more paracentesis at 6 months for 43% of patients	24 (60%)	11 (28%)

\*Implant through interventional radiology (N=29) or surgery (N=1)

§ Median values (ref. Bellot *et al.*, Bureau *et al.*, Stirnimann *et al.*) or mean values (ref. Thomas *et al.*, Sola *et al.*, Solbach *et al.*, Wong *et al.*, Will *et al.*) of the MELD score on the day of implantation.† Main exclusion criteria without listing usual absolute contraindications

Abbreviations : GFR, glomerular filtration rate ; GI, gastrointestinal ; HCC, hepatocellular carcinoma ; HE, Hepatic encephalopathy ; MELD, Model for End-stage Liver Disease ; NA, not available; NS, not significant ; RCT : randomized control trial ; SBP, spontaneous bacterial peritonitis ; TIPS, transjugular Intrahepatic Portosystemic Shunt

**Table 2.** General complications after implantation of the alfapump®: acute kidney injury, peritoneal and urinary tract infections.

Author, Year	N patient s	AKI occurrence during follow-up	Variation in creatinine levels before versus after implantation	Peritoneal infections (N episodes)	Urinary tract infections (N episodes)
Bellot et al, 2013	40	13 episodes, 11 patients	106 <i>vs</i> 127 µmol/L at 3 months (p=NA) 105 µmol/L at 6 months (p=NA)	12	3
Thomas et al, 2015	10	3 episodes	168 <i>vs</i> 221 µmol/L at 2 months (p=NS)	NA	NA
*Bureau et al, 2017	27	After day 7: G1 <i>vs</i> G2: 17 <i>vs</i> 11 episodes; p= NS	G1 <i>vs</i> G2, at 3 months: Increase of 18.1 <i>vs</i> 8.1 µmol/L (p=NS)	NA	NA
Stirnimann et al, 2017	56	NA	Increase of 46 µmol/L at 3 months (p=NA)	5	1
Solà et al, 2017	10	18 episodes, 14 after day 7 in 7 patients	96 <i>vs</i> 105 µmol/L at 12 months (p=NS)	3	8
Solbach et al, 2018	21	0	140 <i>vs</i> 168 µmol/L at 3 months (p=NS)	11	4
Wong et al, 2020	30	11 episodes after day 7 in 9 patients	93 <i>vs</i> 107 µmol/L at 12 months (p=NA)	1	3

Abbreviations: AKI, acute kidney injury; NA, not available; NS, not significant.

\*In this randomized controlled study, G1 and G2 correspond to « alfapump® » and « iterative paracentesis » groups, respectively.

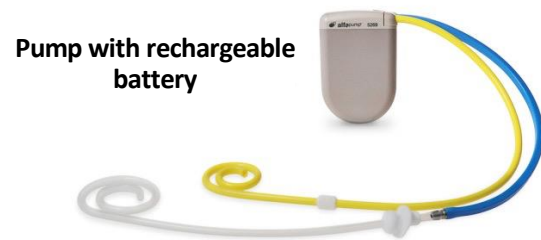**Table 3.** Device-related complications after alfapump® implantation.

Author, Year	N patient s	Peritoneal catheter dysfunction (N patients)	Bladder catheter dysfunction (N patients)	Pump dysfunction (N patients)	Pump pocket complicati on (N patients)	Explanted/replaced pumps
Bellot et al, 2013	40	5	9	2	Infection : 2 Wound: 2	13/NA
Thomas et al, 2015	10	0	Kinking: 1	1	Infection : 1 Wound: 2	1/0
Bureau et al, 2017	27	2	3	12	3	3/4
Stirnimann et al, 2017	56	Blockage: 13 Displacement: 2 Disconnection: 1 Twist: 2	Blockage : 1 Migration : 1	Clogging: 2 Humidity: 2 Communication: 4 Faulty sensor: 3	Infection : 2 Wound: 2	17/11
Solà et al, 2017	10	Migration : 2 Blockage: 1	2	Charging problem: 2 Transient blockage :2	1	2/1
Karkhanis et al, 2017	3	0	Migration : 1	1	2	
Solbach et al, 2018	21	Obstructions : 6	Dislocations : 5	4	4	4/2
Wong et al, 2020	30	13	1	3	4	10/9
Will et al,	40	NA	Obstructions : 9	NA	NA	12/40



**Figure 1**

**A**



**B**

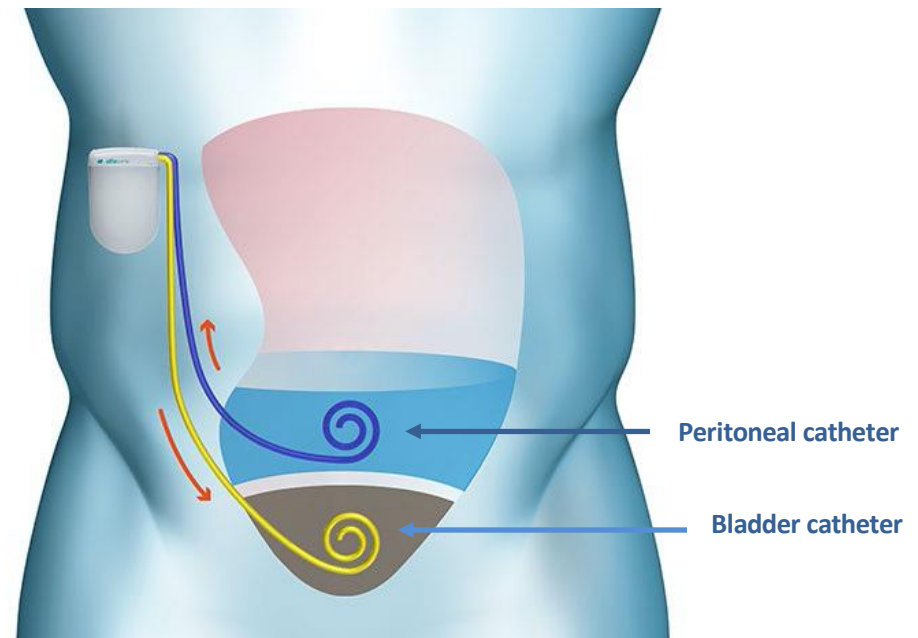
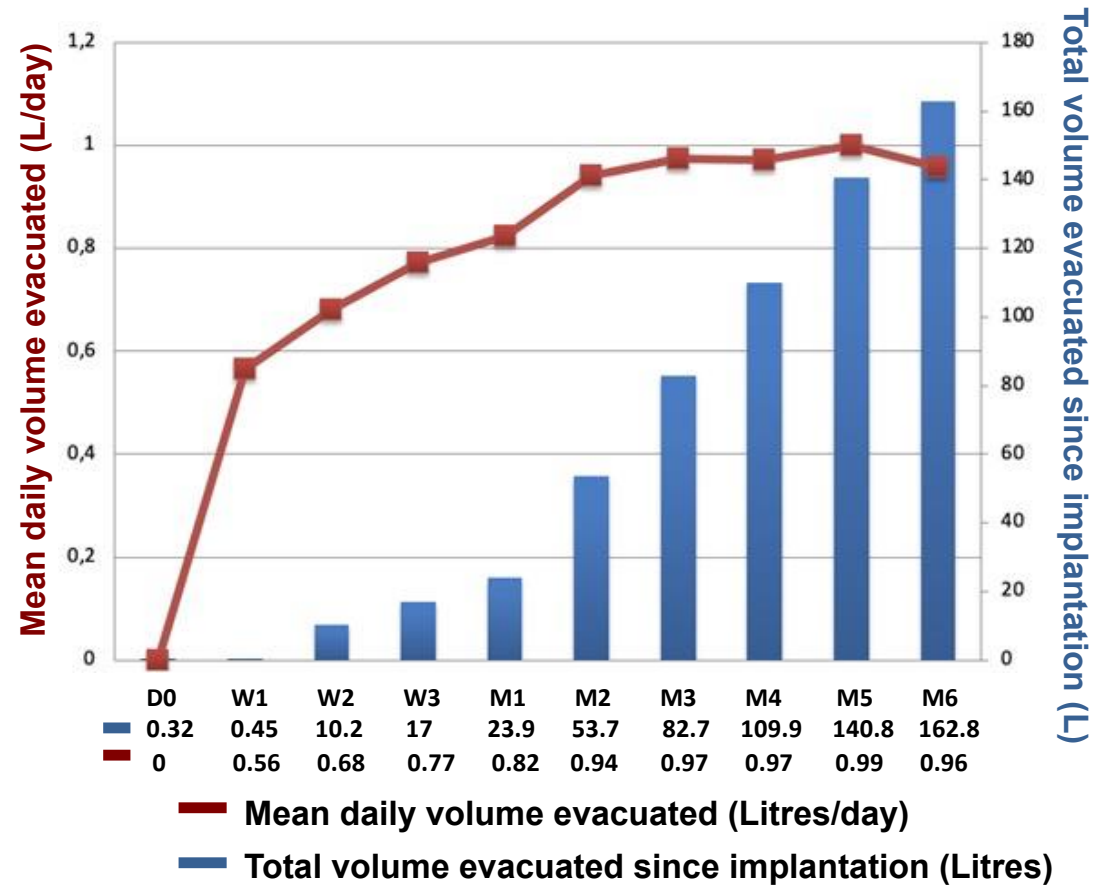
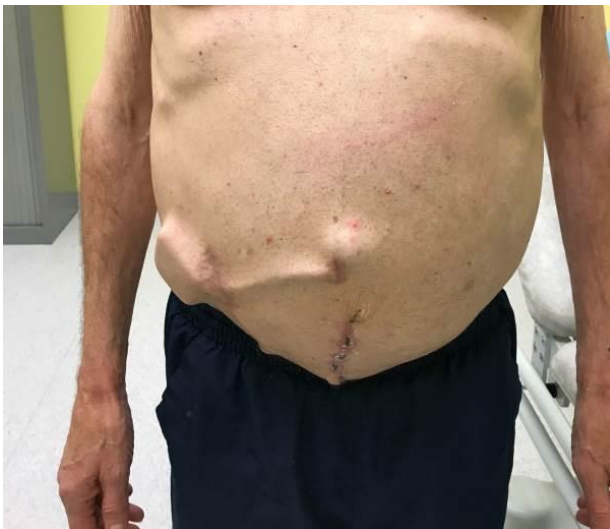
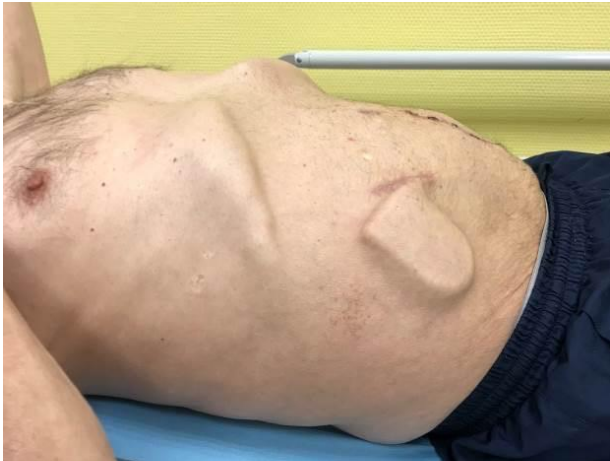
Figure 2



**Figure 3**

**A**

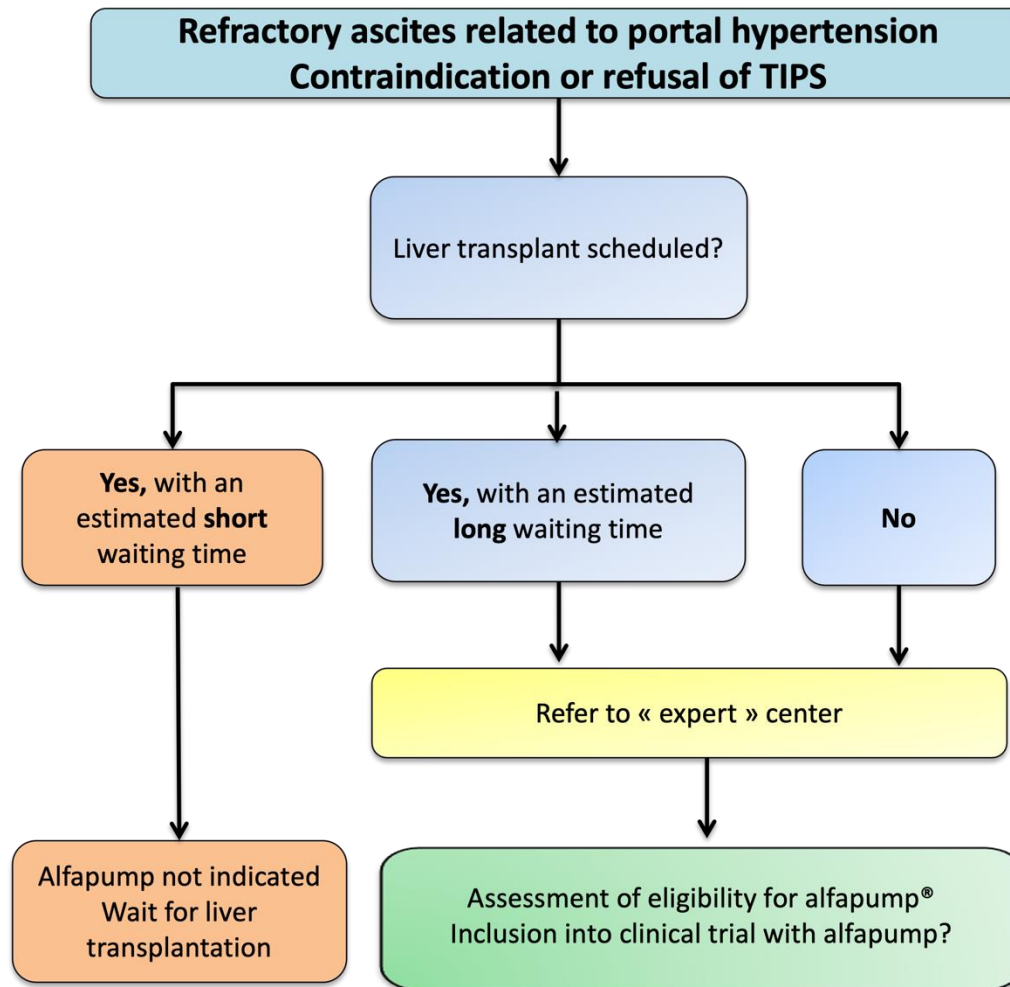


**B**

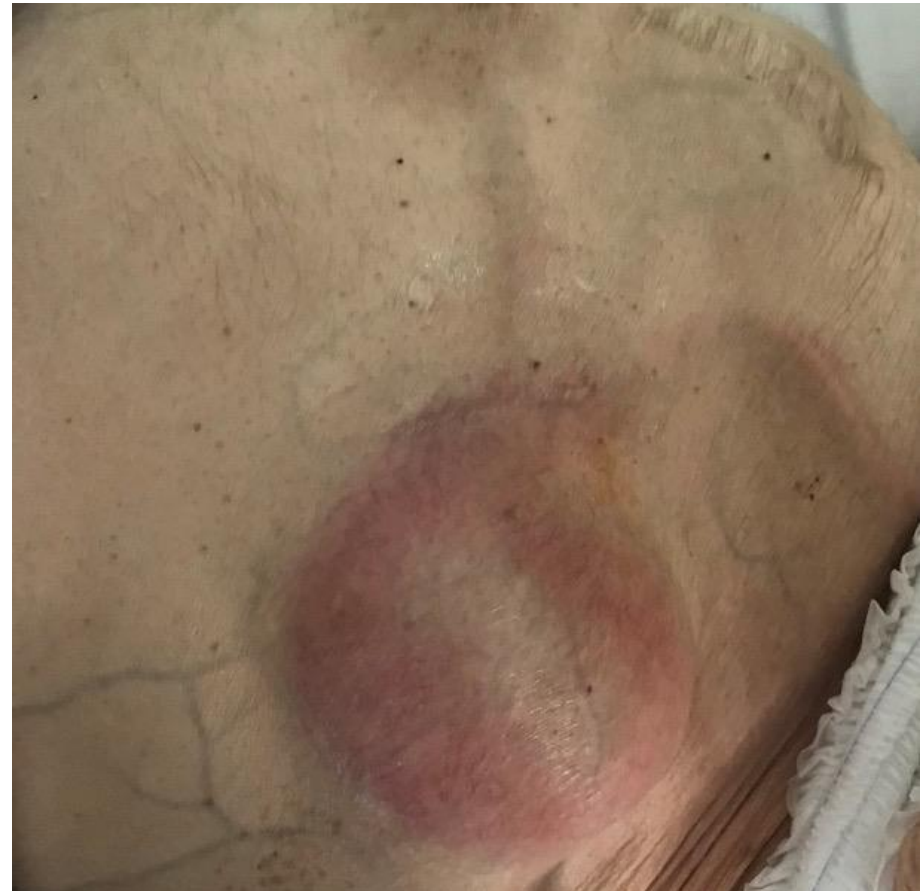



Figure 4



### Contra-indications

#### Anatomical contraindications:

- Loculated ascites
- Untreatable obstructive uropathy

#### Physiological contraindications:

- Severe life threatening comorbidities ( life expectancy < 3-6 months)
- Contraindication to general anesthesia
- Ongoing abdominal/urinary tract infection

#### Collegial discussion on a case-by-case basis, especially if:

- Severe impairment of liver function (MELD > 21)
- Pre-existing chronic renal failure
- Past history of spontaneous bacterial peritonitis or or recurrent urinary tract infections
- Pre-existing cognitive impairment