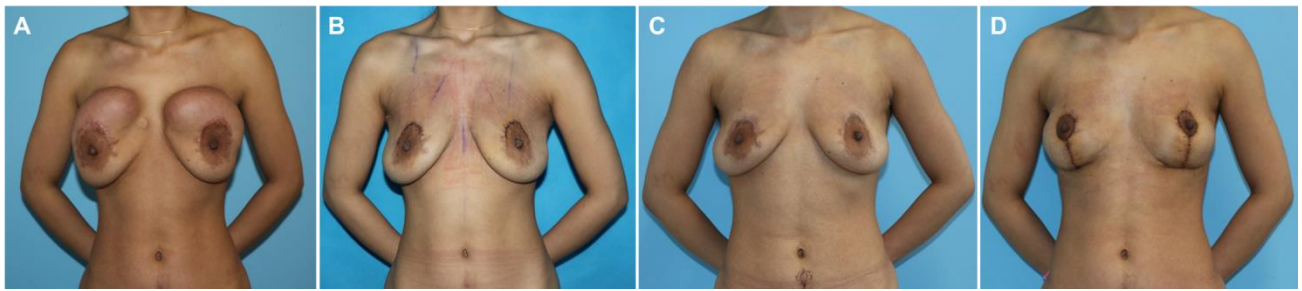
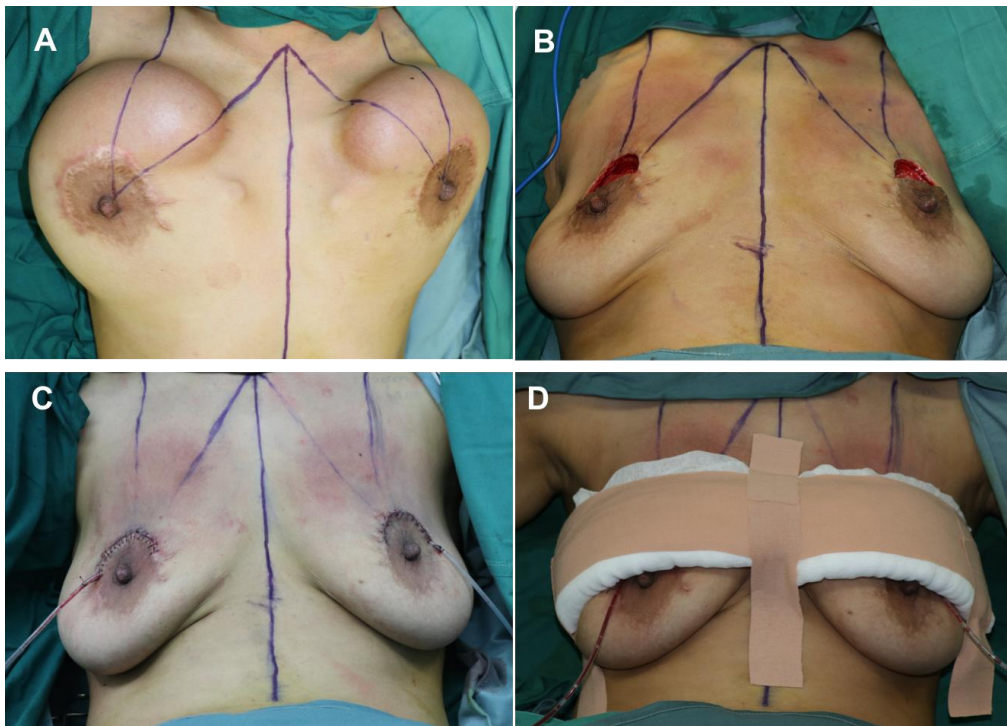


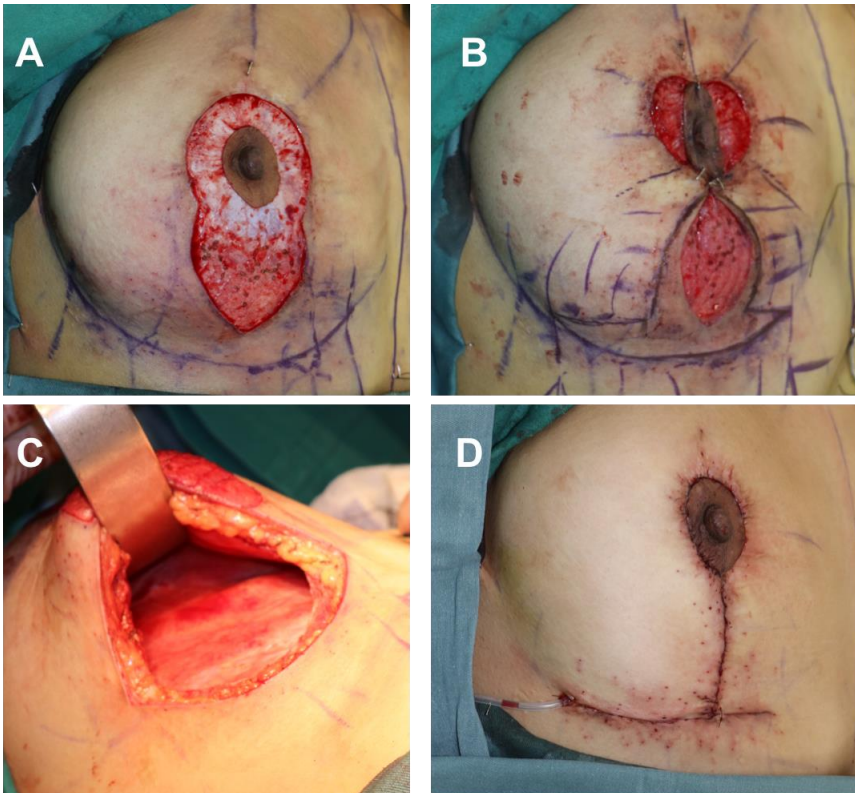
Supplemental materials



Supplemental Figure 1 A: Preoperative of second stage; B: One week after the second stage; C: Three months after the second stage, the skin stopped contraction; D: One week after the final stage.



Supplemental Figure 2 Intraoperative stage of removing tissue expander. Expanders were removed from the old scar incision. Suturing of the pectoral muscle and inferior pedicle to prevent skin retraction. Rib Belts were used to prevent retraction of the expanded skin



Supplemental Figure 3 Intraoperative stages of revision mastopexy. A: Deepithelialization around the NAC; B: Determine the location of NAC; C: The vertical segment is incised through the inframammary fold (IMF) incision skin to the breast parenchyma. The descend tissue was removed; D: Final intraoperative view after closure of the flaps.