

median arcuate ligament release :  
division of the right crus of the diaphragm

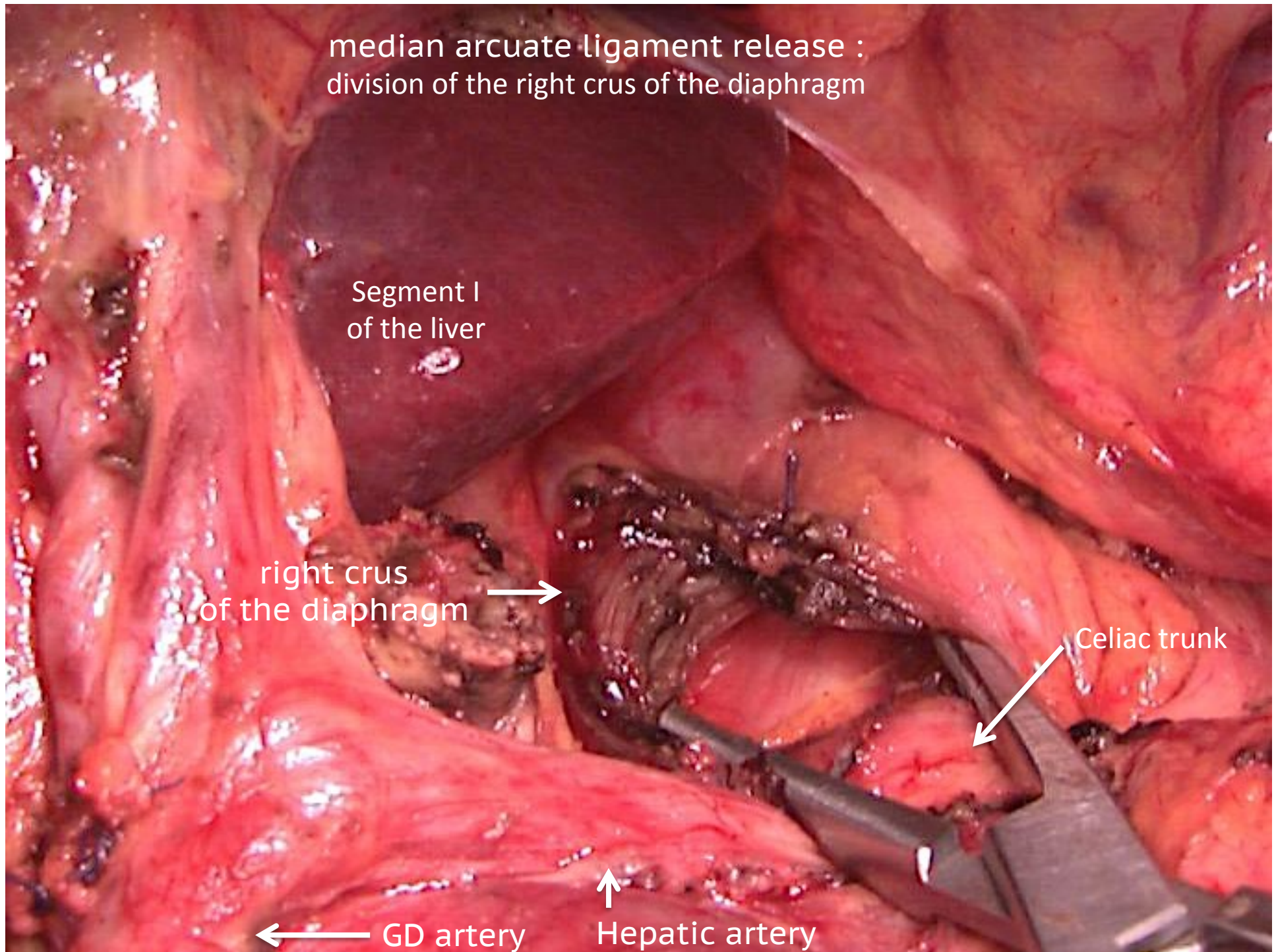
Segment I  
of the liver

right crus  
of the diaphragm →

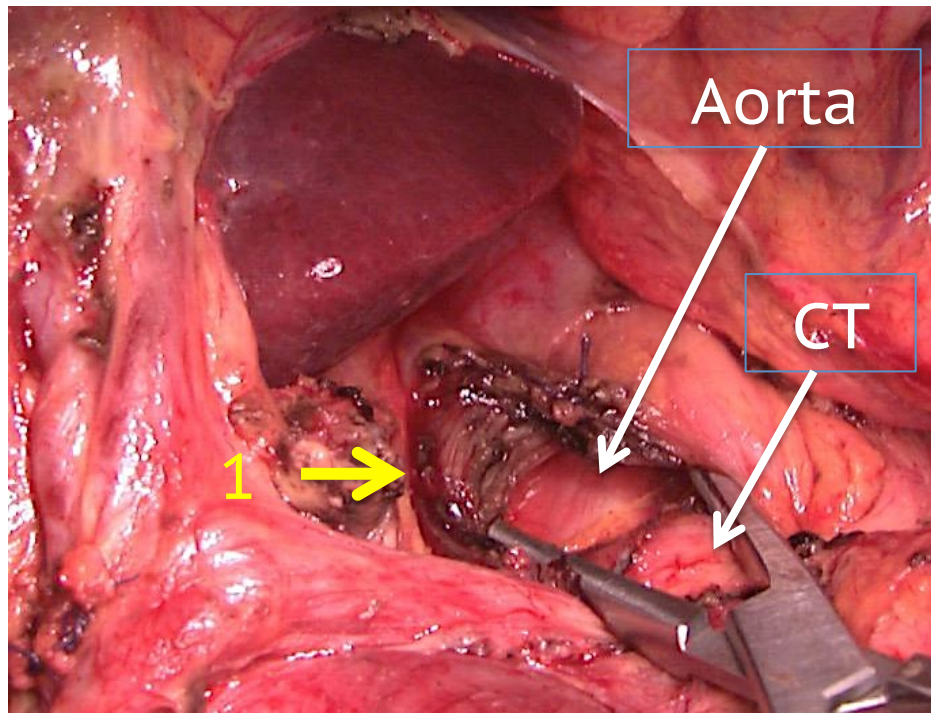
← Celiac trunk

← GD artery

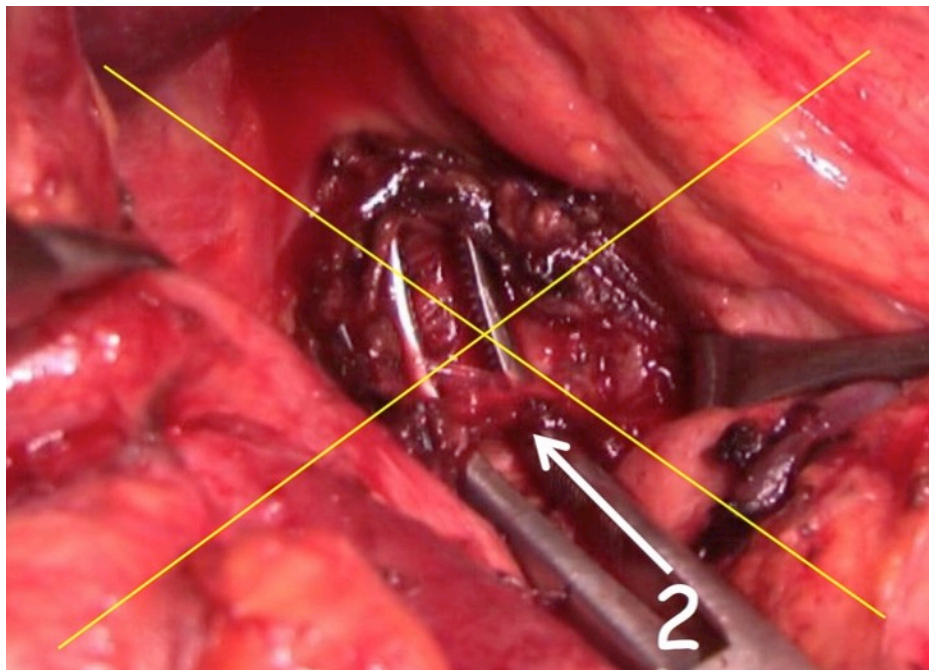
↑  
Hepatic artery







Wide division of the right crus  
of the diaphragm (1) ;  
the right side and the upper edge of  
the CA  
were progressively freed  
of all dense fibrous tissue



Division of the fibrous ligament itself  
(2)  
by a medial approach is difficult and  
can cause injury of the celiac trunk  
which the tunica adventitia is  
weakened.  
(CA fibromuscular dysplasia in some  
patient)



median arcuate ligament release

Celiac trunk

Splenic artery

Hepatic artery

Gastroduodenal artery

