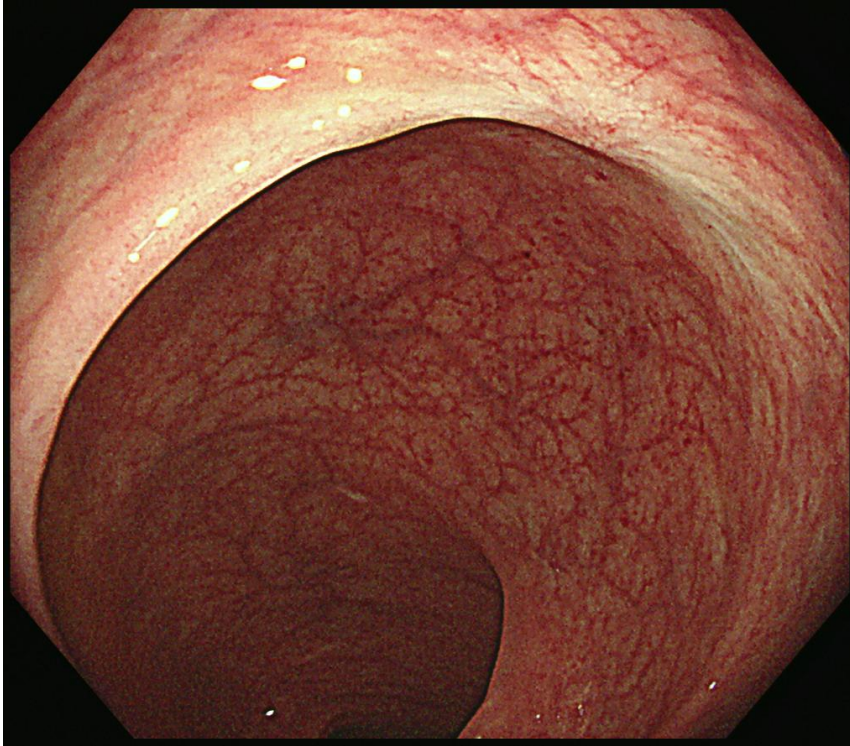
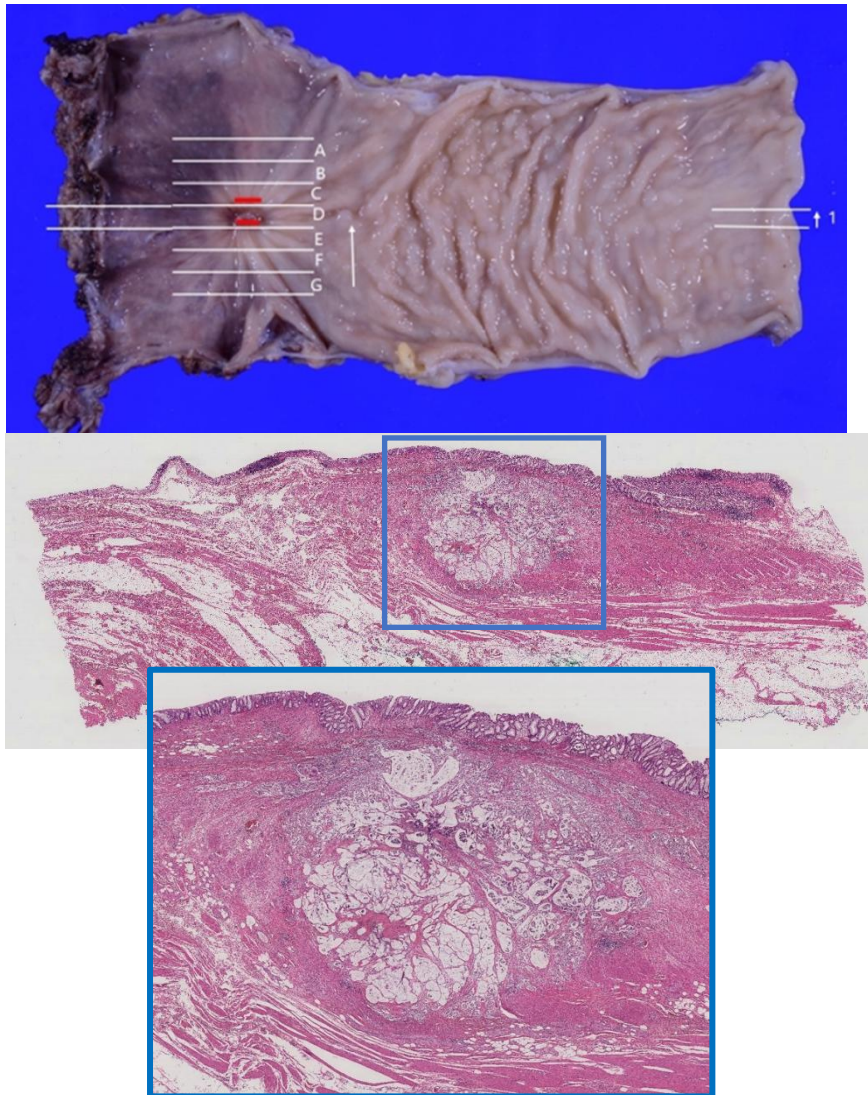


Supplementary figure 1



Supplementary figure 1. Endoscopic findings of the rectal mucosa two years after the primary endoscopic submucosal dissection. The whitish scar indicates no residual tumor endoscopically.

Supplementary figure 2.



Supplementary figure 2. A histopathological examination of the surgically resected tissue. Additional rectal resection with lymph node resection removed the ulceration after re-endoscopic submucosal dissection completely. The mucinous lake with signet-cell carcinoma observed under the ulceration infiltrated into the muscularis propria (blue square). The final histological diagnosis was type 0-Is+IIa, muc>tub>sig, T2, Ly1, V0, N0, M0, Stage I.